A Study of Benign Histopathological Changes in Cholecystectomy Specimen: Experience at a Referral Hospital

Swagata Dowerah[1], Rashmi Deori[2]

ABSTRACT

Introduction: Cholecystectomy or surgical removal of the gall bladder is one of the most commonly performed operations in a surgical setup. We carried out a study of the benign morphologic changes observed in cholecystectomy specimen to emphasise the importance of their proper diagnosis, as many of these may be misdiagnosed as malignant by the inexperienced eye.

Material and methods: A one year study of all cases of cholecystectomy specimen received in histopathology section was carried out. Three sections were taken from each specimen, stained with H and E and analysed by microscopy for histomorphological changes.

Results: Of a total of 103 cases studied, 95 cases were benign (92.2%) and only 8 cases were malignant. 85.4% cases showed chronic cholecystitis, 2.9% showed acute cholecystitis, 3.9% eosinophilic cholecystitis and 0.9% showed xanthogranulomatous cholecystitis. Other cases noted were empyaema, mucocoele and polyp. A spectrum of epithelial changes were noted which included hyperplasia, metaplasia, cholesterolosis, dysplasia and adenomyomatosis.

Conclusion: The present study was conducted to describe the histomorphological spectrum of gall bladder disease. A histopathologist well conversant with all the alterations and changes of the gall bladder is of utmost importance for proper diagnosis and treatment.

Keywords: Benign changes, gall bladder, cholecystectomy

INTRODUCTION

Cholecystectomy or removal of the gall bladder by surgery is one of the most commonly performed operations in a surgical setup. Its indications include inflammation of the gall bladder, symptomatic gall stones, risk factors for gall bladder malignancy and pancreatitis caused by gallstones. Laparascopic cholecystectomy is nowadays the procedure of choice. The histopathological diagnosis in most of the cholecystectomy specimens is chronic cholecystitis. However, chronic cholecystitis specimen often show other associated lesions such as cholesterolosis, hypertrophy of muscle layer, parietal fibrosis, polypoid and adenomatous proliferation of mucous glands, and changes such as metaplasia, hyperplasia and dysplasia.[1-3] Knowledge and awareness of these findings is important as many of them may be missed and an erroneous diagnosis of malignancy can be made. Aim of the study was to describe the benign morphologic changes observed in cholecystectomy specimen and to emphasise on the importance of their proper diagnosis.

MATERIAL AND METHODS

A one year study of all cases of cholecystectomy specimen (103) received in histopathology section of Assam Medical College and Hospital was carried out for the period of January 2015 to December 2015. The study was carried according to the institutional ethical guidelines for such studies. The clinical findings were noted and gross examination was done according to standard protocol. Three sections were taken, one from the fundus, one from the body and one from the neck. Sections were prepared and stained with H and E and evaluated for histomorphological changes.

STATISTICAL ANALYSIS

Microsoft office 2007 was used for tabulation and analysis. Descriptive analysis like rates and proportions using percentage were used to infer results.

RESULTS

Of a total of 103 cases studied, 95 cases were benign (92.2%) and only 8 cases were malignant. 3 cases showed acute cholecystitis with denuded mucosa, congestion, hemorrhage and oedema; the remainder were all showing changes of chronic cholecystitis (Figure-1). There were 4 cases of eosinophilic cholecystitis with marked infiltration of the gall bladder wall by eosinophils; apart from these, a variable number of eosinophils were observed in many of the specimen of chronic cholecystitis. One patient showed xanthogranulomatous cholecystitis with an inflammatory infiltrate in the wall comprising of foamy macrophages and foreign body type of giant cells.

There were 2 cases of empyaema gall bladder and 1 case of mucocoele which were diagnosed from gross and microscopic findings. There was a single case of fibrous polyp of gall bladder. Other non neoplastic epithelial alterations in the resected specimen included glandularis proliferans (14 cases, 13.6% of the total cholecystectomy specimen), spongioid hyperplasia (4 cases, 3.8% of total cases studied) (Figure-2), cholesterolosis (5 cases, 4.9%), adenomyomatosis (2 cases,1.9%), pseudopyloric metaplasia (1 case).

Low grade dysplasia was observed in 7 cases (6.8%) (Figure-3). The malignancies reported included adenocarcinoma (6 cases), undifferentiated carcinoma (1 case) and a single case of neuroendocrine carcinoma.

While the mean age group for malignant lesions was 48 years, that of benign lesions was 39 years. The mean age of patients showing low grade dysplasia was 42.43 years.

DISCUSSION

Histopathological examination of every resected gall bladder

[1]Assistant Professor, Department of Pathology, Silchar Medical College, [2]Assistant Professor, Department of Pathology, Assam Medical College India

Corresponding author: Dr. Swagata Dowerah, Department of Pathology, Silchar Medical College, India

How to cite this article: Swagata Dowerah, Rashmi Deori. A study of benign histopathological changes in cholecystectomy specimen: experience at a referral hospital. International Journal of Contemporary Medical Research 2016;3(8):2392-2394.

is of utmost importance. While the diagnosis in most cases is chronic cholecystitis, a spectrum of other morphological changes are commonly seen which include acute inflammation, cholesterosis, metaplasia and hyperplasia. Uncommonly, cholecystectomy specimen may reveal an unexpected gallbladder carcinoma. Therefore a detailed knowledge of the architectural variations of the gall bladder is essential so that none of these changes are misdiagnosed as malignant and no case of malignancy is missed.

In our study of 103 cases of cholecystectomy, there were 95 cases showing benign changes, almost exclusively associated with gall stone disease. The male to female ratio was calculated to be 1:4.6. In a study by Selvi et al, gall stone disease was predominantly seen in females (61.5%) as compared to males (38.4%).[2] In another study of cholecystectomies by Shah et al, the overall male to female ratio (M:F) was observed to be 1:2.3 and in cases with gall stones, the ratio was 1:2.7.[3] Thus it appears that gall bladder disease is more common in females. Female sex hormones and sedentary habits of most women in India expose them to factors that possibly promote the formation of gallstones.[4-6]

The average age of patients showing benign disease was 39.33 years while for malignant cases, it was 48 years, the average age of patients showing dysplastic changes was 42.43 years. Benign disease occurred at an earlier age group than dysplastic lesions. Likewise, malignancies were seen to occur at a more advanced age. This corroborates with the findings of several other studies. The most common finding in our study was chronic cholecystitis. Chronic cholecystitis is the most commonly encountered disease of the gallbladder; therefore the majority of cholecystectomies are performed for this condition.[7-9] The degree of chronic inflammation may vary and comprise of predominantly lymphocytes with few plasma cells, histiocytes, and occasional eosinophils. Acute cholecystitis on the other hand is mainly a clinical entity caused by abrupt injury of the gall bladder. It is an acute destructive process typically associated with ischemia, congestion, edema, epithelial denudation, vascular leakage, hemorrhage and fibrin deposition. In our study, there were 88 cases (85.4%) of chronic cholecystitis and only 3 cases (2.9%) of acute cholecystitis. Other variants of cholecystitis encountered were eosinophilic cholecystitis (4 cases) and one case of xanthogranulomatous cholecystitis (Table-1). There were 2 cases (1.9%) of empyaema gall bladder and one case of mucocoele. Selvi et al[2] had reported 85.8 % cases with chronic cholecystitis, 2.5% with acute cholecystitis, 2.5% polyp, 1.2% granulomatous cholecystitis, 1.2% empyema, 5.1% eosinophilic cholecystitis and 1.2% carcinoma. The proportion of malignant cases was higher in our study with 8 reported cases (7.7%). Terada et al in their study found incidence of malignancy to be 2.2%[10], while in another study Ghimire P et al[11] showed it to be 1.28%.

Apart from these, a wide variety of epithelial alterations were recorded which included hyperplasia including spongioid

Changes observed	Number of cases	Percentage
Chronic cholecystitis	88	85.4 %
Acute cholecystitis	3	2.9 %
Eosinophilic cholecystitis	4	3.9 %
Xanthogranulomatous cholecystitis	1	0.9 %
Empyaema	2	1.9 %
Mucocoele	1	0.9 %
Hyperplasia	14	13.6 %
Cholesterolosis	5	4.9 %
Spongioid hyperplasia	4	3.8 %
Adenomyomatosis	2	1.9 %
Pseudopyloric metaplasia	1	0.9%
Gall bladder polyp	1	0.9 %

Table-1: Non malignant changes seen in cholecystectomy specimen

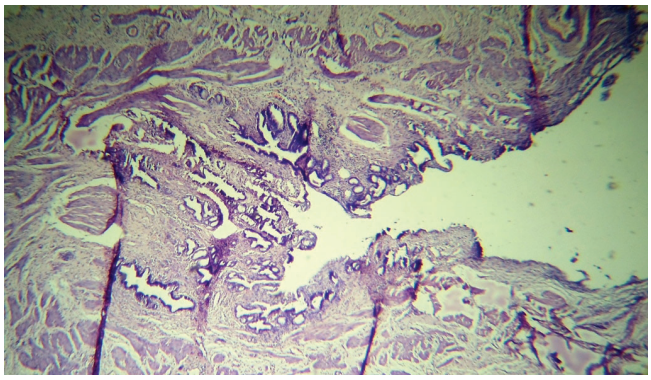

Figure-1 Showing gall bladder mucosa with features of chronic cholecystitis

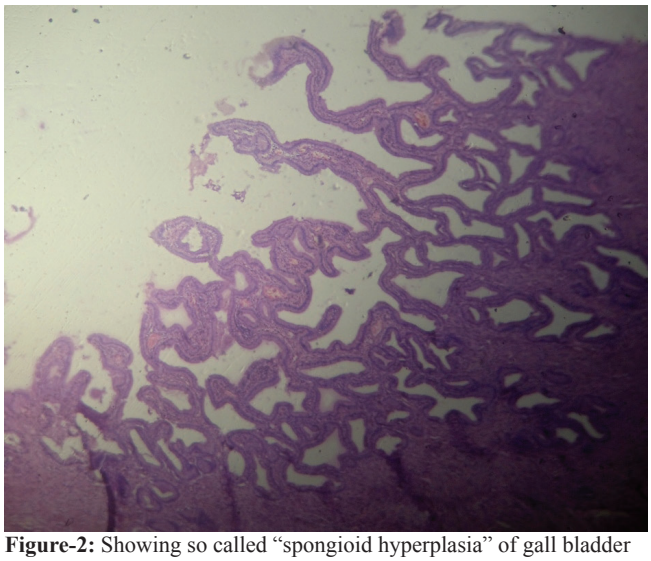

Figure-2: Showing so called "spongioid hyperplasia" of gall bladder

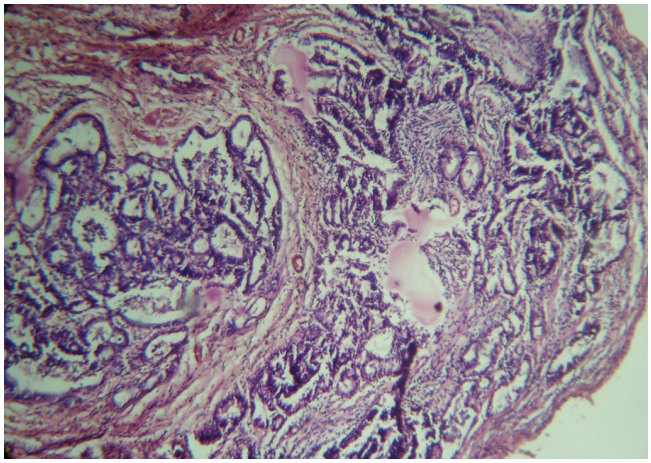

Figure-3: Showing hyperplasia of the mucosa of gall bladder with mild dysplastic changes

hyperplasia, metaplasia, cholesterolosis, adenomyomatosis and dysplasia (Table-1). Shah et al[3] in their study found chronic cholecystitis to be the most common pathology reported in 80.4% cases. Other benign lesions were, acute cholecystitis in 10.2% and empyema in 4.5% cases. There were 2 cases (0.3%) each of cholesterosis, adenomyoma and hyperplasia and 1 case of metaplasia in their study.

It is important for the pathologist to be familiar with these benign alterations of the gall bladder mucosa as an untrained eye may erroneously label these changes as malignant. Further studies are needed to properly elucidate the cause of these changes and to understand their relevance in the clinical setting.

CONCLUSION

The present study was conducted to describe the histomorphological spectrum of gall bladder disease. While the most common diagnosis noted was chronic cholecystitis, a wide range of other findings were also observed which included hyperplasias, metaplasia, adenomyomatosis and cholesterolosis. A histopathologist well conversant with all the alterations of the gall bladder is of utmost importance for proper diagnosis and treatment.

REFERENCES

1. Stancu M, Caruntu ID, Giusca S, Dobrescu G. Hyperplasia, metaplasia, dysplasia and neoplasia lesions in chronic cholecystitis – a morphologic study. 2007;48:335-42.
2. R. Thamil Selvi, Pammy Sinha, P.M. Subramaniam, P.G. Konapur, C.V. Prabha. A clinicopathological study of cholecystitis with special reference to analysis of cholelithiasis. 2011;2:68-72.
3. Nailesh Shah, Jyoti Gadhavee, Samir Dalsaniya, Nirali K Shah. A Histopathological study of cholecystectomies at a tertiary care teaching hospital in Western India. 2014;6:15-21.
4. Mohan H, Punia RP, Dhawan SB, Ahal S, Sekhon MS. Morphological spectrum of gallstone disease in 1100 cholecystectomies in North India. Indian J Surg. 2005;67: 140-2.
5. Tandon RK. Pathogenesis of gallstones in India. Trop Gastroenterol. 1988;9:83-9.
6. Baig SJ, Biswas S, Das S, Basu K, Chattopadhyay G. Histopathological changes in gallbladder mucosa incholelithiasis: Correlation with chemical composition of gallstones. Trop Gastroenterol. 2002;23:25-7.
7. Weedon D. Diseases of the gallbladder. In In:Mc Sween RMN APBAa, editor. Pathology of the Liver. 3rd ed. New York: Churchill Livingstone. 1994.514-534.
8. Bilhartz LE, Horton JD. Gallstone disease and its complications. 6th ed. In: Feldman M SBSM, editor. Philadelphia: WB Saunders; 1998.
9. Jagannath SB, Singh VK, Cruz- Correa M et al. A long term cohort study of outcome after cholecystectomy for chronic acalculous cholecystitis. 2003;185:91-95.
10. T T. Histopathologic features and frequency of gall bladder lesions in consecutive 540 cholecystectomies. Int J Clin Exp Pathol. 2013;6:91-6.
11. Ghimire P, Yogi N, Shrestha BB. Incidence of incidental carcinoma gall bladder in cases of routine cholecystectomy. Kathmandu Univ Med J. 2011;34:3-6.

Source of Support: Nil; **Conflict of Interest:** None

Submitted: 15-06-2016; **Published online**: 31-07-2016