

# A Case Report of Disseminated *Trichosporon Asahii* and Covid-19 Co-Infection in an Immunocompetent Patient

Dipika Menon<sup>1</sup>, Soumen Saha<sup>2</sup>, Subhrangshu Mandal<sup>3</sup>

## ABSTRACT

**Introduction:** *Trichosporon asahii* is an emerging yeast-like fungal pathogen. It can cause fatal infection in patients with haematological malignancy and other immunodeficient conditions. In a number of cases, *T. asahii* was found to cause secondary infection in COVID patients with high case fatality.

**Case report:** We describe a case of an elderly male patient without any immunodeficiency presented with features of pulmonary infection and found to have co-infected with COVID-19 and *T. asahii*. Yeast like fungus was isolated from blood in routine fungal culture media. Morphologically diagnosed as *Trichosporon* from presence of hyphae and arthroconidia. The identification was confirmed using Vitek 2 compact and subsequently matrix-assisted laser desorption/ionization time-of-flight (MALDI-TOF) mass spectrometry (VITEK-MS, Biomeireux). The clinical course of the patient was rapidly deteriorating leading to multi organ failure and death on the 6<sup>th</sup> day.

**Discussion:** Although the clinical condition was progressively poor, serum Procalcitonin was not raised. This phenomenon indicates that a high level of suspicion for invasive fungal infection should be kept in mind in clinically severe diseases with low serum procalcitonin. Further it adds to the possibility of fungal co-infection in COVID patients.

**Keywords:** *Trichosporon*, COVID, Arthroconidia, MALDI-TOF

## INTRODUCTION

*Trichosporon* species are an emerging pathogenic fungi. It is a saprophytic yeast like fungus found in air, soil, water, animal excreta and sewage. It may exist as a commensal on the scalp and hair. It may colonize the skin, gastrointestinal tract and respiratory tract of humans.<sup>1</sup> However it may cause fatal infections in patients with haematological malignancies, granulocytopenia and those receiving corticosteroids for a long time.<sup>2</sup> Infection have been also detected in patients without neutropenia or malignancy.<sup>3</sup> *T. asahii* infection associated with organ transplants, human immunodeficiency virus infection, prosthetic heart valves, peritoneal dialysis and infections related to catheter was also found.<sup>4</sup>

The wide spectrum of clinical features can range from superficial skin infection to invasive systemic infections depending on the immune status of the patient. Those with invasive trichosporonosis have high mortality rate (64%-100%).<sup>4</sup> Hence early diagnosis and treatment is vital.

Here we present a case of disseminated trichosporonosis and COVID 19 co-infection in an immunocompetent person.

## CASE REPORT

A 64 years old male patient, with controlled diabetes, hypertension and non oliguric CKD (chronic kidney disease) presented to the ER (emergency room) with shortness of breath and altered mental state for the last two days. He was haemodynamically stable and had no history of fever or cough. In past medical history he had suffered from CVA (cerebro vascular accident) in 2019.

Oxygen saturation at the ER was 88% and oxygen was given at a rate of 15 lit/ min through NRB (Non rebreathing mask). Initial investigations showed high leukocyte count (TLC)  $1.52 \times 10^4$  cells/ ul ( $0.4-1.05 \times 10^4$  cells/ ul), increased CRP 76.25 mg/L (0-5 mg/L), very high D-dimer 2161.3 ng/mL (0-500 ng/mL) and ferritin 2520 ng/mL (17.9-464 ng/mL) but low Procalcitonin level 0.52 ng/ ml. To rule out COVID-19, CBNAAT (cartridge based nucleic acid amplification test) was sent which came as positive. Serology screening tests were negative, including HIV. Routine urine culture was sent, which showed growth of yeast after 24 hours, in a background of increased pus cells. CT scan thorax showed segmental bronchioles in bilateral lower lobes appear thickened & prominent with peribronchovascular nodules, ground glass opacities & collapse consolidation associated with fibroatelectatic changes. Think of bilateral pleural effusion (Figure 1D).

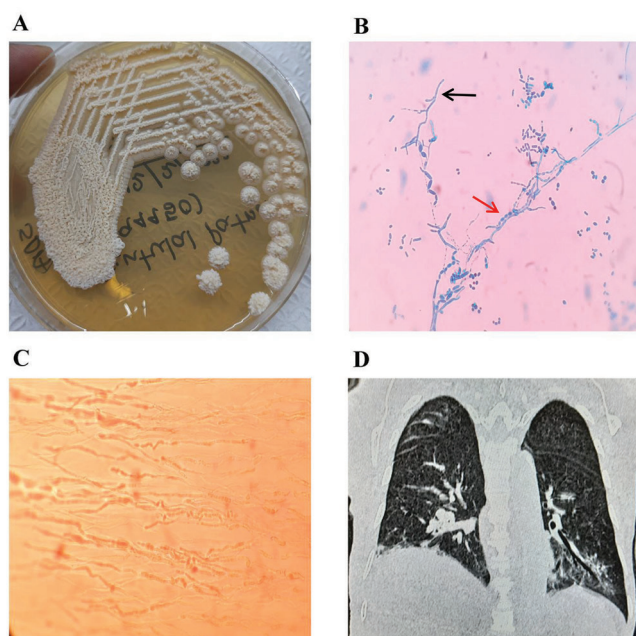
He was started on treatment for COVID along with broad spectrum antibiotics, meropenem, teicoplanin and doxycycline. On 3<sup>rd</sup> day of therapy the patient developed shock and started on inotropes. He was intubated due to severe hypoxia and metabolic acidosis. TLC and CRP was increasing steadily and the patient developed anuria on 5<sup>th</sup> day requiring haemodialysis. Antibiotics were escalated at this point to polymixin B and minocycline. Aerobic blood culture sent on 2<sup>nd</sup> day showed positive growth of yeast after 3 days of incubation. Unfortunately the patient passes away on 6<sup>th</sup> day after a cardiac arrest but the growth of yeast was further

<sup>1</sup>Junior Consultant, Department of Microbiology, Medica Superspecialty Hospital, <sup>2</sup>Senior Consultant, Department of Microbiology, Medica Superspecialty Hospital, <sup>3</sup>Associate Professor Microbiology, Department of Laboratory Medicine, Chittaranjan National Cancer Institute, Medical Superspecialty Hospital

**Corresponding author:** Dr. Soumen Saha, 127 Mukundapur, E.M. bypass, Kol- 700099

**How to cite this article:** Dipika Menon, Soumen Saha, Subhrangshu Mandal. A case report of disseminated trichosporon asahii and covid-19 co-infection in an immunocompetent patient. International Journal of Contemporary Medical Research 2022;9(11):K1-K3.





**Figure-1:** [A] growth of *Trichosporon* on Sabouraud dextrose agar (SDA); [B] Lacto phenol cotton blue mount of growth from SDA, septate hyphae indicated by black arrow and arthrospores indicated by red arrow; [C] demonstration of arthroconidia in corn meal agar by Dalmau plate technique; [D] CT scan of chest showing pulmonary infiltrates.

processed for identification and antifungal sensitivity. On Sabouraud dextrose agar the colonies were cream coloured with wrinkled and raised surface (Figure 1A). The organism was processed on Candida Chrome agar and Corn meal agar for Dalmau plate culture. Lacto phenol cotton blue mount from the growth revealed pleomorphic yeast like cells with septate hyphae, arthrospores and blastospores (Figure 1B). The arthrospores were further demonstrated from Dalmau plate (Figure 1C). This was suggestive of *Trichosporon* species. Colour and colony morphology found in Chrome agar was also suggestive of *Trichosporon* sp. The isolated yeast was further identified as *T. asahii* by Vitek 2 compact. Subsequently confirmed as *T. asahii* by matrix-assisted laser desorption/ionization time-of-flight (MALDI-TOF) mass spectrometry (VITEK-MS, Biomeireux). Antifungal sensitivity was not reported by Vitek 2 compact as it is not included in the data base.

## DISCUSSION

*Trichosporon* species are opportunistic fungal pathogen, causing infections predominantly in immunocompromised patients, particularly having neutropenia and haematological malignancies.<sup>1</sup> However it has also been reported from immunocompetent patients.<sup>3,5</sup>

During COVID pandemic increasing number of secondary infections with *Trichosporon* has been reported, with *T. asahii* being the isolated species almost in all the cases.<sup>6,7,8</sup> Gawahir A Ali reported *T. asahii* infection in a severe COVID after 11<sup>th</sup> day of hospital admission.<sup>6</sup> Almedia J et al reported 5 cases of *Trichosporon* fungemia in COVID patients with

a calculated rate of 27.3/1000 ICU admissions. The average interval was 22 days of hospital admission before contracting the infection.<sup>7</sup> Gonzalo S Calvo has reported one incident of *T. asahii* in a COVID patient after 27<sup>th</sup> day of ICU admission along with other bacterial co-infections.<sup>8</sup> *Trichosporon* has been isolated most commonly from blood among these COVID patients. All of them received immunosuppressive drugs either in form of steroids or interleukin antagonists. In our case the patient was not neutropenic or had cancer but was infected with COVID-19. The fungus was present in blood sent for culture on the 2<sup>nd</sup> day of admission. This indicates the patient had fungal pneumonia during admission before receipt of any immunosuppressive drug and can be assumed that in our case COVID 19 was co-infected with *Trichosporon asahii*. Which leads to the question whether COVID infection itself can create an immunodeficient state and facilitate fungal co-infection.

In accordance with the definitions of opportunistic invasive fungal infections (IFI) published by the European Organization for Research and Treatment of Cancer/ Invasive Fungal Infection Cooperative Group (EORTC/ IFICG) and the National Institute of Allergy and Infectious Disease Mycoses Study Group (NIAID/MSG), invasive trichosporonosis may be

defined as follows: patients with proven invasive trichosporonosis presenting at least one of the following criteria: (i) blood cultures yielding *Trichosporon* species in patients with temporally related clinical signs and symptoms of infection, (ii) cerebrospinal fluid (CSF) culture yielding *Trichosporon* species, or (iii) biopsy specimens that are culture positive and present histopathological evidence of fungal elements compatible with *Trichosporon* spp.<sup>9</sup>

Unfortunately in our case the patient could not be treated with anti-fungal drug due to rapidly deteriorating clinical course. In general treatment with Voriconazole along with Amphotericin B or alone has good effect on the fungal pathogen.<sup>2</sup> *Trichosporon* can be confused with *Candida* sp which could lead to improper choice of anti-fungal drug at early stage of infection, but *Trichosporon* forms arthroconidia which is not produced by *Candida*.<sup>4</sup>

## CONCLUSION

*Trichosporon asahii* is an emerging fungus which may cause disseminated disease. The fatality of invasive disease is high. *Trichosporon* species is often confused with candida species as both are yeast like fungi. In situations when procalcitonin level is low in spite of features of severe infection, possibility of fungal infection should be kept in mind, particularly if the patient has compromised immunity or co-infection like COVID 19.

## REFERENCE

1. Colombo AL, Padovan ACB, Chaves GM. Current knowledge of *Trichosporon* spp. and Trichosporonosis. Clin Microbiol Rev. 2011;24(4):682–700.
2. Tanyildiz HG, Yesil S, Toprak S, Candir MO, Sahin G. Two case presentations infected by *Trichosporon asahii* and treated with voriconazole successfully. Case Rep

- Infect Dis. 2015;2015:651315.
3. Ebright JR, Fairfax MR, Vazquez JA. Trichosporon asahii, a non-Candida yeast that caused fatal septic shock in a patient without cancer or neutropenia. Clin Infect Dis. 2001;33(5):E28-30.
  4. Sah R, Soin AS, Chawla S, Wadhwa T, Gupta N. Disseminated Trichosporon asahii infection in a combined liver-kidney transplant recipient successfully treated with voriconazole. Immun Inflamm Dis. 2019;7(3):125–9.
  5. Devi K, Mate P, Singh L, Devi K, Devi K. Disseminated infection with Trichosporon asahii in an immunocompetent patient: A rare case report. J Med Soc. 2015;29(3):174.
  6. Ali GA, Husain A, Salah H, Goravey W. Trichosporon asahii fungemia and COVID-19 co-infection: An emerging fungal pathogen; case report and review of the literature. IDCases. 2021;25(e01244):e01244.
  7. Nobrega de Almeida J Jr, Moreno L, Francisco EC, Noronha Marques G, Mendes AV, Barberino MG, et al. Trichosporon asahii superinfections in critically ill COVID-19 patients overexposed to antimicrobials and corticosteroids. Mycoses. 2021;64(8):817–22.
  8. Segrelles-Calvo G, Araújo GRDS, Llopis-Pastor E, Frases S. Trichosporon asahii as cause of nosocomial pneumonia in patient with COVID-19: A triple co-infection. Arch Bronconeumol. 2021;57:46–8.
  9. De Pauw B, Walsh TJ, Donnelly JP, Stevens DA, Edwards JE, Calandra T, et al. Revised definitions of invasive fungal disease from the European organization for research and treatment of cancer/invasive fungal infections cooperative group and the national institute of allergy and infectious diseases mycoses study group (EORTC/MSG) consensus group. Clin Infect Dis. 2008;46(12):1813–21.

**Source of Support:** Nil; **Conflict of Interest:** None

**Submitted:** 22-09-2022; **Accepted:** 26-10-2022; **Published:** 30-11-2022