Mammogram and Ultrasound Evaluation of Breast Lesion with FNAC correlation

Sheikh Burgees Ismail[1], Jigyasa Puri[2], Rounaq Mishra[3], Rajesh Sharma[4]

ABSTRACT

Introduction: Breast cancer is the most common female cancer worldwide representing nearly quarter (25%) of all cancers. According to World health organization (WHO), in 2020, there were 2.3 million women diagnosed with breast cancer and 685,000 deaths globally. Aim: To study the mammographic and ultrasonographic characteristics of breast lesions in patients andto categorize the detected breast lesions according to BI- RADS.

Material and Methods: The study included all the female patients referred to the Department of radiodiagnosis and imaging, Acharya Shri Chander College of Medical Sciences and Hospital, Sidhra, Jammu, for evaluation of breast lesions after being analysed by their primary complaints, relevant positive and negative histories and proper clinical examination of breast.

Results: In the present study, out of 52, 23 (44.2%) and 16 (30.8%) were diagnosed benign and malignant lesion respectively on mammography, out of 52, 9 (17.3%), 9 (17.3%), 10 (19.2%), 4 (7%) and 3 (5.8%) had calcification, architectural distortion, internal vascularity, post acoustic shadowing and post acoustic enhancement respectively on USG.

Conclusion: This study demonstrates that ultrasonography and mammography have a greater combined specificity for detecting breast lumps, including cancers.

Keywords: Mammogram, Ultrasound, Breast Lesion, FNAC correlation

INTRODUCTION

Breast cancer arises in the lining cells (epithelium) of the ducts (85%) or lobules (15%) in the glandular tissue of the breast. Breast cancer is the most common female cancer worldwide representing nearly quarter (25%) of all cancers. According to World health organization (WHO), in 2020, there were 2.3 million women diagnosed with breast cancer and 685,000 deaths globally. As of the end of 2020, there were 7.8 million women alive who were diagnosed with breast cancer in the past 5 years, making it the world's most prevalent cancer. There are more lost disability-adjusted life years (DALYs) by women to breast cancer globally than any other type of cancer (WHO, 2020).

According to GLOBOCAN 2020, India along with United States and China collectively accounts for almost one third of the global breast cancer burden. Female breast cancer has now surpassed lung cancer as the leading cause of global cancer incidence in 2020, with an estimated 2.3 million new cases, representing 11.7% of all cancer cases (Sung et al, 2021).

Overall, the burden of cancer incidence and mortality is rapidly growing worldwide, this reflects both aging and growth of the population as well as changes in the prevalence and distribution of the main risk factors for cancer, several of which are associated with socioeconomic development (Omeran, 1971; Gersten et al, 2002).

There is a significant increase in the incidence and cancer-associated morbidity and mortality in Indian subcontinent as described in global and Indian studies (Babu et al, 2013). Indian women having breast cancer are found a decade younger in comparison to western women suggesting that breast cancer occurs at a younger premenopausal age in India (Chopra et al, 2013). In India, majority of patients present at locally advanced or at metastatic stages at the time of diagnosis. According to various studies, majority of carcinoma breast cases in the west report in stages I and II of disease, whereas in India 45.7% report in advanced stages (Kakarala et al, 2010).

Encouraging patients aged 40 years and older to have annual mammography and clinical breast examination is the single most important step that clinicians can take to reduce suffering and death from breast cancer. Clinicians should also ensure that patients at high risk of breast cancer are identified and offered appropriate screening and follow-up. Continued progress in the control of breast cancer will require sustained and increased efforts to provide high-quality screening, diagnosis, and treatment to all segments of the population (DeSantis et al, 2011).

MATERIALS AND METHODS

Selection of patients: All the female patients referred to the Department of radiodiagnosis and imaging, Acharya Shri Chander College of Medical Sciences and Hospital, Sidhra, Jammu, for evaluation of breast lesions after being analyzed by their primary complaints, relevant positive and negative

[1]PG Resident, Department of Radio-Diagnosis and Imaging ASCOMS Hospital, Jammu, [2]Assistant Professor, Department of Radio-Diagnosis and Imaging ASCOMS Hospital, Jammu, [3]PG Resident, Department of Radio-Diagnosis and Imaging ASCOMS Hospital, Jammu, [4]Professor-HOD, Department of Radio-Diagnosis and Imaging ASCOMS Hospital, Jammu

Corresponding author: Dr Rajesh Sharma, S/O: Keshav Dutt Sharma, H no 175-B, Ram Vihar, Old Janipur, Jammu City, Jammu, Janipur, Jammu And Kashmir, 180007

How to cite this article: Sheikh Burgees Ismail, Jigyasa Puri, Rounaq Mishra, Rajesh Sharma. Mammogram and ultrasound evaluation of breast lesion with FNAC correlation. International Journal of Contemporary Medical Research 2022;9(6):F7-F12.

histories and proper clinical examination of breast.

Study design– Hospital based Prospective observational study

Study duration– From November 2020 to October 2021

Sample size: - Sample size was taken 52

Inclusion criteria

- Females age 30 years and above coming for routine breast screening, found to have BI-RADS 2 and above.
- Females age 30 years or above associated with typical or atypical symptoms of breast malignancy (nipple discharge, inverted nipple, dimpling/ thickening of breast skin, etc.) referred to department of radio diagnosis.
- Females age 30 years or above with complaints of pain in the breast referred to Department of Radiodiagnosis.
- Females age 30 years and above with breast lumps.

Exclusion criteria

- Pregnant women
- Patient with bleeding diathesis.
- Patients with known history of breast malignancy (BI-RADS 6).
- Patient is not willing for FNAC / not capable of giving consent**.**

Equipments

- Conventional mammography will be performed by 'Mammography system MAM-VENUS, Allengers medical systems limited'.
- Ultrasonography will be performed by 'SIEMENS ACCUSON X 300' using a high frequency 7-10 MHz linear array transducer.

Sampling technique

A convenient sampling technique was used to enroll the patients in study till the sample size completion and 52 patients were selected for the study.

Methodology

All the patients gave consent for study were asked about sociodemographic details and underwent for mammography and USG. Final confirmation was made by FNAC.

Mammography was performed as an initial imaging examination, followed by USG prior to histopathological examination.

Mammography

The patients were subjected to "Two view Mammography" (cranio-caudal & medio- lateral views).

The mammographic evaluation of the detected lesions was performed using the ACR- BIRADS Lexicon criteria. The lesions were assessed for the following attributes:

- Location with respect to specific breast quadrant,
- Shape,
- Size,
- Margins,
- Density,
- Presence or absence of calcifications,
- Presence or absence of any associated features, like Halo Sign, Axillary Lymphadenopathy, Retraction of the skin or nipple and Skin-Thickening.

USG

High-resolution sonographic evaluation of both breasts was performed in real time, in gray-scale, Color Doppler and Spectral Doppler modes, using a high resolution, linear-array transducer (7.5-12 MHz).

On USG, the lesions were classified into benign or malignant, on the basis of following characteristics:

- Mass shape,
- Margins,
- Parallel or Anti-Parallel Orientation,
- Echotexture,
- Posterior acoustic features,
- Presence or absence of calcifications,
- Vascularity of the mass, and RI value if vascularity present.
- Any associated axillary lymphadenopathy and lymph nodal characteristics.
- Presence or absence of any associated features, like Halo Sign, Retraction of the skin or nipple and Skin-Thickening**.**

Categorization of the lesions:

The final assessment includes the BI-RADS 0 to 6 categorization.

BI-RADS 0: A category assessment of BI-RADS 0 refers to an incomplete evaluation with further imaging required including additional mammographic views including spot compression or magnification and or ultrasound.

BI-RADS 1: BI-RADS 1 refers to a negative examination, meaning that there are no masses, suspicious calcifications or areas of architectural distortion. There can be no description of a finding in the report if it is categorized as a BI-RADS 1.

BI-RADS 2: BI-RADS 2 is consistent with benign findings. Benign findings include secretory calcifications, simple cysts, fat-containing lesions, calcified fibroadenomas, implants and intramammary lymph nodes.

BI-RADS 3: BI-RADS 3 is probably benign and should have shortened interval follow-up to determine stability. The risk of malignancy is below 2%. There are very strict classifications to qualify a finding in the BI-RADS 3 category: a non-palpable, circumscribed mass on a baseline mammogram; a focal asymmetry, which becomes less dense on spot compression images, or a solitary group of punctate calcifications. Any findings other than this cannot be placed in the category 3**.**

BI-RADS 4: BI-RADS 4 is a suspicious abnormality, which can represent the chance of being malignant (in percent). The BI-RADS category 4 is subdivided into a, b, and c. The subcategory of (a) has a low probability of malignancy with a 2% to 10% chance of malignancy. The subcategory of (b) has an intermediate change of malignancy ranging from 10% to 50%. The subcategory of (c) has a high probability of malignancy ranging from 50% to 95%.

BI-RADS 5: BI-RADS 5 is highly suggestive of malignancy

more than 95%. If something is placed in this classification and the pathology comes back as benign, the recommendation is still surgical consultation, because the pathology is discordant with the radiographic findings.

BI-RADS 6: The last category that was recently added is the BI-RADS 6, used for pathology proven malignancy.

The final correlation of the categorized lesions was performed with histopathological findings for confirmation of the diagnosis.

In the present study, out of 52, maximum participants i.e. 17 (32.7%) were in age group of 30-40 years and 41-50 years each.

RESULTS

The study population consist of 52. The summary of the findings is as follows:

- In our study, mean of study participants was 47.2 years with SD of 12.6. youngest participant was 30 year old while oldest participant was 74 year old and out of 52, maximum participants i.e. 17 (32.7%) were in age group of 30-40 years and 41-50 years each.
- In the present study, out of 52, on clinical breast examination 44 (84.6%) were positive for breast mass.
- In the present study, out of 52, maximum participants i.e. 22 (42.3%) had 1 lesion and mean size of lesion was 18.3 mm with SD of 3.0 on mammography. Out of 52, 10 (19.2%) had axillary lymph node >1 cm on mammography
- In the present study, out of 52, 23 (44.2%) and 16 (30.8%) were diagnosed benign and malignant lesion respectively on mammography.
- In the present study, out of 52, 23 (44.2%) had calcification and 17 (32.7%) had architectural distortion

Mean	**47.21**
Median	45.00
Std. Deviation	12.595
Minimum	30
Maximum	74

Table 1: Age distribution of study participants:

Age (years)	Frequency	Percent
30-40 years	17	32.7
41-50 years	17	32.7
51-60 years	10	19.2
>60 years	8	15.4
Total	52	100.0

Table 2: Distribution of study participants according to age group

CBE	Frequency	Percent
Positive	44	84.6
Negative	8	15.4
Total	52	100.0

Table 3: Distribution of study participants according to CBE

Number of lesion on MMG	Frequency	Percent
1	22	42.3
2	10	19.2
MULTIPLE	6	11.5
NA	14	26.9
Total	52	100.0

Table 4: Distribution of number of lesion on MMG

CASE OF FIBROADENOMA

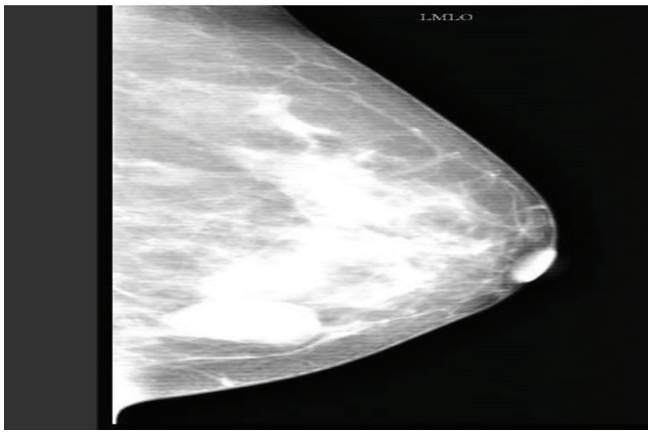

Plate-1: Well defined radio-opaque lesion with benigncharacteristicson mammography

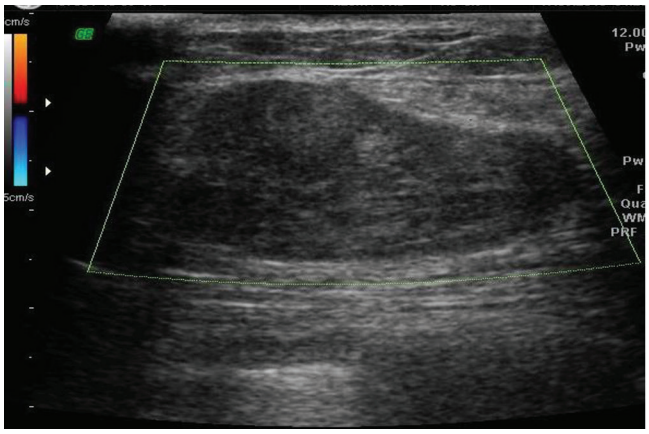

Plate-2: Well defined hypoechoic lesion, FNAC proven fibroadenoma

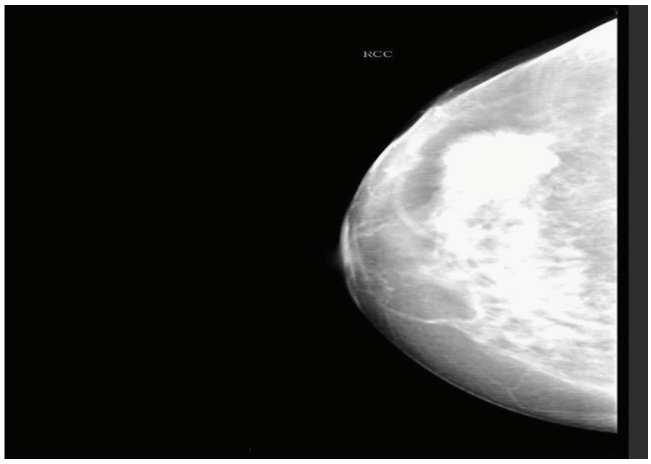

Plate-3: Lesion with irregular spiculated margins on mammography

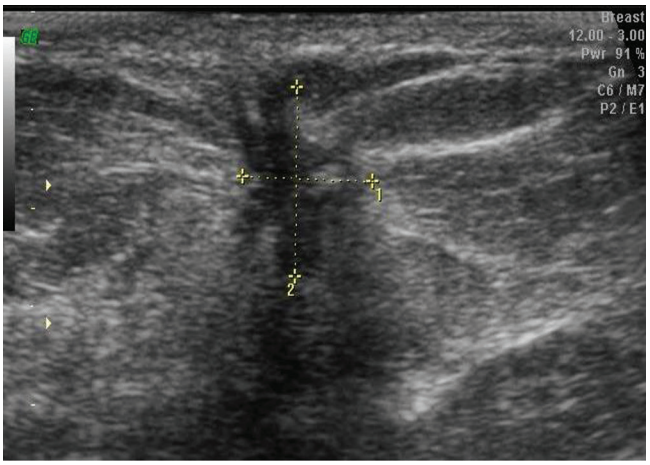

Plate-4: Same patient -irregular heterogenous lesion withfeatures of malignancy on usg, FNAC proven atypical ductalhyperplasia

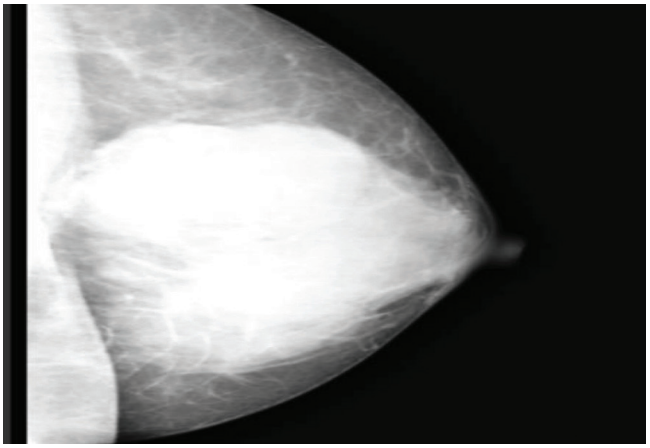

Plate-5: Retroareolar abscess on mammography

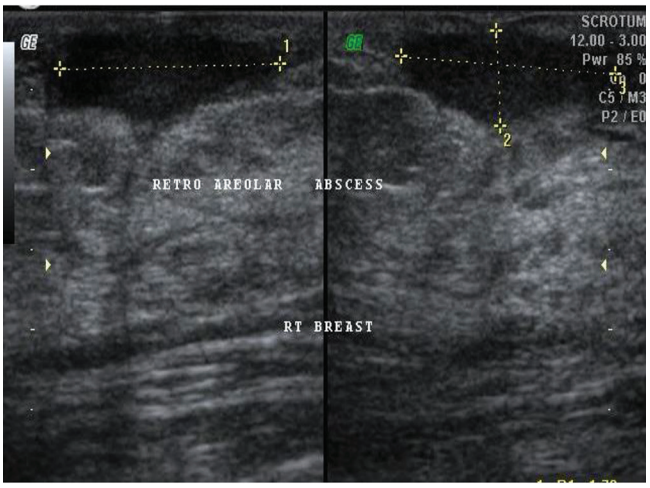

Plate-6: USG-retroareolarabscess

on mammography.

- In the present study, out of 52, 17 (32.7%) had axillary lymph node involvement on mammography.
- In the present study, out of 52, maximum i.e. 21 (40.4%) had C grade of breast density on mammography.
- In the present study, out of 52, maximum i.e. 31 (59.6%) had BIRAD score 2.
- In the present study, out of 52, maximum participants i.e. 17 (32.7%) had multiple lesion on USG.
- In the present study, out of 52, 32 (61.5%) and 15 (28.9%) were diagnosed benign and malignant lesion respectively on USG.
- In the present study, out of 52, maximum i.e. 29 (55.8%) had hypoechoic lesion on USG.
- In the present study, out of 52, 9 (17.3%), 9 (17.3%), 10 (19.2%), 4 (7%) and 3 (5.8%) had calcification, architectural distortion, internal vascularity, post acoustic shadowing and post acoustic enhancement respectively on USG.
- In the present study, out of 52, 34 (65.4%) and 18 (36.6%) were diagnosed benign and malignant lesion on biopsy/FNAC.
- In the present study, out of 52, most common pathology was fibroadenoma and found in 13 (25%) participants.
- In our study, sensitivity, specificity, PPV and NPV of mammography was 88.2%, 95.5%, 93.8% and 91.3% respectively.
- In our study, sensitivity, specificity, PPV and NPV of USG was 82.4%, 96.5%, 93.3% and 87.5% respectively.
- In our study, sensitivity, specificity, PPV and NPV of combined USG and mammography was 88.9%, 100%, 100% and 93.5% respectively.

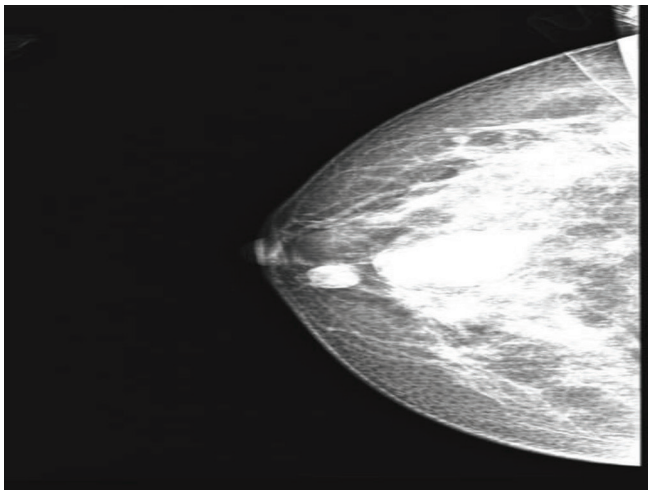

Plate-7: Breast cyst on mammography

DISCUSSION

Mammography

Mammography is a cost-effective and widely-accepted technique for evaluating breast lesions and is regarded the gold standard in the evaluation of breast masses. Mammography is used to rule out the existence of cancer and screen for any further lesions in the ipsilateral and contralateral breast in patients with palpable breast lumps. Mammography, on the other hand, has an estimated false-negative rate of 4 percent to 12 percent in the presence of a palpable breast mass, which is mostly based on the patient's age and the density of the breast under evaluation. Malignancy cannot be ruled out even if the mammographic findings of a palpable tumour are negative.

Mammography can be used to search for microcalcifications

and architectural distortion in breast masses, as well as speculated borders and so identify the lesion's probable malignant nature. It can also be used to screen for occult disease in the surrounding tissue. Mammography has proven to be a useful diagnostic tool for distinguishing between benign and malignant characteristics of palpable breast masses.

USG

Ultrasonography is an excellent complement to mammography because they are both cost-effective, readily available, and time-consuming. Only ultrasonography was previously utilised to distinguish between solid and cystic lesions. Ultrasonography can distinguish between solid and cystic lesions, which make up almost a quarter of all breast lesions.

Ultrasonography aids in diagnosis and reduces the number of invasive diagnostic tests and surgical biopsies in cases when solid lesions and cysts are concealed by dense fibroglandular tissue on mammography. As a result, complicated cysts or cysts that require repeated aspiration must be evaluated since they may harbour cancer.

Intense hyperechogenicity, ellipsoid shape, soft lobulations, thin echogenic pseudocapsule, and less than four gentle lobulations are USG markers that aid in evaluating the benign nature of the lesion. Malignant features include spiculations, angular edges, shadowing, microlobulations, and microcalcifications.

Hence many of the times, other modalities are needed to compliment the primary diagnosis given on mammography. Additional imaging with sonography is appropriate in most instances, with the exception of lesions that are mammographically benign as or lesions that are highly indicative of malignancy, in which sonographic imaging would not add any additional information.

Combined USG and mammography

Mammography is useful in combination with sonography because it may check the ipsilateral and contralateral breasts for clinically occult lesions. It has been stated that the accuracy of sonography as a breast cancer screening technique is comparable to that of mammography. However, no research has been done on the role of sonographic screening for further lesions in symptomatic patients.

In our study, out of 31 benign, 29 (93.5%) patients were categorized as benign and out of 16 malignant lesion on biopsy, all (100%) as malignant after a combined mammographic and sonographic evaluation, clearly showing the value of imaging in helping avoid unnecessary biopsies in these patients.

In our study, sensitivity, specificity, PPV and NPV of combined USG and mammography was 88.9%, 100%, 100% and 93.5% respectively.

Finally, though mammography and ultrasonography have their own advantages and limitations. No single investigation is 100% accurate but combination of mammography and ultrasonography can yield near 100% results.

Fewer unneeded biopsies are performed as a result of combined imaging examination. Perdue et al found cancer 81 in 11.1 percent of 623 excisional biopsy specimens of palpable breast. In this study, 47 of 50 palpable anomalies were subjected to biopsy based on imaging findings, with 17 of them (36.17 percent) revealing malignancy.

Donegan et al. (2002) reported in study research that the majority of breast tumours present as palpable lumps, which are frequently discovered by patient 51. Not all perceptible anomalies, however, are separate masses.

Previous research has looked into the efficacy of combining mammographic and sonographic imaging in symptomatic individuals. In 368 cases, Moss et colleagues observed a sensitivity of 94.2 percent and a specificity of 67.9%. Shetty MK and Shah YP (2002) found that their sensitivity was 100 percent and their specificity was 80.1 percent. Barlow et al. showed an 87 percent sensitivity, 88 percent specificity, and a 22 percent positive predictive value 9. Their findings are comparable to current findings in patients with palpable breast masses, which show a sensitivity of 88.8% and a specificity of 100%.

In a study conducted by Shetty et al (2002), combined use of mammography and sonomammography for the evaluation of palpable breast masses was demonstrated to have greater sensitivity (100%), negative predictive value (100%), and specificity (80.1%).

According to a 2013 study by Taori et al (2013), the specificity of mammography and sonomammography in the diagnosis of malignant breast masses was 93.3 percent and 86.6 percent, respectively, with 97 percent when both sonography and mammography were utilised in concordance. Zonderland et al (1999). reported similar findings in 1999, finding that mammography's sensitivity and specificity were 83 percent and 97 percent, respectively, while the combined sensitivity and specificity of mammography and sonomammography were 91 percent and 98 percent, respectively

CONCLUSION

This study demonstrates that ultrasonography and mammography have a greater combined specificity for detecting breast lumps, including cancers. Early detection of malignant breast lesions, differentiation of benign and malignant lesions, avoidance of unnecessary pre-operative invasive procedures, and management of palpable breast lesions all benefit from mammography using sonography as an adjuvant in evaluating the breast lump. By use of concordant mammographic, ultrasonography and FNAC results, we could correlate each modality with FNAC results and concluded that the most accurate method was when both the modalities were combined.

REFERENCES

1. Abhinaya, K. S. L. (2020), 'Evaluation of breast lesions with Ultrasonography and Mammography in Correlation with FNAC/HPE' IOSR Journal of Dental and Medical Sciences (IOSR-JDMS), 19(7), pp. 46-55
2. Andersson, I. and Sigfússon, B. F.(1995), 'Breast imaging. In: Pettersson H editor. A global textbook of radiology. Sweden, The NICER Institute publisher, pp.

627-68.
3. Anto, J. R. et al. (2019), 'Radiological and cytological correlation of breast lesions with histopathological findings in a tertiary care hospital in costal Karnataka' International Journal of Contemporary Medical Research, 6(2), pp. B1-B4.
4. Babu,G.R. et al. (2013), 'Epidemiological correlates of breast cancerinSouthIndia'Asian PacJ Cancer Prev, 14, pp.5077–83.
5. Badgwell, B.D. et al. (2008), 'Mammography before diagnosisamong women age 80 years and older with breast cancer' J Clin Oncol, 26(15), pp. 2482-8.
6. Badu-Peprah,A. et al. (2018), 'Accuracy of clinical diagnosis, mammography and ultrasonography in preoperative assessment of breast cancer'GhanaMed , 52(3), pp. 133-139.
7. Balasundaram, A. N. (2019), 'A comparative study with clinico-pathological correlation between ultrasonography, mammography and fine needle aspiration cytology in evaluation of breast lumps in coastal population of Karaikal' IAIM, 6(9), pp. 21-27.
8. Boerner, S. and Sneige, N. (1998), 'Specimen adequacy and false-negative diagnosis rate in fine-needle aspirates of palpable breast masses' *Cancer,* 84(6), pp. 344–348.
9. Bukhari, M. H. et al. (2011), Use of fine-needle aspiration in the evaluation of breast lumps' Pathology Res Int,;2011, p. 689521.
10. Chala,L. et al. (2007), 'Gray-ScaleSonographyofSolid BreastMasses:DiagnosisofProbablyBenignMassesand ReductionoftheNumberofBiopsies, Journal ofClinical Ultrasound,35(1), pp. 13-9.
11. Chopra, B. et al. (2014), 'Kaur V, Singh K et al. Age shift: breast cancer is occurring inyoungerage groups—isittrue?ClinCancerInvestig J,3, pp.526–29.
12. Costantini, M. et al. (2006), 'Characterization of Solid Breast Masses-Use of the Sonographic Breast Imaging Reporting and Data System Lexicon' J Ultrasound Med, 25, pp. 649-59.
13. Del Cura, J. L. et al. (2005), 'The Use ofUnenhanced Doppler Sonography in the Evaluation of Solid Breast Lesions' AJR2005, 184, pp.1788-94.
14. DeSantis, C. et al. (2011), 'Breast cancer statistics, 2011' CA CancerJClin, 61(6), pp. 409-18.

Source of Support: Nil; **Conflict of Interest:** None

Submitted: 25-04-2022; **Accepted:** 28-05-2022; **Published:** 30-06-2022