Barium Bronchography in an Undiagnosed Tracheoesophageal Fistula

Kedia Yash S[1], Nair Jairaj P[2], Thorve Swapnil[3], Waghmare Siddharth[4]

ABSTRACT

Tracheoesophageal fistula (TEF) is a rare complication of intubation which results from prolonged mechanical ventilation. The high cuff pressure is responsible for tracheal injury and TEF formation. TEF is a diagnostic challenge and requires surgical management.

We present a case of a 43-year-old male complaining of dysphagia with a previous history of mechanical ventilation. Barium swallow was done to evaluate the cause of dysphagia. There was immediate spillage of the dye into the conducting airways. Further investigations revealed a TEF.

Keywords: Barium Bronchography, Tracheoesophageal Fistula

INTRODUCTION

Endotracheal tubes are a common interface used to provide mechanical ventilation to the patients in ICU. It can be an elective or emergency procedure. However, it can be a traumatic process and can result in complications like oral bleed, injury to the teeth, tracheal stenosis, loss of voice, injury to the trachea, subcutaneous emphysema, etc. Tracheoesophageal fistula (TEF) is one such complication that can occur post prolonged mechanical ventilation. TEF typically develops after prolonged intubation which may range from 12-200 days of mechanical ventilation with an average of 42 days.[1]

We here report a case of post-intubation TEF which developed after just 7 days of mechanical ventilation.

CASE

A 43-year-old male presented to the hospital with right hypochondriac pain and tenderness, fever and breathlessness. His chest X-ray revealed an air-fluid level under the right dome of the diaphragm and right-sided pleural effusion. In order to remove the focus of infection, along with iv antibiotics, a pigtail was inserted in the liver and an intercostal drainage tube (ICD) in the right pleural space. In view of his deteriorating condition, he was intubated and put on mechanical ventilation for 7 days (Fig. 1). The patient's condition improved and was discharged. However, after two months of discharge, he developed new symptoms of progressive breathlessness, productive cough, multiple episodes of vomiting and dysphagia to both solid and liquid food. The chest x-ray now showed ill-defined reticular opacities in bilateral lung fields (Fig. 2). Barium swallow under dynamic fluoroscopy was done to look for oesophageal strictures or obstruction. Dynamic fluoroscopy demonstrated the immediate movement of barium in the airways with some amount in the esophagus and the stomach (Fig. 3 & 4). The patient was conscious and oriented during the study. A CT Chest with neck cuts was done to further elucidate this phenomenon. It revealed multiple centrilobular nodules with tree in bud appearance in bilateral lung fields (right more than left) (Fig. 5). It also revealed a 16mm tracheoesophageal

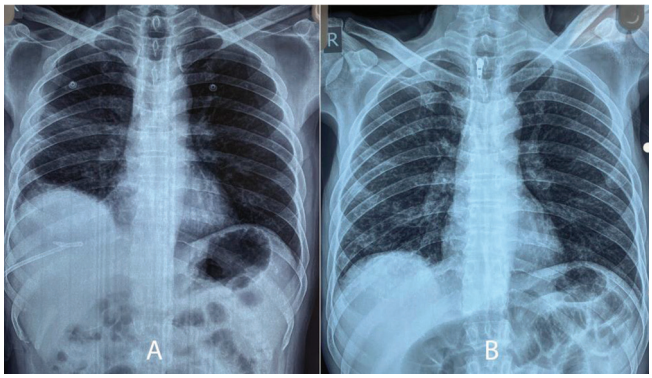

Figure-1: (A) Chest X-Ray of the patient during the first admission showing elevated right hemidiaphragm and pigtail in the liver. (B) Chest X-Ray of the patient during the second admission showing elevated right hemidiaphragm with few reticular opacities in B/L lung fields.

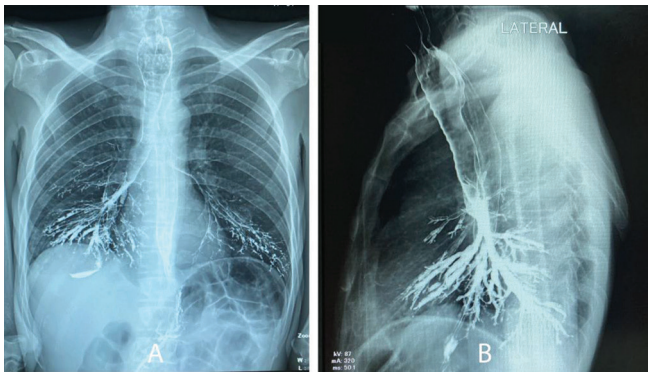

Figure-2: (A) and (B): Chest X-Ray PA & Lateral view after barium swallow showing barium in the airway as well as the oesophagus.

[1]Junior resident, Department of Respiratory Medicine, LTMMC, Mumbai, [2]Professor & Head, Department of Respiratory Medicine, LTMMC, Mumbai, [3]Assistant Professor, Department of Respiratory Medicine, LTMMC, Mumbai, [4]Assistant Professor, Department of Respiratory Medicine, LTMMC, Mumbai, India

Corresponding author: Dr. Yash Kedia, Room no 409, Old RMO Hostel, Sion Hospital, Mumbai – 400012, India

How to cite this article: Kedia Yash S, Nair Jairaj P, Swapnil T, Siddharth W.Barium bronchography in an undiagnosed tracheoesophageal fistula. International Journal of Contemporary Medical Research 2022;9(5):E1-E3.

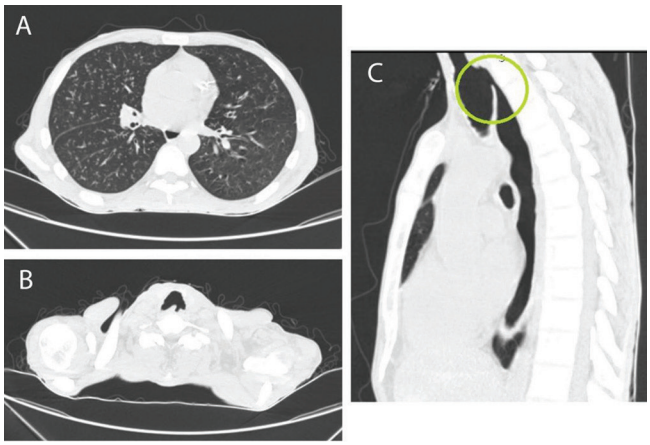

Figure-3: (A) HRCT Chest of the patient showing B/L ill defined centrilobular nodules with VY branching pattern (Rt>Lt). (B) HRCT Chest showing a fistula arising from the trachea. (C) Sagittal cuts on HRCT Chest showing the TEF (Marked in green circle).

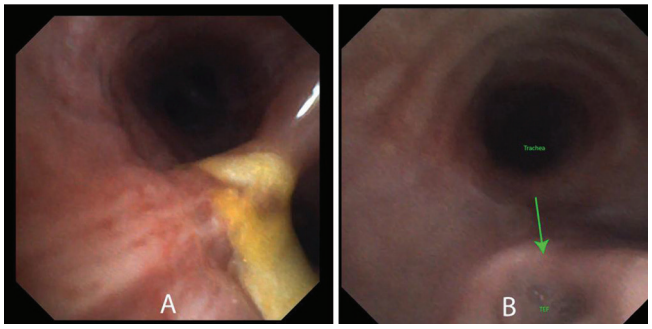

Figure-4: (A) Bronchoscopic view showing food particles in the airway (Left bronchus view). (B) Bronchoscopic view showing the TEF (Marked by the green arrow).

fistula just below the upper esophageal sphincter (Fig. 6 & 7). A fiberoptic bronchoscopy revealed food particles in the trachea and bronchus (Fig. 8). A fistula opening was observed just below the vocal cords (Fig. 9). Bronchial washings were collected to rule out superadded infection. Percutaneous gastrostomy was done for nutrition and surgical opinion was taken for definitive management.

DISCUSSION

Tracheoesophageal fistula is an abnormal connection between the trachea and the esophagus. It acts as a conduit for the movement of non-sterile contents of the esophagus into the sterile milieu of the respiratory system, which can lead to fatal pulmonary complications. TEF can be congenital or acquired. Acquired TEFs occur secondary to malignant disease, infection (especially tuberculosis), ruptured diverticula, and trauma.

Oral bleed, erosion of the trachea, granulation tissue formation at the site of the cuff, loss of voice, tracheal stenosis, subcutaneous emphysema, and in some cases tracheoesophageal fistula can occur as a complication of cuffed endotracheal tube. Postintubation TEFs is an uncommon complication of endotracheal or tracheostomy tube. It can develop anytime from 12–200 days after intubation, with an average of 42 days.[1,2] However, there are reports of TEF developing as early as 7 days post-intubation.[3] Cuff pressure is the primary driver for the formation of a fistula. Failure to maintain safe cuff pressures can result in tracheal injuries.[4] TEFs are estimated to occur in 0.5% to 1% of prolonged ventilated patients.[4] When cuff pressure exceeds >30 cm H2O it compresses mucosal capillaries and impairs blood flow in the tracheal tissue. Ischemia ensues and leads to tissue necrosis.[5] TEFs can occur rarely with tracheostomy or malpositioning of the tracheal tube secondary to improper tracheal incretion. The malpositioned tracheostomy tube exerts pressure against the esophagus, resulting in tissue damage and a TEF.

A high index of suspicion is required to diagnose a TEF, especially in patients on mechanical ventilation. A constant air leak, recurrent pneumonia, respiratory distress, presence of enteral feed in tracheal aspirate, and gastric distension are indicators of the presence of TEF. Symptoms of productive cough, dysphagia, and recurrent pneumonia in an ambulant patient with a history of intubation should raise the suspicion of TEF.

For diagnosis of a TEF, barium swallow can be performed which may show aspiration of barium in the tracheobronchial tree. A barium study in a prone position with a lateral view may sometimes delineate the fistula. A CT scan of the neck and chest with or without oral contrast can also demonstrate the fistula. The upper gastrointestinal scopy aids in visualizing the oesophageal opening of the fistula and the tracheal opening can be seen with bronchoscopy.

In an intubated patient, once the fistula is diagnosed, the cuff should be repositioned distal to the fistula and the cuff should be periodically deflated to minimize the inflammation. To avoid aspiration of feeds, the patient's head end should be elevated and a nasogastric tube insertion or gastrostomy should be done. If a gastrostomy is placed, it should be kept on drainage to reduce the reflux of gastric contents.[6]

The definitive treatment is surgical. Surgical tracheal anastomosis risks dehiscence with positive pressure therefore surgery should always be done once the patient is off mechanical ventilation.[7] Some reports have shown successful closure of small TEF (<5mm) by endoscopic procedures as well.[8]

Prolonged ventilation is a risk factor for TEF. Early extubation should be attempted in all patients. Regular monitoring of cuff pressures, periodic cuff deflation will reduce the occurrence of TEF in patients requiring prolonged ventilation

CONCLUSION

Complaints of dysphagia in a patient with a history of intubation is a harbinger of TEF. TEF can increase morbidity, hospital visit and reduce the health-related quality of life of the patients. Adequate measures should be taken while on mechanical ventilation to prevent this fatal complication in patients requiring prolonged intubation.

REFERENCES

1. Marzelle J, Dartevelle P, Khalife J, Rojas-Miranda

A, Chapelier A, Levasseur P. Surgical management of acquired post-intubation Tracheo-oesophageal fistulas:27 patients. Eur J Cardiothorac Surg. 1989; 3: 499–502.

2. Smith, H. M., Bacon, D. R., & Sprung, J. Difficulty assessing endotracheal tube placement in a patient with undiagnosed iatrogenic tracheoesophageal fistula. Journal of cardiothoracic and vascular anesthesia, 2006; 20: 223–224.
3. Kaur, D., Anand, S., Sharma, P., & Kumar, A. Early presentation of postintubation tracheoesophageal fistula: Perioperative anesthetic management. Journal of anaesthesiology, clinical pharmacology. 2012; 28: 114–116.
4. Muniappan, A., Wain, J. C., Wright, C. D., Donahue, D. M., Gaissert, H., Lanuti, M., Mathisen, D. J. Surgical treatment of nonmalignant tracheoesophageal fistula: a thirty-five year experience. The Annals of thoracic surgery. 2013; 95: 1141–1146.
5. Hameed AA, Mohamed H, Al-Mansoori M. Acquired tracheoesophageal fistula due to high intracuff pressure. Annals of Thoracic Med. 2008; 3:23-25.
6. Reed MF, Mathisen DJ. Tracheoesophageal fistula. Chest surgery clinics of North America. 2003; 13:271-289.
7. Mooty, R. C., Rath, P., Self, M., Dunn, E., Mangram, A. Review of tracheo-esophageal fistula associated with endotracheal intubation. Journal of surgical education. 2007; 64: 237–240.
8. Ahmad Zaheen and Matthew B. Stanbrook. Accidental barium bronchography, Canadian Medical Association Journal. 2017; 189 (18) E670

Source of Support: Nil; **Conflict of Interest:** None

Submitted: 25-03-2022; **Accepted:** 28-04-2022; **Published:** 31-05-2022