

Incidence, Clinical Presentation and Management of Type IV Perforations after Sphincterotomy among Post ERCP Patients

Mir Intikhab Maqbool¹, Showkat Ahmad Kadla², Syed Asif Rafiq³

ABSTRACT

Introduction: ERCP related perforation is an endoscopic emergency. Presence of retroperitoneal air after ERCP always is not an indication for emergency surgery. Aim of this study is to determine the incidence of Type IV perforations and management of patients with Type IV perforation.

Material and methods: This was a prospective hospital based study, in these study 111 consecutive patients after fulfilling the inclusion and exclusion criteria were enrolled.

Results: Incidence of Type IV perforation in the study is 7.2%. Patients with type IV perforation have varied clinical presentation. All patients with Type IV perforation were managed conservatively.

Conclusion: ERCP related Type IV perforations occur in a significant number of patients undergoing ERCP. Patients in whom an ERCP related perforation is suspected should undergo an urgent CECT abdomen with oral contrast to rule out extravasation of contrast. Patients with contrast extravasation should be managed by emergency surgery. Patients with type IV perforation should be managed conservatively.

Keywords: Choledocholithiasis, Sphincterotomy, ERCP, Perforation.

INTRODUCTION

Endoscopic retrograde cholangiopancreatography (ERCP) is a common, well established procedure that is being used with increasing frequency for the evaluation and treatment of biliary tract and pancreatic duct disease. In the recent years the therapeutic use of ERCP has increased 30 fold.¹ The success rate of ERCP varies markedly between institutions.² The short term complication rate of ERCP is around 10% and includes acute pancreatitis, bleeding, cholangitis and perforation.³ In the hands of an expert, endoscopic retrograde cholangiopancreatography (ERCP) and endoscopic sphincterotomy (ES) are associated with high rates of success and few complications, most of which can be treated conservatively.⁴ Although the post-ERCP complications are varied, in this paper we study the complications related to perforations. More specifically we study the incidence of type-IV perforations. ERCP related perforations have been classified by various researchers based on the location of perforation and mechanism of injury, the most popular of these classifications was proposed by Stapfer et al.¹⁵ ERCP related perforations have been classified into four types¹⁵, Type I, lateral or medial wall duodenal perforation; type II, paravaterian injuries; type III, distal bile duct injuries related to guide wire-basket instrumentation and type IV, retroperitoneal air alone.¹⁵ Presence of free air after an ERCP

has been found to be present in 13-29% of asymptomatic patients.¹⁶

Many patients with ERCP related perforations may be managed conservatively or may need an emergency surgical intervention.¹⁷ ERCP related perforation although rare can have a mortality rate of as high as 37.5%.¹⁸ The causes of perforation include patient related factors such as Billroth II gastrectomy and technical factors such as inexperienced endoscopist, difficult cannulation, precut, and sphincterotomy.¹⁹ Early diagnosis and prompt treatment are important for better outcome.^{7,20} The diagnosis of perforation can often be suspected or made during the endoscopic procedure, but is usually confirmed radiologically by demonstrating open air cavity or leakage of contrast.

Often the physical examination can help assess the patient, but not all abdominal perforations present with an acute abdomen.²¹ Post ERCP perforations can be managed conservatively or may need an emergency surgical exploration. Proper management of post ERCP perforation depends on type of injury and time of diagnosis of perforation after ERCP. Type I perforations are large, usually discovered during the ERCP procedure. They require immediate surgery or urgent endoscopic treatment, both type II and III perforations may be managed non surgically but require close surveillance, Type IV perforations which are not true perforations require no surgical intervention and are usually managed successfully by conservative management.²²

The aim of this study was to determine the incidence of type IV perforations in the patients undergoing ERCP and also to determine the clinical profile and management of the patients with type IV perforations.

Experimental Design

A hospital based observational analytical study was done. This study was conducted in the department of gastroenterology and hepatology, Government Medical College Srinagar

¹Resident, Department of Gastroenterology, ²HOD, Department of Gastroenterology, ³Resident, Department of Gastroenterology, Government Medical College, Srinagar

Corresponding author: Mir Intikhab Maqbool, Resident, Department of Gastroenterology, Government Medical College, Srinagar

How to cite this article: Maqbool MI, Kadla SA, Rafiq SA. Incidence, clinical presentation and management of type IV perforations after sphincterotomy among post ERCP patients. International Journal of Contemporary Medical Research 2021;8(9):11-16.

DOI: <http://dx.doi.org/10.21276/ijcmr.2021.8.9.9>



(J&K) over a period of 2 years from May 2018 to June 2020. Informed consent of the study participants was obtained in all cases. The study had approval of College ethical committee. A pro-forma was designed that recorded both demographic information like name, age, gender as well as the clinical profile like indication of ERCP (cholelithiasis, choledocholithiasis, biliary pain, cholangitis), values of lab results like serum amylase and CT findings. The data was then entered vary carefully into a spread-sheet. Later on both spread-sheet and SPSS softwares were used to analyze the data.

A total of 111 patients were included in our study. To estimate our sample size for the study we had done a power calculation with alpha value of 0.05 and power of the experiment set at 80% and the calculation revealed that a sample size of 26 or more be sufficient for the study.^{35,36} Patients of all the ages and both the genders who were subjected to ERCP for the first time were included in the study. Patients admitted in our hospital during the 2 year period satisfying the inclusion and exclusion criteria and who underwent ERCP first time in our hospital were included in the study. ERCPs were performed by experienced consultants in our department. Drugs such as midazolam and hyoscine were used as premedication and during the procedure. All the patients after undergoing ERCP were observed for 24 hours. The enrolled patients were subjected to history and physical examination before and after ERCP.

The nature of the procedure and possible complications were explained to the patients and their attendants. Post-ERCP patients were subjected to clinical examination to look for signs of peritoneal irritation, abdominal distension, subcutaneous emphysema and pneumomediastinum. Serum amylase levels will be measured 6 hours after the procedure. NCCT chest abdomen pelvis with oral contrast was done in all patients within 24 hours after the procedure. The presence of pneumomediastinum, retroperitoneal air, contrast extravasation and its location was recorded. All patients with diagnosis of type IV perforations were kept NPO, and were given IV fluids, IV antibiotics. Patients in this group were subjected to clinical examinations frequently and their vitals were recorded frequently so as to detect organ failure or clinical deterioration at the earliest.

Exclusion Criteria

- Billroth II and Roux en Y gastrojejunostomy.
- Recent Paracentesis.
- Recent surgery.
- Pregnancy.
- Previous ERCP.
- Biliary malignancy.
- Pancreatic head malignancy.

Ethical consideration

The study design, method of data collection, consent form and patient information sheets were analyzed by the institutional ethics committee at Government Medical College Srinagar, as a part of the procedure necessary for the approval of researches that involve the human interventions.

The study was conducted after approval by the institutional ethics committee.

Informed consent forms

Appropriate consent forms were designed for seeking written consent which was approved by the institutional IEC. Patients and attendants were explained the nature of the procedure, risks involved, possible complications. After explaining the procedure clearly, the participants were requested to sign the consent form for the study. A patient information sheet was also signed by each participant after explaining the protocol and its requirements.

Participant confidentiality

Patient confidentiality was fully maintained. Every patient was given an ID for further reference. All the data entries were made by using patient IDs. The data collected stayed with the researcher and was filed regularly by the researcher to be kept under safety.

RESULTS

This is an observational analytical study. The data was entered in Microsoft Excel sheet. Chi-square test was used to analyze the relationship between the categorical variables and post ERCP type IV perforation. A p-value of < 0.05 was considered statistically significant.

This is a prospective, hospital based study conducted in the department of medical gastroenterology SMHS Srinagar conducted from June 2018 to June 2020. All patients with history of biliary pain, cholangitis, and acute pancreatitis secondary to stone disease were enrolled in this study. During the study period 111 patients of all ages, sexes were enrolled. Out of 111 registered patients, 10% of patients developed perforations (see Figure 1).

Out of these 10% one patient (0.9%) developed duodenal perforation with evidence of contrast extravasation (Stauffer type I), two patients (1.8%) developed paravaterian perforations with evidence of contrast leak in second part of duodenum and 8 patients (7.2%) showed evidence of only air leak without evidence of contrast extravasation (Stauffer type IV). We performed two proportion tests³⁴ to compare the proportion of type of perforations. It was observed that the difference in the proportion of type I and type IV perforations is significant ($X^2(1, 111) = 5.18, p < 0.05$). Similarly comparison between the proportions of type III and type IV perforations revealed a significant difference ($X^2(1, 111) = 8.01, p < 0.05$). However, all other pairwise comparisons revealed a non-significant difference of proportions (see Figure 2).

The most common indication of ERCP in our study is biliary pain (73%) followed by acute cholangitis (20%) and acute pancreatitis (7%). Patients in this study were subjected to sphincterotomy, Precut, depending on the type of papilla, experience of the endoscopist. Although type IV perforations are caused by either precut or sphincterotomy or a combination of both however, there was no statistically significant relation between the type of procedure and type IV perforations ($X^2(2, 111) = 0.64, p = 0.72$) (see Figure 3).

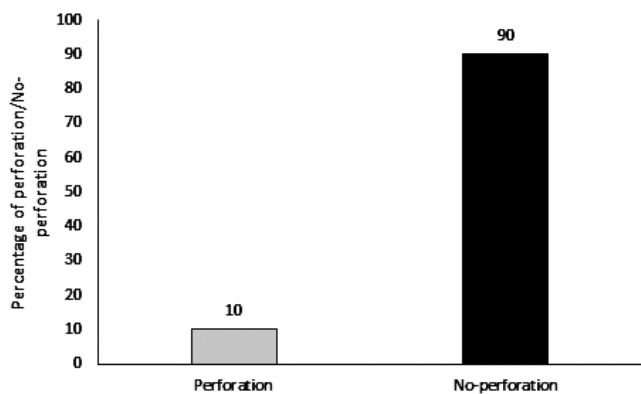


Figure-1: Percentage of perforations

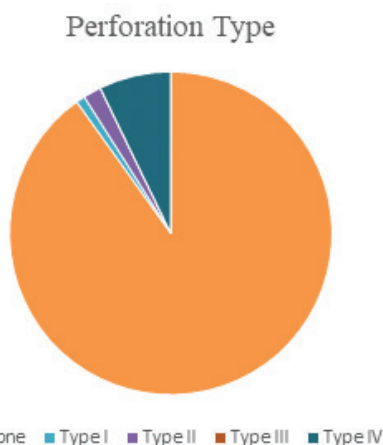


Figure-2: Relative proportion of various types of perforations

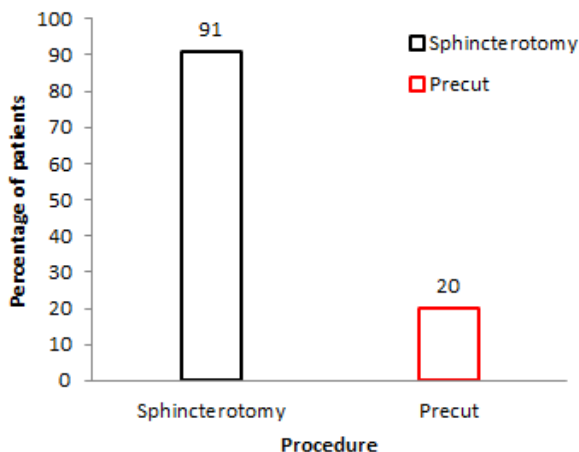


Figure-3: Various procedures done for cannulation and their respective percentages.

Most common finding in post ERCP CT chest abdomen pelvis with oral contrast is pneumobilia (82%) (see Figure 4). CT was unremarkable in 5% patients. Pneumoperitoneum without evidence of contrast leak was found in 7.2% patients. Pneumoperitoneum with evidence of contrast leak was found in 2.8% patients. Thus incidence of type IV perforation in our study is 7.2%.

All patients in the study who developed type IV perforation were females and above 40 years of age and this difference in the percentage of males and females across the perforation types is statistically significant ($\chi^2(1, 8) = 4.17$,

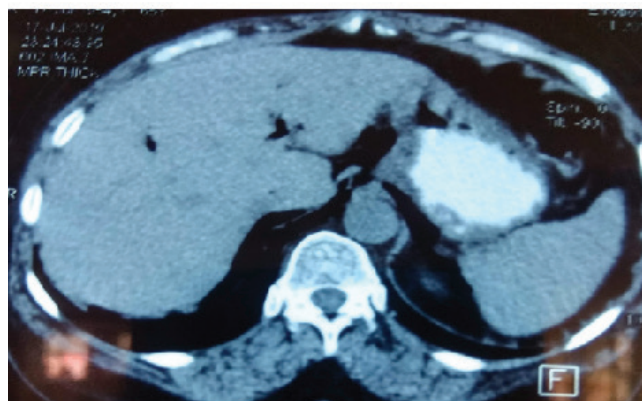
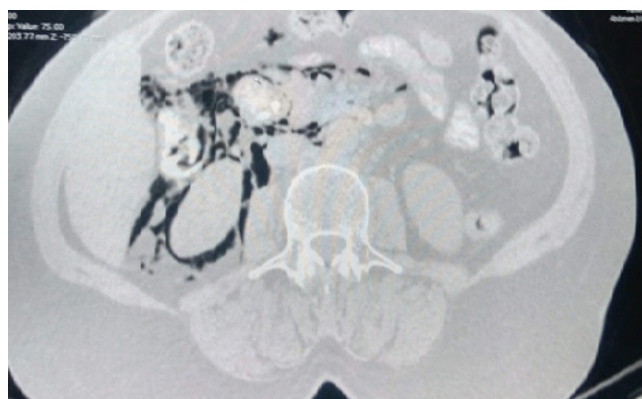


Figure-4: Representational NCCT images showing presence of (a) Retroperitoneal air (b) Pneumobilia.

$p < 0.05$). Seven out of 8 patients were having diagnosis of choledocholithiasis with biliary pain and one patient was having diagnosis of gall stone related acute pancreatitis. Post-ERCP one patient was having sub-cutaneous emphysema on clinical examination, 4 patients were having pain abdomen. Three patients were asymptomatic and type IV perforation was diagnosed incidentally on NCCT abdomen with oral contrast. Thus clinical presentation of patients with type IV perforation is varied.

All patients with type IV perforation in our study were managed conservatively with NPO, broad spectrum IV antibiotics. All patients with type IV perforation improved after conservative management, although the number of hospitalization days was prolonged by an average of 7 ± 3 days. All patients with type IV perforation were discharged successfully. None of the patients with type IV perforation needed a surgical intervention.

DISCUSSION

ERCP is an important therapeutic modality for the treatment of a number of biliary and pancreatic diseases. Since ERCP is an invasive procedure, with the advent of MRCP, ERCP has largely been used as a therapeutic modality. During a routine ERCP session we encountered a 53-year-old female patient with history of biliary pain and MRCP documented choledocholithiasis was admitted for an elective ERCP. The patient underwent ERCP and after the procedure, the patient complained of pain in the abdomen and vomiting. ERCP related perforation is a serious complication and has several important implications such as cost of treatment, length of

hospital stay, morbidity and mortality.

We conducted a prospective observational, hospital based study in the department of gastroenterology and hepatology for a period of 2 years from May 2018 to May 2020. A total of 111 patients were included in our study after fulfilling the exclusion criteria. The average age of patients in this study was 50.19. Majority of the subjects were female compared to males. This can be attributed to the fact that biliary tract stone disease is more common in females than males.

Majority of patients in our study was from rural areas in comparison to patients from urban areas. The most common indication of ERCP in our study is biliary pain followed by cholangitis and acute pancreatitis. Several researchers have classified ERCP related perforations according to the location and mechanism of injury. Stapfer et al classified perforations into four types according to the location and mechanism of injury (1) Type I, lateral or medial duodenal wall perforation, ERCP scope related. (2) type II, periampullary or paravaterian, sphincterotomy related. (3) type III, Ductal perforations due to wire manipulation or basket instrumentation during stone retrieval and occur in distal CBD (4) type IV, tiny retroperitoneal perforations caused by the use of compressed air during endoscopy. Second classification system has been proposed by Howard et al, which includes three groups (1) Group I, guide wire perforations (2) Group II, periampullary perforations and (3) Group III, Duodenal perforations. Third classification system has been proposed by Enns et al. Group I: esophageal, gastric, duodenal perforations, Group II sphincterotomy related perforations, Group III guide wire related perforations.³³

ERCP has been widely practiced for more than 35 years, progressively evolving from a diagnostic to a therapeutic role. The risk of serious complications has been identified early and has been the focus of many studies and reviews.¹⁷ Non-invasive imaging, such as MRCP and EUS, have largely superseded diagnostic ERCP, and the safety profile of surgery has greatly improved.¹⁸ Subcutaneous emphysema after an ERCP is a rare but well-recognized complication.¹⁹ Prolonged air insufflation leads to dissection of air through the tissues. An alternative explanation is the leakage of air along the perineural and perivascular sheaths.²⁰ The type of post ERCP perforation should guide towards operative or non-operative management.

Type I perforations can be diagnosed during the procedure as a result of direct visualization of the retroperitoneal space or the abdominal cavity.²⁴ In cases with bleeding and lack of a clear view, fluoroscopy with or without contrast injection can help in diagnosis.²² Type II perforations can be suspected after a sphincterotomy and confirmed by fluoroscopy, the later showing the presence of retroperitoneal air, especially around the right kidney.²³ Contrast injection can also depict contrast leaking at sphincterotomy site.²⁵ Type III perforations can be picked up by the unusual passage of the guide wire.²⁶ Pre-cutting is dangerous and thus ERCP including pre-cutting needs to be done by experienced endoscopist.²⁷ After every ERCP, the patient should be examined carefully and appropriate laboratory investigations should be done to

detect any perforation. The duodenum should be inspected carefully while doing the procedure and X-ray abdomen should be done to look for the presence of retroperitoneal air. Patients with air leaks can present hours after procedure with pain, fever and leucocytosis. In type I perforations, the diagnosis is usually obvious with severe pain and signs of peritonitis.²⁷ When a patient complains of severe pain after ERCP, acute pancreatitis and perforation need to be ruled out.²⁸ In retroperitoneal perforations the diagnosis is not straight forward.²⁸ The patient may report epigastric pain but no signs of peritonitis.²⁹ Subcutaneous emphysema may be evident from the first hours after the procedure.³⁰ Leucocytosis and fever are often seen several hours after completion of the procedure.³¹ In patients with suspected perforation, a CT scan with oral contrast should be done. Retroperitoneal air can be picked up by plain films, but CT scan is more sensitive.³²

Free perforation indicates a serious complication; with associated high mortality approaching 25%. The diagnosis of free perforation can be made by the demonstration of air in the peritoneum and evidence of contrast leak on CT abdomen with oral contrast. Physical examination can be helpful in identifying the patients who develop ERCP related perforation, however all patients with perforation do not present with an acute abdomen.

In our study 8 patients developed type IV ERCP related perforation. Out of these 8 patients 5 patients were having pain abdomen in the Post ERCP period and one patient was having subcutaneous emphysema in the cervical region. Of these 8 patients who developed type IV perforation, the diagnosis of perforation was made immediately in the post ERCP period in only one patient because of the presence of subcutaneous emphysema in the cervical and thoracic regions on physical examination. The length of procedure lasted less than 60 minutes in all the cases. The finding of retroperitoneal air is not associated with the duration of the procedure. Among these 8 patients who developed type IV perforation, endoscopic sphincterotomy was done in 6 patients and precut was done in 2 patients. Thus in our study more number of patients who developed type IV perforation has undergone endoscopic sphincterotomy as compared to precut but it is not statistically significant. Of these 8 patients who developed type IV perforation serum amylase was above the upper limit of normal in only 2 patients. Thus hyperamylasemia has no association on the incidence of type IV perforation. Of these 8 patients who developed type IV perforation 6 patients were complaining of abdominal pain that lasted for 3-4 days and other 2 patients were completely symptom free. Thus patients with type IV perforation can have pain in the post ERCP period that lasts for few days or these patients may be completely asymptomatic. All the patients in our study who developed type IV perforation were managed conservatively by I/V fluids, antibiotics, analgesics, parenteral nutrition. All the patients who developed type IV perforation were successfully discharged from the hospital, although the length of hospital stay was prolonged in this group of patients (7-10 days).

CONCLUSION

ERCP is an invasive procedure used for the treatment of a number of biliary and pancreatic disorders. Due to its invasive nature, it may be associated with a number of complications including post ERCP pancreatitis, cholangitis, perforation and bleeding. Successful management of ERCP related perforations requires immediate diagnosis and early decision to decide whether to manage conservatively.

Endoscopic retrograde cholangiopancreatography (ERCP) is an invasive procedure used for the treatment of a number of biliary and pancreatic disorders. Due to its invasive nature, it may be associated with a number of complications including PEP, cholangitis, and perforation and bleeding. The objectives of this were to determine the incidence of type IV ERCP related perforations, and to determine the clinical profile and management of these patients with type IV perforation.

This is a hospital based prospective study conducted in the Department of Gastroenterology, Government Medical College Srinagar. Patients of all ages and both sexes who were subjected to ERCP and after fulfilling the exclusion and inclusion criteria were enrolled in this study. One hundred eleven consecutive patients who underwent ERCP and were fulfilling the exclusion and inclusion criteria were enrolled in this study. CBC, LFT, KFT, coagulogram, chest x-ray, ECG, HBSAg, IgG anti HCV were done prior to ERCP. Patients were monitored carefully in post ERCP period for 24 hours. Serum amylase levels were evaluated at 6 hours NCCT abdomen with oral contrast was done within 24 hours of ERCP in all the patients. NCCT abdomens with oral contrast were reported by the experienced radiologists.

Out of 111 patients who underwent ERCP, 8 patients developed type IV ERCP related perforations. Out of 8 patients 7 were female and 1 patient was male. All the patients with type IV perforation were managed conservatively, although the length of hospital stay is longer.

REFERENCES

- Moffatt DC, Yu BN, Yie W, Bernstein CN. Trends in utilization of diagnostic and therapeutic ERCP and cholecystectomy over the past 25 years: a population-based study. *Gastrointest Endosc* 2014;79:615–622
- Ekkelenkamp VE, de Man RA, Ter Borg F, Borg PC, Bruno MJ, Groenen MJ, Hansen BE, van Tilburg AJ, Rauws EA, Koch AD. Prospective evaluation of ERCP performance: results of a nationwide quality registry. *Endoscopy* 2015;47:503–507
- Wojtun S, Gil J, Gietka W, Gil M. Endoscopic sphincterotomy for choledocholithiasis: a prospective single-center study on the short-term and long-term treatment results in 483 patients. *Endoscopy* 1997;29:258–265
- Anselmi, M., Cobo, R., Benavides, C. and Pacheco, F. Endoscopic Sphincterotomy: Indications, Successes, Failures and Complications. *Revista Chilena de Cirugia*, 1998;50:268-275.
- Committee ASoP, Anderson MA, Fisher L et al. Complications of ERCP. *Gastrointest Endosc* 2012;75:467–73.
- Freeman ML and Guda NM. Prevention of post-ERCP pancreatitis: a comprehensive review. *Gastrointest Endosc* 2004;59:845–64.
- Cotton, P.B., Lehman, G., Vennes, J., Geenen, J.E., Russell, R.C.G., Meyers, W.C., Liguory, C. and Nickl, N. Endoscopic Sphincterotomy Complications and Their Management: An Attempt to Consensus. *Gastrointestinal Endoscopy* 1991;37:383-393.
- Enochsson L, Thulin A, Osterberg J, Sandblom G, Persson G. The Swedish Registry of Gallstone Surgery and Endoscopic Retrograde Cholangiopancreatography (GallRiks): a nationwide registry for quality assurance of gallstone surgery. *JAMA Surg* 2013;148:471–478.
- Katsinelos P, Lazaraki G, Chatzimavroudis G, Gkagkalis S, Vasiliadi I, Papaenthimiou A, et al. Risk factors for therapeutic ERCP-related complications: an analysis of 2,715 cases performed by a single endoscopist. *Ann Gastroenterol* 2014;27:65–72.
- Doganay M, Yuksek YN, Daglar G, Gozalan U, Tutuncu T, Kama NA. Clinical determinants of suppurative cholangitis in malignant biliary tract obstruction. *Bratisl Lek Listy* 2010;111:336–339.
- Ferreira LE, Baron TH. Post-sphincterotomy bleeding: who, what, when, and how. *Am J Gastroenterol* 2007; 102: 2850-8.
- Saeed M, Kadir S, Kaufman SL, Murray RR, Milligan F, Cotton PB. Bleeding following endoscopic sphincterotomy: Angiographic management by transcatheter embolization. *Gastrointest Endosc* 1989; 35: 300-303.
- Masci E, Toti G, Mariani A, et al. Complications of diagnostic and therapeutic ERCP: A prospective multicenter study. *Am J Gastroenterol* 2001; 96: 417–423.
- Howard TJ, Tan T, Lehman GA, Sherman S, Madura JA, Fogel E, Swack ML, Kopecky KK. Classification and management of Perforations complicating endoscopic sphincterotomy. *Surgery* 1999; 126: 658-663; discussion 664-665.
- Stapfer M, Selby RR, Stain SC, Katkhouda N, Parekh D, et al. Management of duodenal perforation after endoscopic retrograde cholangiopancreatography and sphincterotomy. *Ann Surg* 2000;232: 191–198.
- Genzlinger JL, McPhee MS, Fisher JK, Jacob KM, Helzberg JH. Significance of retroperitoneal air after endoscopic retrograde cholangiopancreatography with sphincterotomy. *Am J Gastroenterol* 1999;94:1267-1270.
- Lee TH, Bang BW, Jeong JI et al. Primary endoscopic approximation suture under cap-assisted endoscopy of an ERCP-induced duodenal perforation. *World Journal of Gastroenterology*, 2010; 16: 2305–2310.
- Ercan E, Bostanci EB, Dalgic T et al. Surgical outcome of patients with perforation after endoscopic retrograde cholangiopancreatography. *Journal of Laparoendoscopic and Advanced Surgical Techniques A*, 2012; 224: 371–377.
- Machado NO. Management of duodenal perforation postendoscopic retrograde cholangiopancreatography. When and whom to operate and what factors determine the outcome? A review article. *Journal of the Pancreas*,

- 2011; 13:18–25.
20. Guitron-Cantu A, Adalid-Martinez R, Gutierrez-Bermudez JA, Nieves-Renteria A, and Alvarez-Valdes G. Complications in diagnostic and therapeutic endoscopic holangiopancreatography. Prospective study. *Revista de Gastroenterologia de Mexico*, 2007; 72: 227–235.
 21. Bell RCW, Van Stiegmann G, Goff J, et al. Decision for Surgical Management of Perforation after Endoscopic Sphincterotomy. *The American Journal of Surgery*, 1991; 57: 237-240.
 22. Martin DF and Tweedle DE. Retroperitoneal perforation during ERCP and endoscopic sphincterotomy: causes, clinical features and management. *Endoscopy* 1990; 22: 174–175.
 23. Stapfer M, Selby RR, Stain SC, Katkhouda N, Parekh D, Jabbour N, Garry D. Management of duodenal perforation after endoscopic retrograde cholangiopancreatography and sphincterotomy. *Ann Surg* 2000;232:191–198.
 24. Colemont LJ, Pelckmans PA, Moorkens GH and Van Maercke YM. Unilateral Periorbital Emphysema: An Unusual Complication of Endoscopic Papillotomy. *Gastrointestinal Endoscopy*, 1988; 34:473-475.
 25. Preetha M, Chung YF, Chan WH, Ong HS, Chow PK, Wong WK, et al. Surgical management of endoscopic retrograde cholangiopancreatography related perforations. *ANZ J Surg* 2003;73:1011e4.
 26. Fatima J, Baron TH, Topazian MD, Houghton SG, Iqbal CW, Ott BJ, et al. Pancreaticobiliary and duodenal perforations after perampullary endoscopic procedures: diagnosis and management. *Arch Surg* 2007;142:448e54.
 27. Avgerinos DV, Laguna OH, Lo AY, Voli J, Leitman IM. Management of endoscopic retrograde cholangiopancreatography: related duodenal perforations. *Surg Endosc* 009;23:833e8.
 28. Polydorou A, Vezakis A, Fragulidis G, Katsarelias D, Vagianos C, Polymeneas G. A tailored approach to the management of perforations following endoscopic retrograde cholangiopancreatography and sphincterotomy. *J Gastrointest Surg* 2011;15:2211e7.
 29. Dubecz A, Ottmann J, Schweigert M, Stadlhuber RJ, Feith M, Wiessner V, et al. Management of ERCP-related small bowel perforations: the pivotal role of physical investigation. *Can J Surg* 2012;55:99e104.
 30. Rabie ME, Mir NH, Al Skaini MS, El Hakeem I, Hadad A, Ageely H, et al. Operative and non-operative management of endoscopic retrograde cholangiopancreatography associated duodenal injuries. *Ann R Coll Surg Engl* 2013;95:285e90.
 31. Koc B, Bircan HY, Adas G, Kemik O, Akcakaya A, Yavuz A, et al. Complications following endoscopic retrograde cholangiopancreatography: minimal invasive surgical recommendations. *PLoS One* 2014;9:e113073.
 32. Kodali S, Monkemuller K, Kim H, Ramesh J, Trevino J, Varadarajulu S and Wilcox C. ERCP-related perforations in the new millennium: A large tertiary referral center 10-year experience. *United European Gastroenterol J*. 2015; 3: 25-30.
 33. Enns R, Eloubeidi MA, Mergener K, Jowell PS, Branch MS, et al. ERCP related perforations: risk factors and management. *Endoscopy* 2002; 34: 293–298.
 34. MedCalc Software Ltd. Comparison of proportions calculator. https://www.medcalc.org/calc/comparison_of_proportions.php (Version 20.009; accessed July 19, 2021)
 35. Rosner B. *Fundamentals of Biostatistics*. 7th ed. Boston, MA: Brooks/Cole; 2011.
 36. Cohen, J. (1988). *Statistical power analysis for the behavioral sciences*, 2nd edn. Á/L.

Source of Support: Nil; **Conflict of Interest:** None

Submitted: 12-08-2021; **Accepted:** 30-08-2021; **Published:** 30-09-2021