

Role of Mammography in Diagnosis of Carcinoma of Breast

Sanjay Singhvi¹, P.S. Sagar²

ABSTRACT

Introduction: Breast cancer is the fifth most common cause of cancer deaths in world. Due to lack of awareness and social stigma, breast cancers are detected at advance stage resulting in higher mortality. Therefore aim of present study is to detect carcinoma of breast at early stages by mammography.

Material and Methods: Present study was carried out on 30 cases of breast tumour attending LLR Hospital & J.K. Cancer Research Institute of GSVM Medical College, Kanpur. Clinical, radiological and histopathological examination was done. Radiological Study (Mammography) was carried out in strict privacy. Both cranio-caudal and medio-lateral views were taken as a routine.

Results: Maximum cases (56.67%) in study was suffering from carcinoma of breast followed by 11 cases (36.67%) belonged to fibroadenoma. Incidence of carcinoma of breast was found to be slightly more in post menopausal age group i.e. 9 out of 17 (52.9%). In 9 cases, left breast was affected while in 8 cases it was the right breast. Nodular presentation of breast carcinoma was present in more than half of cases (58.7%) followed by diffuse presentation (41.3%).

Conclusion: Mammography is considered as important investigation tool for early detection of breast carcinoma and along with Ultrasonography, it has higher sensitivity rate for detection of breast masses.

Keywords: Mammography, Carcinoma, Breast Masses, Histopathological Examination.

INTRODUCTION

In developing countries like India, due to lack of awareness, females are unaware of breast pathologies and due to social stigma they are hesitant to reveal it to family person or doctor, hence they are detected usually in advanced stages comprising of inoperable masses, metastasis (Bone, Brain, Lung).¹ Various benign breast lesions like fibroadenomas, breast abscess, duct ectasia etc and malignancies like carcinoma are common pathologies of female breast. Worldwide, in females, most common cause of death due to cancer is breast cancer.²

For the first time, Albert Solomon³ (1913) used the X-rays for diagnostic purpose for breast pathologies. Mammography (X-rays) was used for early detection of malignancies in curable stages and to decrease malignancy related mortality. Mammography is a easily available, cheap and used as screening tool to detect micro calcifications, small lymph nodes and speculated masses in malignancies.⁴ By routine mammographic screening of healthy women, incidence of breast cancer could be reduced by 30%.^{5,6}

Mammography which is our objective approach to the diagnosis of breast lesions is soft tissue roentgenography of

the breast. Over the years various departure from the principle of soft tissue radiography has occurred. These changes have been mainly instituted to reduce radiation dosage to breast and to allow better imaging of dense breasts. Now the technique has developed to such an extent that satisfactory mammographic examination of breast is the method of choice in the investigation of breast disease. Even though it is more accurate in the diagnosis of breast cancer than clinical examination, it is best utilized as a complementary method of examination to clinical assessment.

Wolfe in 1967 was the first to attempt to identify various breast patterns in breast xeroradiograms which he thought might relate to subsequent carcinoma. He described two features- a 'Prominent Duct Pattern' and "Mammary Dysplasia" which indicated a higher risk of developing carcinoma. He classified breast parenchyma into four types based on the relative amount of fatty, epithelial and connective tissue. The four categories were: N₁, P₁, P₂ and DY. In a retrospective study of 7214 patients published in 1976, Wolfe reported the incidence rate of carcinoma over a three years follow up period. In all the four types of breast parenchymal patterns, he found lowest incidence of carcinoma in N₁ and highest in DY. On this, observations he grouped the mammographic patterns into two broad groups.

1. Low Risk Group: Comprising of N₁ and P₁
2. High Risk Group: Comprising of P₂ & DY

Mammography is the most commonly used method and has proven effectiveness especially in non palpable carcinoma patients.⁷⁻⁹ Therefore aim of present study is to evaluate the role of mammography in detection of malignant lesions of breast.

MATERIAL AND METHODS

Present study was conducted on cases of breast diseases attending L.L.R. Hospital, J.K. Cancer Research Institute of GSVM Medical College, Kanpur during year 1993-1994. Clinical, radiological and pathological examination was done. History, general examination and breast examination was done clinically.

¹Assistant Professor, Department of Radiodiagnosis, Prasad Institute of Medical Sciences, Lucknow (U.P.), ²Assistant Professor, Department of Radiodiagnosis, Government Medical College, Banda (U.P.), India

Corresponding author: Dr. P. S. Sagar, Assistant Professor, Department of Radiodiagnosis, Government Medical College, Banda (U.P.), India

How to cite this article: Singhvi S, Sagar PS. Role of mammography in diagnosis of carcinoma of breast. International Journal of Contemporary Medical Research 2020;7(10):J6-J10.

DOI: <http://dx.doi.org/10.21276/ijcmr.2020.7.10.19>



Radiological Study (Mammography): Both cranio-caudal and medio-lateral views were taken and at a time single breast was X-rayed.

Position

1) For Cranio-Caudal View: The patients was seated on the adjustable revolving stool in such position that maximum portion of the breast could be placed conveniently on the cassette placed horizontally on the x-ray table. The X-ray tube was centered so that the ray passed perpendicular to the film at the point midway between the nipple and the chest wall.

2) For Medio-lateral View: Patient was placed in the lateral recumbent position on the x-ray table, so that the breast to be examined was nearer the table top. The arm of the side under investigation was extended above the head, so that the axillary folds were not tense but just sufficient to keep the breast in its long axis parallel to the table. The position may ultimately be described as how a mother feeds a child lying down. This was very easily understood by the illiterate and lower class patients. The tube was centered perpendicular to the cassette so that the rays passed through a point midway between the nipple and the chest wall.

Apparatus Used

- X-ray machine: 300 Ma IG wipro make X-ray machine.
- Filter: Normally used 1 mm aluminium filter.
- X-ray films: Blue tinted double emulsion coated films screen type were used. Film size was 6"X 8".
- A plate to press the breast against the cassette.

KVp in cranio-caudal view was 32-36 and in medio-lateral view was 34-38; mAS was from 80-120 with FFD of 36. For proper exposure, immobilisation of patient was essential.

Processing of Mammographic Film

Standard processing chemicals were used to process the film in routine manner. Immediate basic evaluation was done in wet films and whenever necessary, repeat films were obtained.

Pathological study

The breasts removed during operation were sent for histopathological examination to find out basic pathology and the patients with breast lumps underwent FNAC. The axillary glands removed at the time of radical operation were sent to histopathological examination for any evidence of secondary deposits. The various histopathological types of breast tumours has been charted.

RESULT

Thirty cases having breast masses were included in present study which was conducted at L.L.R. & associated Hospitals and J.K. Cancer Institute, Kanpur. All cases were undergone Figure 1 shows maximum cases (56.67%) in study was suffering from carcinoma followed by 11 cases (36.67%) belonged to benign disease fibroadenoma. One case of inflammatory breast disease (3.33%) and one case of cystic breast disease (3.33%) was found in present study. These differentiations have been achieved in correlation

to their clinical presentation, mammographic findings, histopathological examinations and by the relative fact that they were subjected to surgery and radiotherapy.

Table 1 shows that the incidence of carcinoma of breast was found to be slightly more in post menopausal age group i.e. 9 out of 17 (52.9%).

The numbers of cases in relation to the duration of the symptoms under 1 year were 14 out of 17 (82.7%). The

| Age Group in Years | No. of Cases | Percentage |
|--------------------|--------------|------------|
| < 20 | 0 | 0.00 |
| 21-30 | 2 | 11.77 |
| 31-40 | 4 | 23.53 |
| 41-50 | 4 | 23.53 |
| 51-60 | 6 | 35.29 |
| >60 | 1 | 5.88 |
| Total | 17 | 100.00 |

Table-1: Age Wise Distribution of Carcinoma of Breast

| Duration of Symptoms | No. of Cases | Percentage |
|----------------------|--------------|------------|
| 0-6 Months | 12 | 70.5 |
| 7-12 Months | 2 | 11.8 |
| 13-18 Months | 0 | 0.00 |
| 19-24Months | 3 | 17.7 |
| 25-30Months | 0 | 0.00 |
| >30 Months | 0 | 0.00 |
| Total | 17 | 100.00 |

Table-2: Duration of Symptoms in Carcinoma of Breast

| Side of lesion | Site of lesion | No. of Cases |
|----------------|--------------------------------------|--------------|
| Right breast | Upper & outer quadrant | 4 |
| | Upper & inner quadrant | 1 |
| | Lower & inner quadrant | 0 |
| | Lower & outer quadrant | 0 |
| | Upper outer & inner | 1 |
| | Inner upper & lower | 1 |
| | Inner upper outer & subareolar | 1 |
| | Total | 8 |
| | Upper & outer quadrant | 3 |
| | Upper & inner quadrant | 2 |
| | Lower & inner quadrant | 0 |
| | Lower & outer quadrant | 1 |
| | Lower inner & outer quadrant | 1 |
| | Sub areolar & lower outer | 1 |
| | Upper inner subareolar & lower inner | 1 |
| | Total | 9 |

Table-3: Side & Site of lesion in Breast Carcinoma

| Parity | No. of Cases | Percentage |
|-----------|--------------|------------|
| No child | 0 | 0.00 |
| One child | 3 | 17.7 |
| child | 12 | 70.5 |
| >6 child | 2 | 11.8 |
| Total | 17 | 100.00 |

Table-4: Parity of Cases of Breast Cancer under Study

rest 3 cases belonged to 19-24 months duration as shown in table 2. Nearly all the cases in this group presented with a lump in one of the breasts, followed by pain which was invariably present in a number of cases. In one case an ulcer over the lump was also present. All the patients of breast cancer in this series were married and two of them were widows. An investigation into the menstrual history of 17 women of breast cancer showed that 8 were still having their menstruation regularly while 9 had gone into menopause. The average age of onset of menopause in this series was 44 years.

In 9 cases left breast was affected while in 8 cases it was the right breast. Retraction of nipple was noticed in 5 out of 17 cases. In 1 case, nipple was involved in the ulcer. In two cases, skin was fixed with the lump and in 1 case ulceration was present. In 4 cases peau de orange was present. In 4 cases no abnormality of skin was noticed. In 2 cases lump was fixed to the pectoral fascia or pectoral muscle. (Table 3)

Metastasis: In 12 cases various groups of lymph nodes were palpable in axilla. Bilateral axillary lymph nodes were involved in 2 cases. In 2 cases supraclavicular group of lymph nodes were also palpable besides the axillary group.

Mammographic findings: On basis of these findings, breast cancer cases can be divided in two groups:

1. Nodular presentation (10 cases).
2. Diffuse presentation (7 cases)

The size of tumour showed duration between 1x1 cm to 5x4 cm in the duration of 1 months to 1 year where as they were 2x1 cm to 6x7 cm in the duration above one year. The size of the tumour varied according to age group, it was more in pre-menopausal age group. The nodular presentation was observed in 10 cases, 9 of them were post menopausal age group while one was pre-menopausal whereas in the diffuse presentation 7 cases were found all belonging to pre-menopausal age group.

Another finding observed in this connection was that all the 7 cases of diffuse presentation belonged to group of shorter duration i.e. 1 month to 1.5 years. In the nodular presentation the most common radiographic finding observed in all the cases was the presence of the mass which was always found to be slightly but definitely smaller than the clinical measurement. The following are the characteristics of the mass observed:

1. **Density:** Definite increase in all cases.
2. **Situation:** In 7 cases lump was found in the upper and outer quadrant i.e. 41.2%. In 2 cases, it was found in sub-areolar region (11.8%).
3. **Shape:** In 7 cases lump was irregular (41.2%), round in 2 cases (11.8%) and poly lobulated in one case (5.8%).
4. **Contour:** Irregular in 7 cases (41.2%), partially smooth in 2 cases (11.8%) and partially irregular in one case (5.8%).
5. **Spiculation:** It was noticed in 4 cases (27.05%).
6. **Calcification:** It was noticed in 3 cases (17.7%).
7. **Capsulation:** None of the case showed any capsulation.

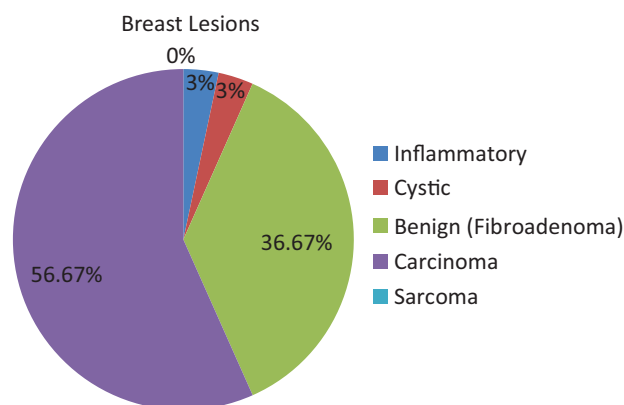


Figure-1: Distribution of Breast Lesions under study

Other mammographic findings observed were:

1. **Nipple:** Retracted in 5 cases (29.4%) and enlarged in 1 case (5.8%).
2. **Skin:** There was generalised thickening of skin more than 4 mm in most of cases. The subcutaneous reticulations were exaggerated in them. Skin vascularity was increased in all cases but not well seen, nor were they calcified.

Histopathological findings

Out of 17 cases of carcinoma of breast, four patients refused surgery. Their mammogram showed malignant changes. In 16 cases, FNAC examination was done after mammography. 15 cases showed positive FNAC results for malignancy and 1 was reported to have fibroadenosis with moderate dysplasia. Out of 13 cases operated, all the specimens were sent for histopathological examination. 8 cases had carcinoma of breast of anaplastic variety while 2 cases were of scirrhous type.

DISCUSSION

Malignant Breast Lesion: Out of the 17 cases of malignant breast lesions in the present study, all were carcinoma and n sarcoma. Taking the age factor into consideration one case safely conclude that more than 50% (52.9%) belonged to the post climacteric age group. Breast cancer is rare below 20 years group as reported by Edward. Similarly Hagensen observed a sharp decrease in the incidence of carcinoma of breast below this age. Findings of our study coincide with above mentioned study.

The higher incidence of carcinoma breast (52.9%) is compared to 65.5% of Jassawala and 75.5% of Taylor. In our series all the breast cancer cases were married and two were widows. Most investigators have reported a high incidence of breast cancer in single women; these findings do not coincide with ours. The explanation being that in India as a general middle and lower class families have usually early marriages.

70.5% of cases under our series came to hospital within 6 months since they noticed lump and discomfort in their breasts. This is in accordance with the findings of Sen and Dasgupta, however our findings do not tally with western investigations. Harnett found that 56% of patients of his

series had symptoms for 3 months. Illiteracy, ignorance, backwardness, poverty and want of medical assistance are probably the main reason of these delays.

Most of our cases had their left breast affected, the ratio being 9:8. This is in line with the findings of Lane Claypon, Jussawala and Lwison. In about 41.2% of cases, it was upper and outer quadrant. This finding is slightly higher to those of various other workers. A majority of breast tissues occur in upper and outer quadrant, it is more liable to malignant disease. According to the presentation in mammograms, carcinoma has been into two groups:

1. Nodular form (58.8%)
2. Diffuse form (41.2%)

It is interesting to note that majority of cases in nodular variety belonged to post climacteric age group. Diffuse presentation was observed in 7 cases of which all belonged to pre-climacteric age group. All the cases in diffuse group showed relatively shorter duration of symptoms in comparison to the nodular form. Apart from other features already discussed, following have been specially taken into consideration in differentiating the two mammographically.

1. **Characteristics of Mass:** The following table gives the comparative study of the 2 groups.

| S. No. | Feature | Nodular form (Group A) | Diffuse form (Group B) |
|--------|---------------|----------------------------------|-------------------------|
| 1 | Density | More | Less |
| 2 | Definition | More | Less |
| 3 | Situation | Mostly in upper & outer quadrant | Similar to nodular form |
| 4 | Shape | Irregular | Irregular |
| 5 | Contour | Less | Higher |
| 6 | Calcification | Present in 3 | Totally absent |
| 7 | Spiculation | Less | More |

In group A, increased vascularity with occasional calcification in the vicinity of the mass was also noted. The above mammographic description of the mass could be well appreciated in correlation with their respective clinical features. As the nodular form is common in older age with longer duration in comparison to diffuse group so their characteristics mammographic findings can be well realised.

2. **Nipple:** Incidence of retraction of nipple in group "A" has been found to be higher than in group "B".
3. **Skin:** Thickening of the skin was found to be well defined in group A (2 mm to 6 mm) which was generalised in 4 cases.
4. **Subcutaneous tissue:** The subcutaneous tissue was found to be increased and formed by exaggerated reticulation in all cases of group B only.
5. **Perifocal tissue of surrounding stroma:** Showed localised increased density, as separate fibrous strands in 70% cases of group 'A' while in the other group, there was generalised thickness.
6. **Vascularity:** It was increased in both the group but while it was well defined in the group 'A', it was not so in group B. In 20% cases of group A, calcification was

noted.

From the observations made regarding the relationship of the type of the tumour with the age of the patients, duration of the complaints and nature of pathology, one can conclude that size of the tumour mostly depends on the age of the patient and nature of the pathology and not much on the duration of the symptoms. Lower the age, higher is the anaplasticity, larger is the size of the growth independent of the duration of symptoms.

The significance of calcification as demonstrated by mammography has been well stressed by Leborgne R¹⁰, Gershon CJ¹¹ and studied by Shepherd JJ.¹² The incidence of its presence has been shown to be about 30-50% in malignant conditions. In comparison to this, present series resulted in about 17.6% (3 out of 17 cases). The reason for this lower incidence of calcification is two folds.

1. Calcification is more common in comedo-carcinoma or intraducta, as none of the cases considered in present study belonged to this group, reported by Leborgne R.¹⁰
2. The common medical film used in present series is not ideal for the demonstration of multiple, fine, punctuate salt like calcification (L. Stantan et al.).

The common sign of breast carcinoma seen on mammograph can be summarised as follows:

1. Visible opacity disrupting breast architecture.
2. Dense opacity with spiculation, nodulation, tentacles, mares tail.
3. Clinical size greater than radiological size.
4. Calcification in or near tumour,
5. Alteration in breast contour.

CONCLUSION

From the above observations, it can be concluded that mammographically the size of the tumour mainly depends on the age of the patient, nature of the pathology and partly on the duration of the disease. The lower the age, higher is the anaplasticity and larger is the size of the mass. Malignant breast lesions can be easily diagnosed by radiological examination. Therefore there is need for mammographic examination in all the cases coming with breast lump to evaluate the nature of the tumour mass. But it must be noted here that mammography being a highly skilled procedure requires the co-operation of surgeon, radiologist and the histopathologist.

REFERENCES

1. Parate R, Kasat V, Solanke R. Evaluation of Breast Masses using Mammography, Sonography and its Correlation. J Evolution Med.Dent.Sci.2018;7:2823-28.
2. World Health Organization (2006), Cancer. Fact Sheet (No. 297), Geneva. <http://www.who.int/mediacentre/factsheets/fs297/en/print.html>.
3. Gold RH. The evolution of mammography. Radiologic Clinics of North America 1992;30:1-19.
4. Khatun H, Tareak-AI-Nasir, Enam S, et al. Correlation of fine needle aspiration cytology and its histopathology in diagnosis of breast lumps. Bangladesh Medical Research Council Bulletin 2002;28:77-81.

5. Morris KT, Vetto JT, Petty JK, et al. A new score for the evaluation of palpable breast masses in women under age 40. *American Journal of Surgery* 2002; 184:346-7.
6. Berg WA, Gutierrez L, NessAiver MS, et al. Diagnostic accuracy of mammography, clinical examination, US and MR imaging in preoperative assessment of breast cancer. *Radiology* 2004;233:830-49.
7. Ciatto S, Cataliotti L, Distanti V. Nonpalpable lesions detected with mammography: review of 512 consecutive cases. *Radiology* 1987; 165: 99 - 102.
8. Kopans DB. Positive predictive value of mammography. *AJR* 1992; 158: 521 - 526.
9. Chakraborti KL, Bahl P, Sahoo M, Ganguly SK, Oberoi C. Magnetic Resonance Imaging of Breast Masses: Comparison with Mammography. *IJRI*.2005;15:381-7.
10. Leborgne RA. Breast in Roentgen diagnosis. *American Journal of Radiology*.1953;1:65.
11. Gershon CJ, Ingleby H. Mammography. *British Journal of Radiology*.1953;26:87.
12. Shepherd JJ et al. Soft-tissue Radiology of the Breast. *Radiology*.1962;78:967.

Source of Support: Nil; **Conflict of Interest:** None

Submitted: 18-08-2020; **Accepted:** 15-09-2020; **Published:** 31-10-2020