Computed Tomography Guided Fine Needle Aspiration Cytology of Clinically Suspected Lung Neoplasm: An Institutional Experience in Kumaun Region of Uttarakhand

Prabhat Pant[1], Vindhya Joshi[2], Kailash Chandra Pandey[3], Sanjeev Kumar Shukla[4], Dinesh Chandra Punera[5]

ABSTRACT

Intrduction: Lung carcinoma is the most common cause of cancer related mortality worldwide. Lung carcinoma is malignant lung neoplasm characterized by uncontrolled cell proliferation in lung tissue. Primary lung cancers are derived from epithelial cells. This present study was designed and conducted with an aim to evaluate demographics, imaging characteristics, staging of lung cancer by MDCT, cytopathological spectrum of lung cancers in Kumaun region of Uttarakhand and to assess the diagnostic accuracy of CT guided FNAC in evaluation of suspected lung masses.

Material and methods: This institution based prospective cross-sectional study was conducted at Government medical College and Swami Ram Cancer Hospital, Haldwani from 2018 to 2020 for two years. Computed tomography guided FNAC was done in 102 patients. After proper history and through clinical examination, patients were subjected to CT guided aspiration using aseptic precautions. Air-dried smears were stained with May–Grunwald–Giemsa stain (MGG). Alcohol fixed smears were stained using routine Papanicolaou (Pap) and Hematoxyline & Eosine (H & E) method.

Results: The study consisted of 102 patients in age group of 33-86 years. There were 81 males (79.41%) and 21 females (20.58%) and adequate sample was obtained in 94 patients giving adequacy rate of 92.15%. The most common cytological presentation was squamous cell carcinoma in 49 patients (52.12%) followed by adenocarcinoma in 23 patients (24.46%). Pneumothorax was seen in 8 patients (7.84%) of patients and no patient required chest tube insertion. In our study computed tomography (CT) guided FNAC was found successful in making the diagnosis in 91 cases (89.21%).

Conclusion: Computed tomography (CT) guided FNAC is a reliable, safe, less expensive, less time consuming, minimally invasive procedure with a high diagnostic accuracy for evaluation of suspected lung neoplasm.

Keyword: Computed Tomography, Fine Needle Aspiration Cytology, Clinically Suspected Lung Neoplasm.

INTRODUCTION

Cancer is a leading cause of death worldwide, accounting for an estimated 9.6 million deaths in 2018. The most common cancers are Lung (2.09 million cases), Breast (2.09 million cases) & Colorectal (1.80 million cases). The most common causes of cancer death are cancers of Lung (1.76 million deaths).[1] Tobacco use is the most important risk factor for cancer and is responsible for approximately 22% of cancer deaths.[2] Fine-needle aspiration cytology (FNAC) is a simple, relatively safe, rapid, reliable technique for the diagnosis of lung masses, particularly with the aid of Computed Tomography (CT) scan and Ultrasound Scan. FNAC not only distinguishes between benign and malignant lesions but also helps in tumour typing of lung cancer, so initiation of specific therapy like chemotherapy or surgery is possible without unnecessary delay.

FNAC was first used by Martin and Ellis as a diagnostic tool.[3] Leyden in 1883 and Menbriel in 1986 introduced the technique as diagnostic lung puncture for detection of malignancy and infections.[4] Numerous literatures supported that CT-guided FNAC is an accurate and sensitive way of diagnosing malignancy of the thorax.[5,6] Complications from image guided needle cytology are infrequent and generally minor, particularly when 22-gauge needles are used. Pneumothorax is the principal complication of CT-guided chest FNAC, may be decreased by minimizing the amount of aerated lung traversed.[7,8] It almost always is self-limited. Whenever possible, vessels, bronchi, and bullae should be avoided to minimize haemoptysis. The needle-track seeding is a rare occurrence with incidence of about 0.01%.[7]

The present study was aimed to evaluate the demographics, imaging characteristics, staging of lung cancer by MDCT, cytopathological spectrum of lung cancers in Kumaun region

[1]Assistant Professor, Department of Pathology, Government Medical College, Haldwani, Nainital, Uttarakhand, [2]Ex-Assistant Professor, Department of Radiodiagnosis and Imaging, Government Medical College, Haldwani, Nainital, Uttarakhand, [3]Associate Professor, Department of Radiotherapy, Government Medical College, Haldwani, Nainital, Uttarakhand, [4]Research Scientist-II, Multidisciplinary Research Unit, Government Medical College, Haldwani, Nainital, Uttarakhand, [5]Associate Professor, Department TB and Chest Disease, Government Medical College, Haldwani, Nainital, Uttarakhand, India[4]

Corresponding author: Dr. Prabhat Pant, Assistant Professor. Department of Pathology, Government Medical College, Haldwani, Nainital, Uttarakhand, India 263139

How to cite this article: Prabhat Pant, Vindhya Joshi, Kailash Chandra Pandey, Sanjeev Kumar Shukla, Dinesh Chandra Punera. Computed tomography guided fine needle aspiration cytology of clinically suspected lung neoplasm: An Institutional Experience in Kumaun Region of Uttarakhand. International Journal of Contemporary Medical Research 2020;7(6):F6-F11.

DOI: http://dx.doi.org/10.21276/ijcmr.2020.7.6.32

of Uttarakhand and to assess the accuracy of CT guided FNAC in evaluation of suspected lung masses.

MATERIAL AND METHODS

This prospective cross-sectional study was conducted in department of Pathology, Radio diagnosis & Radiation oncology, Government medical college & Swami Ram cancer hospital, Haldwani, during the period of 2018 - 2020 for two years. The study protocol was approved by the ethics committee of Govt. medical college, Haldwani. A total of 102 patients having clinically suspected lung cancers on X-ray chest & CT scan were referred from Department of Pulmonary medicine, Government medical college and Department of Radiation oncology, Swami Ram Cancer Hospital, Haldwani. The chest radiograph was taken in posterioanterior view and lateral view using Care stream DR (Digital radiography) machine. CT scan thorax was performed using Siemens Soma tom 16 slice MDCT machine & all images were acquired on 512 X512 pixel matrix. Heterogeneous contrast enhancement of lesion, size greater than 3.0 cm, irregular margins, spiculation, surface lobulation, corona radiate, presence of necrosis, cavitation, calcification, pleural / chest wall invasion, rib or vertebrae invasion, vascular invasion, presence of pleural effusion and hilar or mediastinal lymphadenopathy were considered signs of malignancy.

CT guided FNAC of pulmonary mass lesions from each case were performed by experienced cytopathologist & radiologist after explaining the risks and benefits. From each patient, informed consent was taken. The skin surface was cleaned with povidine iodine and then 21 G-88 mm long spinal needle was introduced through percutaneous or transthoracic approach localizing the exact position by CT scan after the measurement of the site and angle of entry of the needle, route of the needle, and the distance between the skin and lesion on the CT scan monitor. (9) Following placement of the needle, a CT scan slice was taken to ascertain whether the tip of the needle was within the mass. The aspirate was obtained by to and fro and rotating movements of the needle within the lesions and smears were prepared immediately from the sample. At least 8 smears were prepared for the record. Air-dried smears were stained with May gruwald Giemsa stain, whereas alcohol-fixed smears were stained with Papanicolaou (PAP) stain and Hematoxyline & eosine (H&E) stain for cytopathological evaluation. 94 cases with adequate cell yield were included in this prospective cross-sectional study as 08 cases showed inadequate cell yield in cytological examination.

Patients were kept for 6 hours under observation. In our study, 12 patients suffered with chest pain & pneumothorax occurred in 8 cases, which could be managed conservatively. We excluded those cases that were suffering from bleeding diathesis, pulmonary arterial hypertension (PAH), severe Chronic obstructive pulmonary disease (COPD) with bullae and contra lateral pneumonectomy cases and that were unable to hold breath. (9) After data collection, they were tabulated and analysis was done with use of MS Excel and Medcalc online software.

RESULT

Image guided (CT guided and Ultrasound guided) Lung interventions are routinely performed now a days. For the current study out of 102 patients underwent CT guided FNAC, 94 patients having adequate sampling material and were evaluated for clinico-radiological and cytopathological characteristics of lesions during the study period.

In the present study, patients were in the age group of 33 to 86 years of age. Youngest patients encountered was 33 years and oldest was 86 years. The median age of the study population of 61 years. Majority of patients were between 51 to 70 years of age. 32 patients (31.37%) of 51- 60 years and 41 patients (40.19%) of 61 - 70 years. 17 patients (16.66%) were more than 71 years of age.

Male patients were 81 (79.41%) and female patient were 21(20.58%). Male to female ratio was 3.85: 1.0.

In the present study, out of 102 cases 79 patients (77.45%) were chronic smokers while 23 (22.54%) were non-smokers. The ratio of smokers to non-smokers 3.43: 1. Among smokers out of 79 patients, 71 (89.87%) were male and 8 (10.12%) females. The ratio of male smokers to female smokers for 8.8: 1. Majority of male patients 71 patients (87.65%) were smokers. Patients were classified into two groups according to size of lesion. (< 2.0 cm vs ≥2.0 cm). Size of lesion in 29 patients were < 2.0. cm and in 73 patients size were >2.0 cm. Most common lesions were observed in right side in 53 cases (51.96%) followed by left side in 46 case (45.09%), however 03 cases (2.94%) showed bilateral involvement of lung (graph-1).

Most common presentation was cough with expectoration. Out of 102 patients 73 patients (71.56%) complained of cough with expectoration, 59 patients (57.84%) complained of unexplained weight loss with loss of appetite, 58 patients (56.86%) complained of dyspnoea, 49 patients (48.03%) complained of fever, 30 patients (29.41%) complained of chest pain, 19 patients (18.62%) complained of haemoptysis, 8 patients (7.84%) complained of hoarseness of voice, 2 patients (1.96%) complained of bone pain and 2 patients (1.96%) left hemi paresis (table-1).

Hilar or Mediastinal lymph node involvement was observed in the 77 patients (75.49%), Pleural and chest wall invasion

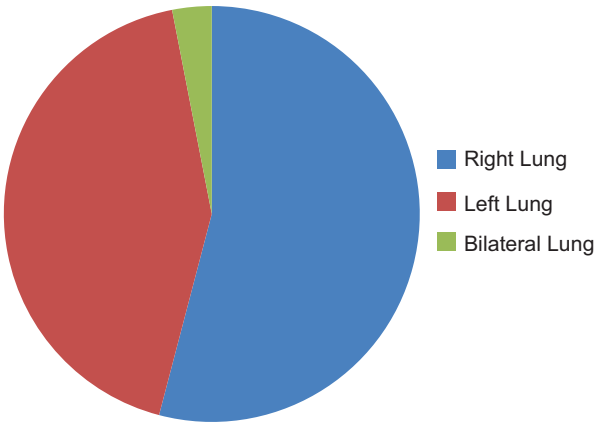

Graph-1: Lung involvement

was noted in 19 patients (18.62%), adjacent rib and vertebrae involvement was noted in 11 (10.78%), mediastinal invasion in 10 (9.80%) while superior vena cava syndrome seen in 4 cases (3.92%.) (table-3).

Distant visceral metastasis was observed in 33 cases (32.35%). Most common organ to be involved being liver 21 cases (20.58%), followed by adrenal in 11 cases (10.78%) and bone in 09 cases (8.82%) (table-4).

Computed tomography (CT) scan signs of malignancy

In the present study computed tomography could diagnose primary bronchogenic carcinoma in 92 cases (90.19%), out of 102 cases. CT was highly sensitive in diagnosing lung malignancies compared to Chest radiograph. P value is significant (P<0.05). Majority of lesions were greater than 3.0 cm and showing predominantly heterogeneous contrast enhancement in 78 cases (75.49%), irregular margins in 49 cases (48.03%), cavitation in 21 cases (20.58%) and spiculation in 47 cases (46.07%). Necrosis was noted in 39 cases (38.23%) and calcification was noted in 19 cases (18.62%). 37 patients (36.27%) presented with associated

Characteristic	No (%)
Age (mean + SD)	61.35 + 9.60
Sex	
Male	81 (79.41%)
Female	21 (20.58%)
Smoking history	
Non - smoker	23 (22.54%)
Smoker	79 (77.45%)
Lesion size, mm (mean + SD)	25 + 14 (8.8 - 95.3)
Lesion size	
< 2.0 cm	29
≥ 2.0 cm	73
Location	
Right Lung	53 (51.96%)
Right upper lobe	28 (27.45%)
Right middle lobe	6 (5.88%)
Right lower lobe	19 (18.62%)
Left Lung	46 (45.09%)
Left upper lobe	26 (25.49%)
Left lower lobe	20 (19.60%)
Bilateral Lung	3 (2.94%)
Provisional diagnosis by CT scan	
Malignant	92
Inflammatory / Benign	10
Cytological diagnosis	
Adequate samples	94
Malignant (Primary and secondary)	91
Benign / Inflammatory	02
Suspicious for malignancy	01

Table-1: Demographics and Lesion Characteristics (n =102).

Clinical Manifestations	No. of Patients	Percentage
Cough with expectoration	73	71.56%
Unexplained weight loss / loss of appetite	59	57.84%
Dyspnoea	58	56.86%
Pyrexia of unknown origin	49	48.03%
Chest Pain	30	29.41%
Haemoptysis	19	18.62%
Hoarsness of Voice	08	7.84%
Bone Pain	02	1.96%
Left Hemi paresis	02	1.96%

Table-2: Clinical Manifestations

Site	No. of Patients	Percentage
Hilar / Mediastinal Lymphadenopathy	77	75.49%
Pleural / Chest wall invasion	19	18.62%
Adjacent Rib / Vertebrae involvement	11	10.78%
Mediastinum invasion	10	9.80%
Superior Vena Cava syndrome	04	3.92%

Table-3: Local tumor Invasion

Site	No. of patients	Percentage
Liver	21	20.58%
Adrenal	11	10.78%
Bone	09	8.82%
Brain	04	3.92%
Contralateral Lung	01	0.98%

Table-4: Distant Metastasis

Cytological Types	No. of patients (n = 94)	Percentage
Squamous cell carcinoma (Including Keratinizing and Non-keratinizing)	49	52.12%
Adenocarcinoma (Including Bronchiolo-alveolar carcinoma)	23	24.46%
Small cell carcinoma	10	10.63%
Large cell carcinoma	02	2.12%
Undifferentiated / poorly differentiated carcinoma	05	5.31%
Secondary / Metastasis	02	2.12%
Granulomatous Pathology	01	1.06%
Lung Abscess	01	1.06%
Suspicious for Malignancy	01	1.06%

Table-5: Cytopathological diagnosis on FNAC

Figure-1: C. T. Scan shows heterogeneously enhancing mass with multiple areas of necrosis in lower lobe of left lung having a large area of contact with chest wall

collapse and consolidation whereas 42 patients (41.17%) presented with pleural effusion (Figure-1).

When the sample had a high cellularity, they were defined as adequate. Sample were considered inadequate when cellularity was poor due to blood stained material or necrosis as no definitive diagnosis could be given in these cases. These cases were considered as procedure failure and these cases were subjected to repeat aspirations or histopathological evaluation. These patients were excluded from the study. Adequate aspirate was obtained in total 94 patients. This constituted to about 92.15% of cases. There were 08 patients with inadequate aspirate. In the lesion size < 2.0 cm, the cell yield was comparatively low.

In this study primary neoplasm was much more common than secondary neoplasm. The most common cytological presentation was squamous cell carcinoma in 49 patients (52.12%) (Figure-2) followed by adenocarcinoma in 23 patients (24.46%), (Figure-3) small cell carcinoma in 10 patients (10.63%) (Figure-4), large cell carcinoma in 2 patients (2.12%) and undifferentiated / poorly differentiated group found in 5 patients (5.31%). 02 patients were diagnosed as metastatic neoplasm with known primary and primary was ductal carcinoma breast and chondrosarcoma of scapular bone (Figure-5). 01 patients was diagnosed as Granulomatous pathology and 01 patients was diagnosed as lung abscess. 01 patient was categorised as suspicious for malignancy due low cell yield with presence of atypical cells. We also found that the most common tumour among the males was squamous cell carcinoma whereas among the females adenocarcinoma was the commonest. The prevalence of all types of bronchogenic carcinoma were more common in the smokers. The most common tumour among the smokers was squamous cell carcinoma whereas the most common tumour among the non-smokers was a adenocarcinoma.

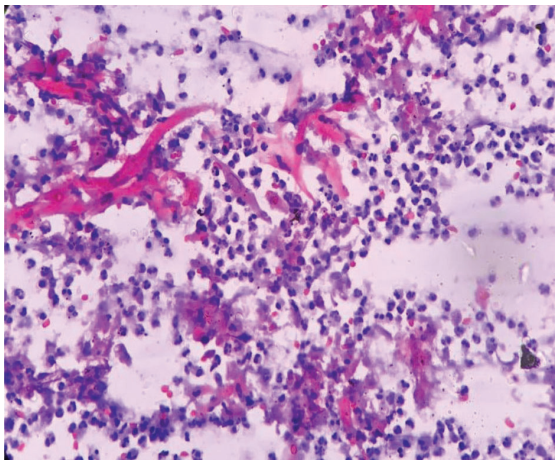

Figure-2: Keratinizing Squamous cell carcinoma Lung. Dispersed kertinizing malignant squamous cells, spindle cells and caudate cells against a background containing necrotic debris and neutrophils. (PAP)

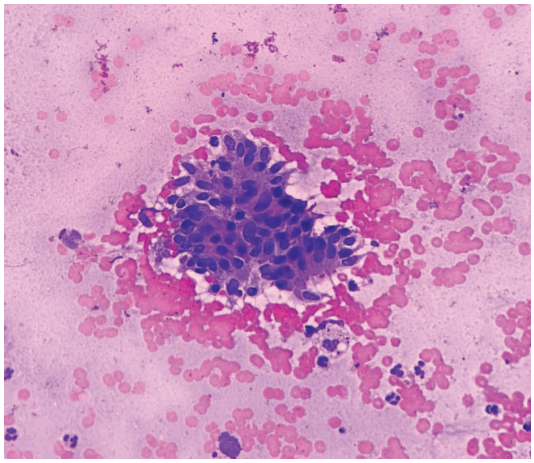

Figure-3: Adenocarcinoma 'Bronchogenic' : Group of palisaded columnar epithelial cells forming vague acinar pattern. (H&E)

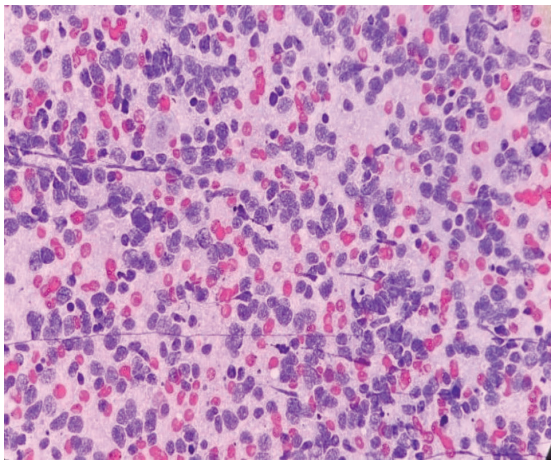

Figure-4: Small cell carcinoma Lung. Dispersed atypical small cells with scant or no cytoplasm and uniform coarse granular nuclear chromatin. (PAP)

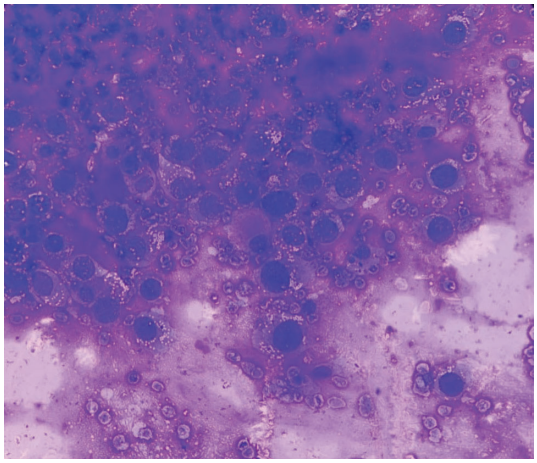

Figure-5: Metastatic deposit of chondrosarcoma. Clusters and tissue fragments of relatively bland cells with abundant vacuolated cytoplasm embedded in chondroid ground substance.(MGG)

DISCUSSION

A total of 102 cases having clinical and radiological suspicious on lung cancer were underwent multidetector computed tomography examination and fine needle aspiration cytology. Computed tomography could diagnose primary bronchogenic carcinoma in 92 cases (90.19%) while 10 cases diagnosed as inflammatory pathology. Adequate aspirate was

obtained in 94 patients giving the adequacy rate of 92.15%. On cytology 91 cases were diagnosis as bronchiogenic carcinoma, 02 case were inflammatory pathology or granulomatous etiology and 01 case as suspicious for malignancy. The sensitivity of computed tomography guided FNAC was found to be 95.60% and this correlation with computed tomography was found to be Moderate (r=0.565).

Most of the patients in our study belonged to the age group between 51-70 years with median age of 61 years, which is corresponding to other Indian studies.[8,10-13] As compared to western population median age of our patients was a decade younger. Most of the previous studies Indian have reported the similar median age. Behara et al 2004[14], Prabhat Singh Malik et al 2013[13] Prasad et al 2004.[11]

Majority of patients were males with male: female ratio 3.85: 1. Similar sex ratio was reported by R.Prasad et al 2004[11], Sumandram.V. et al 2014[12] and Prabhat Singh Malik et al 2013[13] also found a male to female ratio 4:1 in their studies. Smoking was found to be most important risk factor for the lung cancer in our study. 77.45% of patients were smokers. Similar observation was made by Thippanna et al[15] and Jindal et al.[16] The ratio of smokers to non-smokers was 3.43:1. Smoking was significantly more common among males. In our study the ratio of male to female among smokers was 8.8:1.

Cough with expectoration with the most common complaint found in 73 patients (71.56%) of cases followed by unexplained weight loss with loss of appetite in 59 patients (57.84%), dyspnoea in 58 patients (56.86%), fever in 49 (48.03%), chest pain in 30 (29.41%), haemoptysis in 19 (18.62%) and hoarseness of voice in 8 patients (7.84%). Similar observation was reported by Jagdish Rawat et al[8] and Manoj Kumar Agarwal et al.[17]

Comparison of this current study with other studies showed similar smear adequacy, diagnostic accuracy, sensitivity, specifity and complications as given in the table-6. There were 102 patients and adequate aspirate was obtained in 94 patients giving adequacy rate of 92.15%. Sensitivity was 95.60%, specifity was 100%, positive predictive value was 100% and negative predictive value was 33.33%. Size and depth of the lesion affects adequacy of the smears. It was comparable with other studies.

Various complications can occur during the aspiration like chest pain, pneumothorax, intrapulmonary haemorrhage, haemoptysis, pulmonary embolism and rarely needle track implantation.[7,18-23] We encountered most common complication as chest pain followed by pneumothorax in 8 cases (7.84%).

Adenocarcinoma is now the most common subtype of lung carcinoma worldwide, accounting for 40% or more of all primary carcinomas.[24] In present study the most common cytological presentation was squamous cell carcinoma in 49 patients (52.12%) followed by adenocarcinoma in 23 patients (24.46%), small cell carcinoma in 10 patients (10.63%), large cell carcinoma in 2 patients (2.12%), undifferentiated / poorly differentiated carcinoma in 5 patients (5.31%) and 02 patients were diagnosed as metastatic neoplasm. These findings are similar to studies from other part of India.[8,11,14,16] Squamous cell carcinoma, adenocarcinoma and small cell carcinoma can be effectively diagnosed by cytology.

In the present study majority of patients were diagnosed at a later stage of disease. The majority (72.61%) of non-small cell carcinoma (squamous cell carcinoma, adenocarcinoma, large cell carcinoma and undifferentiated / poorly differentiated carcinoma) patient had advanced stage disease stage (IIIB and IV) and 70% of small cell carcinoma patient had extensive stage disease at the time of diagnosis (IIIA,IIIB and IV). Similar observation were reported by R Prasad et al(11), Prabhat singh Malik et al(13) and Jindal and Behara et al (14). In our study computed tomography (CT) guided FNAC was found successful in making the diagnosis in 91 cases (89.21%). The sensitivity of computed tomography guided FNAC was found to be 95.60% and this correlation with computed tomography was found to be Moderate (r =0.565). In our study CT guided FNAC was found highly sensitive and specific in diagnosing bronchogenic carcinoma. It can sub classify the type of bronchogenic carcinoma. Hence CT guided FNAC diagnosis alone can be used with confidence to select treatment modality and to avoid unnecessary surgery in patient with lung malignancies.

Limitation

As non-contrast computed tomography was performed during the FNAC procedure it was sometime difficult to localize cellular / solid area in suspected lung masses with necrosis and haemorrhage thereby multiple repeat aspiration attempts. Cell yield may be low for lesions lesser than 2.0 cm in size so it can limit the diagnostic accuracy. In present study paediatric patients were excluded hence efficacy in paediatric patients could not be assessed. Although needle core biopsy and histopathology is gold standard test for evaluation of

Name of Author	Current study	Singh JP et al. [18]	Gupta A et al. [19]	Gadodiya et al. [23]	Adyakinkar et al. [21]	Mukherjee S et al. [20]	Emara MM et al. [22]
No. of cases	102	34	66	81	60	94	66
Age	35-86	35-75	9-82	3-80	10-80	40-70	9-82
Adequacy	92.15%	85.3%	90%	85.55%	90%	95%	90%
Sensitivity	95.60%	92%	85.7%	92.31%	90	97%	-
Specificity	100%	100%	68.9%	100%	85.7	100%	-
Positive predictive value	100%	100%	66.6%	-	-	100%	-
Negative predictive value	33.33%	75%	89.96%	-	-	66.6%	-
Pneumothorax	7.84%	11.8%	20%	3.33%	9.8%	4.3%	21%

Table-6: Comparison of current study with previous studies.

lung neoplasm but this is sometime difficult in government hospitals in remote areas due to limited resources.

CONCLUSION

Computed tomography (CT) guided FNAC is a reliable, safe, minimally invasive procedure with a high diagnostic accuracy for evaluation of suspected lung neoplasm and enables sub typing of bronchogenic carcinoma in the vast majority of cases. The differentiation of suspicious neoplasm in early stage of evaluation helps to categorize them in their proper subtype and avoid unnecessary treatment procedure. The pitfalls in the cytology diagnosis can be prevented by proper clinical and radiological correlations. Most common complication being pneumothorax which can be treated easily.

ACKNOWLEDGMENT

I acknowledge the support of faculty members of department of Radiodiagnosis and Imaging, Tuberculosis and Chest Disease and Radiotherapy, Swami Ram cancer Hospital, Haldwani. I am thankful to technical staff for given patient's information and samples. I am also thankful to Principal, Government Medical College, Haldwani, Nainital, Uttarakhand.

REFERENCES:

1. Ferlay J, Soerjomataram I, Ervik M, Dikshit R, Eser S, Mathers C et al. GLOBOCAN 2012 v1.0, Cancer Incidence and Mortality Worldwide: IARC Cancer Base No. 11. Lyon, France: International Agency for Research on Cancer; 2018.
2. GBD 2015 Risk Factors Collaborators. Global, regional, and national comparative risk assessment of 79 behavioural, environmental and occupational, and metabolic risks or clusters of risks, 1990-2015: a systematic analysis for the Global Burden of Disease Study 2015. Lancet. 2016; 388:1659-1724.
3. Martin HE, Ellis EB. Biopsy by needle puncture and aspiration. Ann Surg 1930;92:169-81.
4. Shah S, Shukla K, Patel P. Role of needle aspiration cytology in diagnosis of lung tumors. A study of 100 cases. Indian J PatholMicrobiol 2007;50:56-8.
5. Mullan CP, Kelly BE, Ellis PK, Hughes S, Anderson N, Mc Cluggage WG. CT-guided fine-needle aspiration of lung nodules: Effect on outcome of using coaxial technique and immediate cytological evaluation. Ulster Med J 2004;73:32-6.
6. Cox JE, Chiles C, McManus CM, Aquino SL, Choplin RH. Transthoracic needle aspiration biopsy: Variables that affect risk of pneumothorax. Radiology 1999;212:165-8.
7. Gupta A, Mrigpuri P. Assessment of clinico-radiological correlation with CT guided FNAC of different lung lesions: a hospital based study. International J Contemp Med Res. 2017;4:1290-93.
8. Rawat.J.,Sindhwani G., Gaur D., Dua R., Saini S.,.Clinico-pathological profile of lung cancer in uttarakhand. Lung India 2009;26;74-76.
9. Hayes M.M., Zhang D.Y., Brown W. Transthoracic fine-needle aspiration biopsy cytology of pulmonary neoplasms. Diagn Cytopathol1994;10:315-9.
10. Shetty C.M. Kakhkhar B.N. Gangadhar VS.S. Ramchandran N.R. Changing pattern of bronchiogeniccarcinoma, A statistical variation or reality. Indian journal radiology imaging 2005;15: 233-238.
11. Prasad R. Prince James, Kesarwani V. Gupta R. Pant M.C. Chaturvedi A. Srivastav A.N. Clinicopathological study of broncogeniccarcinoma. Respirology. 2004;9: 557-560.
12. Sundaram V Sanyal N. Clinicopathological profile of bronchogenic carcinoma in tertiary care centre in eastern part of india. Clinical cancer investigation Journal. 2014; 3: 220-224.
13. Malik S. Prabhat. Sharma M.C. Mohanti B.K. Shukla N.K. Deo. S.V.S. Anant Mohan. Kumar Guresh. Raina V. Clinicopathological profile of lung cancer at AIIMS:A changing paradigm in india. Asian pacific journal of cancer prevention 2013. Vol 14.
14. Jindal SK. Behara.D. Clinical spectrum of primary lung cancer. Review of chandigarh experience of 10 years. Lung India 1990. 8; 94-98.
15. Thippanna G, VenuK, Gopikrishna V, Reddy PNS. Sai cheiran BG. A profile of lung cancer in Hyderabad. JIMA.1990: 97;357-359.
16. Jindal SK. Malik SK, alik AK, SinghK, Gujral JS, Sodhi JS. Bronchogenic carcinoma. A review of 150 cases. Indian Journal of chest disease. 1979;21:59-64.
17. Agarwal MK. Kumar A, Khurana A, Akbar N. Clinico pathological profile of Lung cancer at a tertiary care centre, Bareilly. Journal of evolution of medical and dental sciences. 2014;3:14318-14322.
18. Singh JP, Garg L, Setia V. Computed Tomography (CT) guided [5] transthoracic needle aspiration cytology in difficult thoracic mass lesions-not approachable by USG. Ind. J. Radio. Imaging. 2004;14:4:395-400.
19. Gupta A, Mrigpuri P. Assessment of clinico-radiological correlation with CT guided FNAC of different lung lesions: a hospital-based study. International J Contemp Med Res. 2017;4:1290-93.
20. Mukherjee S, Bandyopadhyay G, Bhattacharya A, Ghosh R, Barui G, Karmakar R. Computed tomography-guided fine needle aspiration cytology of solitary pulmonary nodules suspected to be bronchogenic carcinoma: Experience of a general hospital. JCytol. 2010;27:8-11.
21. Panda AK, Pradhan S, Mohapaapatra SS, Biswal R, Nisha S. Correlation of CT Findings of Thoracic Mass Lesions with CT Guided Aspiration Cytology. National Journal of Laboratory Medicine. 2017;6:1.
22. Emara M.M, El- Badrawy A, Elshazly T.A, Abdalla M.E, Yamany H.A. et al. Role of transthoracic CT guided needle aspiration cytology in difficult to diagnose benign and malignant intrathoracic lesions. Egyp J Bronchol. 2013;7:4-13.
23. Gadodiya K, Patil R.N., Kumbhalkar D., Raut W.K. Computed tomography guided FNAC of lung and mediastinal lesions. International journal of contemporary medical research. 2019. Vol.6. Issue 2.
24. Jon.H.Ritter, Hannah.R.Krigman. Section II. Thorax. Chapter: Lung. The Washington manual of surgical pathology. 2nd ed. 2012. Lippincott Williams& Wilkins.

Source of Support: Nil; **Conflict of Interest:** None

Submitted: 04-05-2020; **Accepted:** 06-06-2020; **Published:** 25-06-2020