

# Dermatophytosis: an Epidemiological And Clinical Comparative Study in a Tertiary Care Centre

Sheikh Javeed Sultan<sup>1</sup>, Aaqib Aslam Shah<sup>2</sup>, Ilham Iqbal<sup>3</sup>, Faizan Younus<sup>4</sup>, Iffat Hassan Shah<sup>5</sup>

## ABSTRACT

**Introduction:** Dermatophytosis is a common superficial mycosis associated with significant morbidity. Dermatophytosis which are recurrent and clinically unresponsive to therapy are showing an alarming increase in the last few years. These patients are a potential source of infection to their family members and others closely associated with them. Our study aimed to investigate the risk factors, clinical patterns and causative dermatophyte species in patients with chronic/recurrent dermatophytosis and patients with first episode of typical tinea.

**Material And Methods:** The enrolled patients were categorized as group I consisting of 81 cases of chronic/recurrent dermatophytosis and group II consisting of 81 cases of first episode dermatophytosis. After detailed history and thorough clinical examination, wet-mount preparation for direct microscopic examination was done along with fungal culture using Sabouraud's dextrose agar.

**Results:** In group I, *T. mentagrophytes* (51.7%) was the most common species isolated followed by *T. tonsurans* (26.7%) and *T. rubrum* (18.3%) while in group II, *T. tonsurans* (43.3%) was the most common species isolated followed by *T. rubrum* (28.4%) and *T. mentagrophytes* (23.9%). Injudicious use of topical steroids, non-compliance with treatment and presence of dermatophyte infection among family members were the major risk factors with significant association with chronic/recurrent infections. Limitations: Lack of follow up of cases, antifungal susceptibility with clinical outcome and Immunological profile of the patients was not studied.

**Conclusion:** Chronic and recurrent dermatophytosis are emerging as a major problem in dermatology practice. Injudicious use of topical steroid containing preparations, non-compliance, presence of intrafamilial infection are major factors for chronic and recurrent infections.

**Keywords:** Tinea, Dermatophyte, Dermatophytosis, Trichophyton

topical corticosteroid-based combinations, the increasing usage of broad spectrum antibiotics, the increasing burden of immune-compromised population, the widespread use of antifungals in the agricultural industry, and antifungal drug resistance, have been proposed for this changing trend of dermatophytosis, the exact reasons remain to be elucidated.<sup>1,8</sup> Our study was designed to assess the risk factors, clinical patterns and causative species in patients with chronic/recurrent dermatophytosis in comparison to patients of first episode dermatophytosis.

## MATERIAL AND METHODS

The study was conducted in the Department of Dermatology, Government Medical College, Srinagar, over a period of 1 year after approval from the Institutional ethical committee. All patients with dermatophytosis attending the OPD from April 2019 to March 2020 were screened and out of these patients with chronic/recurrent dermatophytosis were enrolled in our study (Group I). An equal number of new/fresh cases of dermatophytosis were included for comparison (Group II). An informed consent was obtained from all the enrolled patients. For the purpose of our study, chronic dermatophytosis was diagnosed in patients who continued to have disease for 6 months to 1 year with or without recurrence in spite of being treated while recurrent dermatophytosis was diagnosed in patients who had at least one episode of relapse of dermatophytosis within 4 weeks of stopping antifungal drugs in the preceding 6 months.<sup>1,5,9</sup> Patients with only tinea capitis and tinea unguium were excluded.

A detailed history was taken from each patient regarding the duration, treatment taken, topical corticosteroid application, treatment compliance, affected family members, type of clothing, sharing of cloths, towels, soaps and footwear, bath habits, frequency of changing cloths, contact with pets/cattle, intake of any immunosuppressants, history of any other cutaneous or systemic disease. Thorough clinical

## INTRODUCTION

Dermatophytes are pathogenic fungi responsible for causing superficial mycosis known as dermatophytoses. Dermatophytoses are among the commonest diseases encountered by dermatologists and due to the growing prevalence have become a worldwide public health issue.<sup>1-3</sup> Recently there has been an alarmingly increasing trend of dermatophytosis towards treatment unresponsiveness, multiple site lesions, recurrent disease and chronicity.<sup>4-6</sup> What was once an easily treatable condition has become difficult to manage and a cause of significant morbidity and impaired quality of life.<sup>1,7</sup> Although multiple factors, including use of

<sup>1</sup>Lecturer, Department of Dermatology, <sup>2</sup>PG Student, Department of Dermatology, <sup>3</sup>PG student, Department of Microbiology, <sup>4</sup>Senior Resident, Department of Dermatology, <sup>5</sup>Professor, Department of Dermatology, Government Medical College, Srinagar

**Corresponding author:** Dr Sheikh Javeed Sultan, Shalimar – Srinagar, Jammu & Kashmir 191121

**How to cite this article:** Sheikh Javeed Sultan, Aaqib Aslam Shah, Ilham Iqbal, Faizan Younus, Iffat Hassan Shah. Dermatophytosis: an epidemiological and clinical comparative study in a tertiary care centre. International Journal of Contemporary Medical Research 2020;7(6):F1-F5.

**DOI:** <http://dx.doi.org/10.21276/ijcmr.2020.7.6.21>



examination was done in all cases with special attention to the sites involved, body surface area involved (calculated in terms of hand units, 1 hand unit = 1% BSA) and morphology of lesions.

### Sample for mycological study

After cleaning the affected area with 70% alcohol, samples were collected by scraping the lesion from the center to the edge with a sterile scalpel blade. Wet-mount preparation of the samples were performed using 10% potassium hydroxide for direct microscopic examination. Specimens were also cultured on Sabouraud's dextrose agar and incubated for up to 4 weeks. Confirmation of the species was done using Lacto phenol cotton blue (LCBP) mount.

## RESULTS

Out of the 730 patients with dermatophytosis screened, 81 patients met the criteria for chronic/recurrent dermatophytosis (11.09%) and were included in group I. For comparison, an equal number of new/fresh cases were included in group II. Group I comprised of 56 (69.1%) males and 25 (30.9%) females with the age of the patients ranging from 18 to 62 years. Group II consisted of 53 (65.4%) males and 28 (34.6%) females with ages ranging from 13 to 65 years. In both the groups majority of the patients belonged to the 21 to 40 year age range (60% in both). The mean age of patients in Group I was  $35.9 \pm 13.1$  years while in Group II it was  $34.9 \pm 11.5$  years. No statistically significant difference was seen between the mean ages of the two groups ( $t=0.5163$ ,  $p=0.6064$ ).

Multiple site involvement (mixed type infection) (36, 44.4%) was the commonest pattern in group I (Figure 1) while Tinea cruris (33.4%) was the most common pattern seen in group II (Table 1). Inflammatory lesions were seen in 56 (69.1%) patients of group I and 48 (59.3%) patients of group II. Classical annular lesions were seen in 70 (86.4%) patients of group I and 75 (92.6%) patients of group II (Table 2). In both the groups, other types of lesions were also seen (Table 2). Among the various risk factors assessed (Table 3), the most common was presence of dermatophytosis among family members in group I and wearing of tight cloths (e.g jeans pants) in group II. Of the various risk factors, family history and sharing of towels were the only two risk factors that showed a statistically significant ( $p<0.05$ ) association with chronic and recurrent dermatophytosis (Table 3).

Family members affected with dermatophytosis were identified in 39 (48.2%) patients of group I in comparison to only 17 (17.3%) patients in group II. In both groups spouse was found to be the most frequently affected family member (67% in group I and 47% in group II). Sharing of towels among family members was admitted by 35 (43.2%) patients of group I in comparison to 17 (21%) patients in group II.

In group I, use of topical corticosteroids either alone or in combination with antifungals was reported by 37 (45.7%) patients. Majority of the patients (74, 91.4%) in this group had received systemic antifungals (Fluconazole, Terbinafine, Itraconazole or Griseofulvin) previously for durations ranging from 2 weeks to 3 months. While, 49 (66.2%) of

Clinical type	Group I	Group II
Tinea corporis	21 (25.9%)	22 (27.2%)
Tinea cruris	18 (22.2%)	27 (33.3%)
Tinea faciei/barbae	3 (3.7%)	6 (7.4%)
Tinea pedis	3 (3.7%)	11 (13.6%)
Mixed	36 (44.5%)	15 (18.5%)

**Table-1:** Clinical patterns

Type of lesion	Group I	Group II
Classical annular	70 (86.4%)	75 (92.6%)
Papulosquamous	3 (3.7%)	2 (2.5%)
Eczematous	3 (3.7%)	1 (1.2%)
Concentric/pseudoimbricate	2 (2.5%)	1 (1.2%)
Lichenoid	2 (2.5%)	1 (1.2%)
Bullous	1 (1.2%)	1 (1.2%)

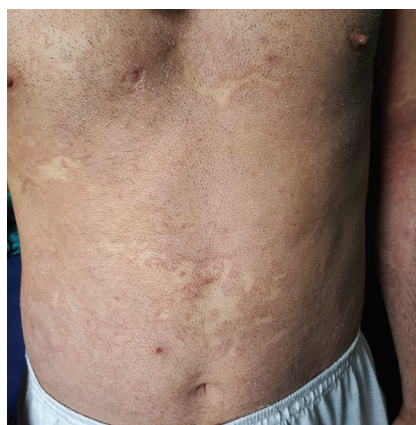**Table-2:** Morphology of lesions

Risk factor	Group I	Group II	P value
Family history	39 (48.2%)	14 (17.3%)	<0.05
Infrequent bath	9 (11.2%)	6 (7.4%)	>0.05
Tight clothing	26 (32.1%)	29 (35.8%)	>0.05
Sharing cloths	10 (12.4%)	7 (9.9%)	>0.05
Sharing towels	35 (43.2%)	17 (21%)	<0.05
Sharing footwear	16 (19.8%)	14 (17.3%)	>0.05
Contact with pets/cattle	11 (13.6%)	10 (12.4%)	>0.05
Atopy	9 (11.2%)	6 (7.4%)	>0.05
Diabetic	5 (6.2%)	6 (7.4%)	>0.05
Immunosuppressants	3 (3.7%)	2 (2.5%)	>0.05

**Table-3:** Risk factors

Species	Group I	Group II
Trichophyton Mentagrophytes	31 (51.7%)	16 (23.9%)
Trichophyton Tonsurans	16 (26.7%)	29 (43.3%)
Trichophyton Rubrum	11 (18.3%)	19 (28.4%)
Trichophyton Concentricum	1 (1.7%)	1 (1.5%)
Epidermophyton spp	1 (1.7%)	2 (2.9%)
No growth	21 (25.9%)	14 (17.3%)

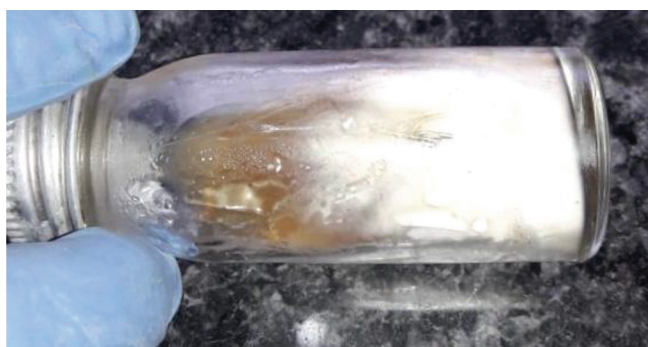**Table-4:** Culture reports



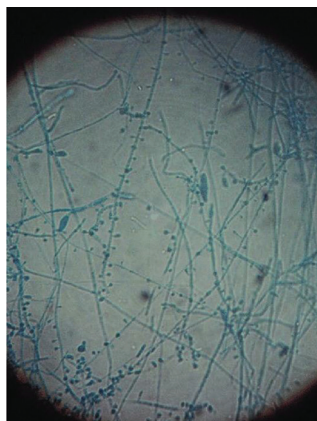**Figure-1:** Extensive dermatophyte infection

these patients had completed the full course of systemic antifungals, 25 (33.8%) patients reported stopping treatment





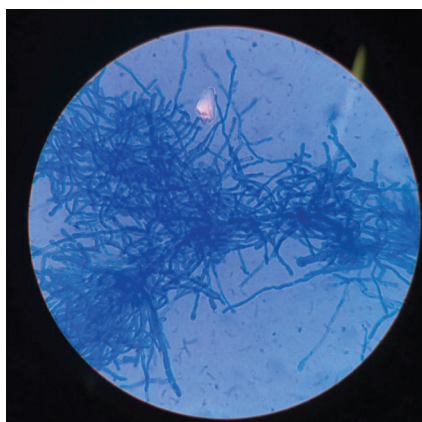
**Figure-2:** White powdery colony on SDA (T Mentagrophytes)



**Figure-3:** LPCB mount showing grape like microconidia and cigar shaped macroconidia with rat tail ends (T Mentagrophytes)



**Figure-4:** White powdery colony with radial rugae on SDA (T tonsurans)



**Figure-5:** LPCB mount showing club like microconidia (T tonsurans)

immediately after clearance of lesions.

Direct microscopic examination of wet-mount specimens

was positive for septate hyphae in 54 (66.7%) patients of group I and 61 (75.3%) patients of group II. Growth of dermatophytes in SDA cultures was seen in samples from 60 (74.1%) patients of group I and 67 (82.7%) patients of group II (Table 4). In group I, *T.mentagrophytes* (51.7%) (Figure 2 & 3) was the most common species isolated followed by *T tonsurans* (26.7%) and *T rubrum* (18.3%). In group II, *T tonsurans*(43.3%) (Figure 4 & 5) was the most common species isolated followed by *T rubrum* (28.4%)and *T mentagrophytes*(23.9%).

## DISCUSSION

Chronic/recurrent dermatophyte infections are increasing more than ever before emerging as one the tough to treat dermatological modalities in current times emerging as a challenge to dermatologists all over the world with India being no exception to it.<sup>8,10</sup> In the present study among the patients of dermatophytosis screened, 11.09% were labeled as chronic/recurrent Dermatophytosis similar to the findings by Pathania S et al.<sup>11</sup> Male preponderance was seen in our study as has been reported by different studies in the past.<sup>11,12</sup> More outdoor activities in males could be a reason for this predominance.<sup>1</sup> Most of cases chronic/recurrent cases in present study were affected in their fourth decade of life similar to the reports of Sivaprakasam et al.<sup>13</sup> Waning immunity and other co morbidities could be a factor for the occurrence of chronic dermatophytosis commonly in late middle age.<sup>1</sup> Statistical significance among risk factors for chronic/recurrent dermatophyte infection could be seen with positive family history(48.2%) and sharing of towels(43.2%). This was in concordance with study by Gosh et al where positive family history was found in 48%.<sup>14</sup> The use of topic steroids alone or in combination with antifungals was found to be present 45.7%. Use of such medications have been seen more frequently in previous studies like Mahajan et al (70%) and application of these readily available steroids or combination drugs of steroids with antifungals and antibiotics has been attributed as an important factor for chronic and recurrent dermatophyte infections.<sup>15</sup> Activation of cell mediated immunity plays an important role in combating dermatophytosis of skin while the use of steroids is believed to suppress this immune response.<sup>16</sup> An overwhelming population of the chronic/recurrent dermatophytosis group of the present study had received systemic antifungal treatment previously(91.4%). Compliance to treatment and completion of full course of systemic anti fungals could be seen in 66.2% cases. Antifungal resistance which has been defined as the persistence or progression of infection despite appropriate antimicrobial therapy along with environmental factors could be the reason for chronicity and recurrence of such cases where despite receiving complete systemic antifungal treatment infection still persisted or recurred.<sup>17</sup> Thus for a clinical response to be successful to antifungals apart from the susceptibility of the pathogenic organism, it is host immune system along with drug penetration and its distribution with absence of a protected or persistent focus of infection which is important.<sup>18</sup> In the present study 66.7%

cases among chronic/recurrent infections were positive for septate hyphae on direct microscopic examination of wet mount similar to many other reports of the past however lower than Pathania et al who found 98.7% positivity in their study.<sup>11,19</sup> Higher culture positivity on SDA could be seen in the present study in both fresh (82.7%) and chronic/recurrent cases (74.1%) compared to many previous similar reports.<sup>11,19,20</sup> However Comparative less isolation among chronic/recurrent cases could be attributed to previous antifungal and topical steroid application causing deeper penetration.<sup>1</sup> Lacto phenol cotton blue (LCBP) mount was used in the present study for confirmation of the species after culture positivity was acquired similar to the report by Sahai et al.<sup>21</sup> *T. mentagrophytes* was the most commonly isolated organism (51.7%) among chronic/recurrent cases in the present study. This finding coincides with many other reports<sup>11,19,22</sup> whereas there have been reports of *T. rubrum* being the most common species isolated in cases of *Tenia corporis* and *cruris*.<sup>1,23</sup> *T. tonsurans* was the most common species (43.3%) found in fresh cases in our study. There have been minimal reports of *T. tonsurans* being the most common species isolated in other reports however the present study lays the emphasis on the growing diversity in the spectrum of dermatophytes isolated from superficial mycoses cases and thus the means to tackle the disease also need to diversify. Sahai et al found 20% of their cases isolated on culture as *T. tonsurans*.<sup>21</sup> *T. rubrum* being the next common species isolated in both groups along with *T. concentricum*, *Epidermophyton* species were also found in the present study similar to the finding by Mahajan et al and Sahai et al.<sup>15,21</sup> Multiple site involvement (Mixed type infection) was the most common pattern seen among chronic/recurrent cases in the present study similar to the findings of Mahajan et al.<sup>15</sup> Classical annular morphological pattern was the most common type seen in both groups in the present study similar to the findings of other reports.<sup>11</sup> However an increased incidence of atypical presentation of lesions of *Tenia* like erythema, eczematous lesions, pseudoimbricate, and pustular lesions could be seen in chronic/recurrent cases specifically secondary to the usage of topical steroids in the past compared to fresh cases similar to the reports of Verma S et al.<sup>24</sup>

## CONCLUSION

Chronic and recurrent dermatophytosis are emerging as a major problem in dermatology practice. Injudicious use of topical steroid containing preparations, non-compliance, presence of intrafamilial infection are major factors for chronic and recurrent infections. Isolation of *T. mentagrophytes* may be a pointer towards chronicity and recurrences.

## REFERENCES

- Vineetha M, Sheeja S, Celine MI, Sadeep MS, Palackal S, Shanmole PE, et al. Profile of dermatophytosis in a tertiary care center. *Indian J Dermatol* 2018;63:490-5.
- Gnat, S., Łagowski, D. and Nowakiewicz, A. (2020), Major challenges and perspectives in the diagnostics and treatment of dermatophyte infections. *J Appl Microbiol*. doi:10.1111/jam.14611
- Köhler J, Hube B, Puccia R, Casadevall A, Perfect J. Fungi that Infect Humans. *Microbiol Spectrum* 2017;5:FUNK-0014-2016.
- Narasimhalu CR, Kalyani M, Somendar S. A cross-sectional, clinico-mycological research study of prevalence, aetiology, speciation and sensitivity of superficial fungal infection in Indian patients. *J Clin Exp Dermatol Res* 2016;7:324.
- Panda S, Verma S. The menace of dermatophytosis in India: The evidence that we need. *Indian J Dermatol Venereol Leprol* 2017;83:281-4.
- Pathania S, Rudramurthy SM, Narang T, Saikia UN, Dogra S. A prospective study of the epidemiological and clinical patterns of recurrent dermatophytosis at a tertiary care hospital in India. *Indian J Dermatol Venereol Leprol* 2018;84:678-84.
- Degreef H. Clinical forms of dermatophytosis (ringworm infection). *Mycopathologia* 2008;166:257-65.
- Dogra S, Uprety S. The menace of chronic and recurrent dermatophytosis in India: Is the problem deeper than we perceive? *Indian Dermatol Online J* 2016;7:73-6.
- Sahoo AK, Mahajan R. Management of tinea corporis, tinea cruris, and tinea pedis: A comprehensive review. *Indian Dermatol Online J* 2016;7:77-86.
- Verma S, Madhu R. The great Indian epidemic of superficial dermatophytosis: An appraisal. *Indian J Dermatol* 2017;62:227-36.
- Pathania S, Rudramurthy SM, Narang T, Saikia UN, Dogra S. A prospective study of the epidemiological and clinical patterns of recurrent dermatophytosis at a tertiary care hospital in India. *Indian J Dermatol Venereol Leprol* 2018;84:678-84.
- Sharma R, Adhikari L, Sharma RL. Recurrent dermatophytosis: A rising problem in Sikkim, a Himalayan state of India. *Indian J Pathol Microbiol* 2017;60:541-5.
- Sivaprakasam K, Govindan B. A clinico-mycological study of chronic dermatophytosis of more than years duration. *Int J Sci Res* 2016;5:551-4.
- Ghosh RR, Ray R, Ghosh TK, Ghosh AP. Clinico-mycological profile of dermatophytosis in a tertiary care hospital in West Bengal, an Indian scenario. *Int J Curr Microbiol Appl Sci* 2014;3:655-66.
- Mahajan S, Tilak R, Kaushal SK, Mishra RN, Pandey SS. Clinico-mycological study of dermatophytic infections and their sensitivity to antifungal drugs in a tertiary care center. *Indian J Dermatol Venereol Leprol* 2017;83:436-40.
- de Sousa Mda G, Santana GB, Criado PR, Benard G. Chronic widespread dermatophytosis due to *Trichophyton rubrum*: A syndrome associated with a *Trichophyton*-specific functional defect of phagocytes. *Front Microbiol* 2015;6:801.
- White TC, Marr KA, Bowden RA. Clinical, cellular, and molecular factors that contribute to antifungal drug resistance. *Clin Microbiol Rev* 1998;11:382-402.
- Turnidge J, Paterson DL. Setting and revising antibacterial susceptibility breakpoints. *Clin Microbiol Rev* 2007;20:391-408.

19. Hanumanthappa H, Sarojini K, Shilpashree P, Muddapur SB. Clinicomycological study of 150 cases of dermatophytosis in a tertiary care hospital in South India. *Indian J Dermatol* 2012;57:322-3.
20. Vyas A, Pathan N, Sharma R, Vyas L. A clinicomycological study of cutaneous mycoses in Sawai man singh hospital of Jaipur, North India. *Ann Med Health Sci Res* 2013;3:593-7
21. Sahai S, Mishra D. Change in spectrum of dermatophytes isolated from superficial mycoses cases: First report from central India. *Indian J Dermatol Venereol Leprol* 2011;77:335-6
22. de Freitas RS, Neves PS, Charbel CE, Criado PR, Nunes RS, Santos-Filho AM, et al. Investigation of superficial mycosis in cutaneous allergy patients using topical or systemic corticosteroids. *Int J Dermatol* 2017;56:e194-8.
23. Lakshmanan A, Ganeshkumar P, Mohan SR, Hemamalini M, Madhavan R. Epidemiological and clinical pattern of dermatomycoses in rural India. *Indian J Med Microbiol* 2015;33 Suppl: 134-6
24. Verma S, Madhu R. The great Indian epidemic of superficial dermatophytosis: An appraisal. *Indian J Dermatol* 2017;62:227-36.

**Source of Support:** Nil; **Conflict of Interest:** None

**Submitted:** 20-05-2020; **Accepted:** 16-06-2020; **Published:** 23-06-2020