

## Foreign Body in Maxillary Deciduous First Molar – A Case Report

Nikhil Chandran<sup>1</sup>, Sudeep C.B.<sup>2</sup>, Joseph Johny<sup>3</sup>, Navaneeth Yerragudi<sup>4</sup>

### ABSTRACT

**Introduction:** Children have a tendency to explore and interact with their external environment by placing and chewing objects in their mouth.

**Case report:** This article reports a case of lodgement of a staple pin in a neglected decay in the left maxillary deciduous first molar in a six year old male patient. The child reported of pain which was spontaneous and aggravated on chewing. An emergency extraction of the tooth involved was performed under local anaesthesia.

**Conclusion:** In conclusion, this article further stresses on the need of periodic examination of the overall oral health status in children and perform necessary early preventive procedures.

**Keywords:** Foreign Body, Primary Teeth, Staple Pin

### INTRODUCTION

Children have a tendency of interacting with the world by placing foreign objects in their mouth. This eventually leads to a consequence of injuring the soft and hard tissues in the oral cavity. The occurrence of foreign bodies such as metal screws, staple pins, darning needles, pencil leads, beads, and tooth-picks lodged in the primary and permanent teeth have been widely reported across the globe.<sup>1</sup> The chances of these foreign objects getting impacted into the tooth is more when the pulp chamber is open either because of traumatic injury or a large carious exposure.<sup>2</sup> These objects once embedded within the tooth may lead to pain and discomfort causing the patient to present to the dentist. Such cases indicate the lack of awareness and dental neglect by the parents. This case report shows the lodgement of a staple pin in a neglected decay in the left maxillary deciduous first molar in a six year old male patient.

### CASE REPORT

A six year male patient reported to the department of pediatric and preventive dentistry with the chief complaint of pain on his upper left back tooth region since 1 week. The pain was spontaneous and aggravated on chewing. The patient reported of avoiding brushing in that area due to the severity of the pain. Medical history and Extraoral examinations were non-contributory. Intraoral examination revealed a deep carious lesion with a shiny silver object embedded w.r.t. 64 (Fig. 1). A detailed history revealed that the patient frequently used pencil nibs and stapler pins to remove food lodged within the tooth. Radiographic examination revealed a stapler pin lodged in the tooth which had penetrated the furcation and impinging the succedaneous erupting first premolar (Fig 2). The treatment plan involved emergency extraction of 64 (Fig 3 & 4) along with the foreign object under local anaesthesia

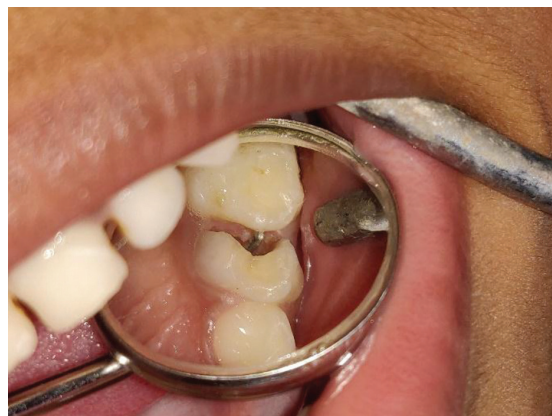

Figure-1: Intraoral Examination

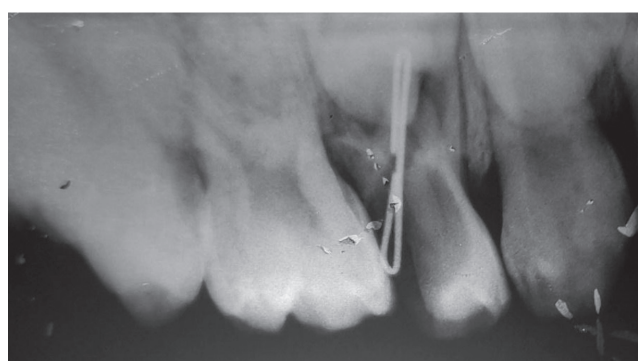


Figure-2: Radiographic examination w.r.t. 64

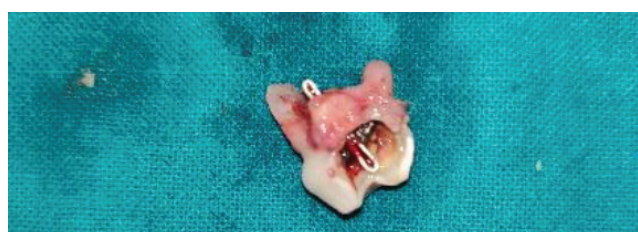

Figure-3: Extracted tooth w.r.t. 64 with lodged staple pin

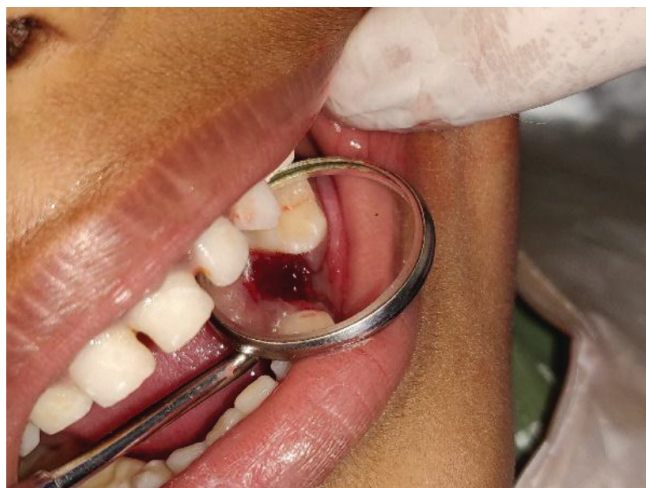<sup>1</sup>Resident Pediatric Dentist, Department of Dentistry, District Hospital, Vadakkara, <sup>2</sup>Associate Professor, Department of Public Health Dentistry and Oral epidemiology, Sree Anjaneya Institute of Dental Sciences, Calicut, <sup>3</sup>Associate Professor, Department of oral medicine and radiology, Sree Anjaneya Institute of Dental Sciences, Calicut, <sup>4</sup>Senior Resident, Department of Dentistry, All India Institute of Medical Sciences, Mangalagiri

**Corresponding author:** Dr. Nikhil Chandran, Department of Dentistry, Government District Hospital, Vadakkara, Kozhikode District, Kerala - 673101, India

**How to cite this article:** Nikhil Chandran, Sudeep C.B., Joseph Johny, Navaneeth Yerragudi. Foreign body in maxillary deciduous first molar – a case report. International Journal of Contemporary Medical Research 2020;7(6):F4-F5.

**DOI:** <http://dx.doi.org/10.21276/ijcmr.2020.7.6.8>





**Figure-4:** Post extraction socket

followed by placement of short band and loop w.r.t. 64.

## DISCUSSION

Children playfully place various objects in the mouth and can lead to accidental ingestion and lodgement of foreign objects in teeth and soft tissues. A number of foreign objects have been reported to be lodged in the pulp chamber and root canals of both primary and permanent teeth. Metallic paper clip, metal screws, pencil lead, stapler pins, darning needle, beads, plastic chopsticks, toothpicks, indelible ink pencil, ink pen tips, dressmaker pins, conical metal objects, hat pins, aluminium foils etc.<sup>3</sup> In this present case report, the patient himself admits of using both pencil nibs and stapler pins. These acts provide relief from irritation and pleasure during the removal of food particles. The child may never reveal such usage unless consequential complications like pain develop.<sup>4</sup>

There is also a potential risk of smaller items being ingested or, more seriously, aspirated leading to the obstruction of the airway. Ingested metal objects may be toxic or may generate toxic chemicals from reactions with body fluids and acids. Most foreign body aspirations occur in children younger than 5 years old, with 65% of deaths affecting infants younger than 1 year. In this present case the child may have even self-attempted to remove the staple pin with other foreign objects which may have lead to deeper lodgement of the pin. Dental neglect on the part of parents causes the children to resort to such measures as well as leads to a long-term sequelae before the foreign body is discovered.<sup>1</sup>

Foreign bodies lodged in soft tissues like gingiva or soft palate may cause inflammation and scarring. The consequences of implanted/embedded intraoral foreign bodies include infections, pain or abscess, cyst, swelling, and tumor-like appearance.<sup>5</sup> Goldstein et al discussed the development of Actinomyces at the apex of the tooth with the radiopaque foreign body in the root canal. They also stated that foreign object aided in establishment of anaerobic conditions necessary for development of infections.<sup>6</sup> Foreign body in deciduous dentition can lead to perforation of the pulp chamber floor space and possibly interfering with developing permanent dentition in the form of odontoma, impaction,

and dilaceration.<sup>5</sup> The possibility of foreign body reaction, formation of granuloma, and non-healing pathology may develop over a long period of time in case of no intervention. Hence, in this case report all these predictable complications indicated the need of extraction of the tooth to preserve the overall integrity of the child's oral health.

## CONCLUSION

The presence of any foreign object in the oral cavity could be a potential source for several complications. Dental neglect by the parents and the fear of revealing such ill usage of foreign objects by the child ends in sacrificing the tooth. This case report emphasizes the need of appropriate dental care at regular intervals in children to avoid such untoward incidences.

## REFERENCES

1. Lakhani B, Garg S, Saraf BG, Tomer E, Singh N, Sheoran N. Self-insertion of Foreign Objects in Teeth. *Int J Clin Pediatr Dent.* 2019; 12.
2. Godhi SB, Adav SN, Kumar SS, Shanbhog R, Sumana MN, Rashmi S. A case of embedded staple pin in the root canal: Mangement and microbiological analysis. *Dental Hypotheses.* 2014;5:29
3. Sharma A. Dental Neglect leading to foreign body in tooth. *J Orofac Res* 2013;3:263-265
4. Srivastava VK. Self-inserted foreign objects inside root canal of fractured incisors: an unusual behaviour. *J Indian Dent Assoc.* 2014;8:31-35.
5. Katge F, Mithiborwala S. Incidental radiographic discovery of a screw in a primary molar: an unusual case report in a 6 year old child. *Case Rep Dent* 2013;2013:296425.
6. Goldstein BH, Sciubba JJ. Actinomycosis of the maxilla: review of literature and report of case. *J Oral Surg* 1972;30:362-366.

**Source of Support:** Nil; **Conflict of Interest:** None

**Submitted:** 06-05-2020; **Accepted:** 20-05-2020; **Published:** 18-06-2020