

Oculo-Cutaneous Manifestation of Neurofibromatosis Type 1: A Rare Case Report

Sunanda Nandi¹, J.J. Kuli²

ABSTRACT

Introduction: Neurofibromatosis type 1 (NF-1) is an autosomal dominant disorder involving multiple systems and affects approximately 1 out of 3000 persons. Ocular manifestations are very rare with lisch nodules, plexiform neurofibroma, optic pathway gliomas.

Case report: Here we present a case of teenager boy with neurofibromatosis type 1 presenting with Rare ocular features along with systemic manifestation of the disease.

Conclusion: The proper diagnosis of NF-1 is a crucial task for a clinician due to the various clinical manifestations including vision and life threatening malignancies in few patients, which may arise in the different phases of life.

Keywords: Neurofibromatosis, Ophthalmic, Lisch Nodules, Maculopathy

INTRODUCTION

Neurofibromatosis (NF) has been reported from all parts of the world and has no racial or sexual preponderance.¹ NF-1 presents with characteristic ocular manifestations. The presence of optic nerve glioma and Lisch nodules are important diagnostic signs.

It's also associated with systemic manifestations like skeletal abnormalities, café-au-lait macules, neurofibromas etc. The present communication deals with ophthalmic and systemic evaluation of a case of NF-1, with a special emphasis on the incidence of Lisch nodules and maculopathy.

CASE REPORT

A 13-year-old male presented with a history of mass over the right limb since his childhood which was gradually increasing in size and causing disfigurement of right hand associated with blurring of vision in Left eye. On ophthalmological examination his Visual Acuity R/E - 6/12; L/E - 6/60. Telecanthus and broad nose were also noticed in this patient [figure 1]. Intraocular pressure was 16 mmHg and 18mmHg in the right and left eye, respectively.

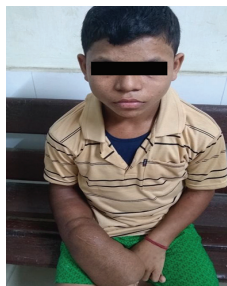

Figure-1: Patient presenting with largest neurofibroma lesion in his right hand

On examination:

Patient is 13 year old boy. Body weight 43 kg, height 146 cm.

Body temperature 36.6°C. Arterial blood pressure 120/70 mm/Hg. Heart rate 68.

Physical Examination revealed more than 20 different size café au lait spots [figure 2] throughout the body, sizes varying from 2mm to >7mm over the trunks and limbs especially on the face and back region; diffuse swelling of the right limb extending from the forearm till the finger tips causing disfigurement of the entire right forearm. There was evidence of freckles in the axillary and inguinal region with the presence of several soft cutaneous sessile neurofibromas varying from few mm to several cm in diameters were present along the trunk, limbs and neck region and especially on the face.

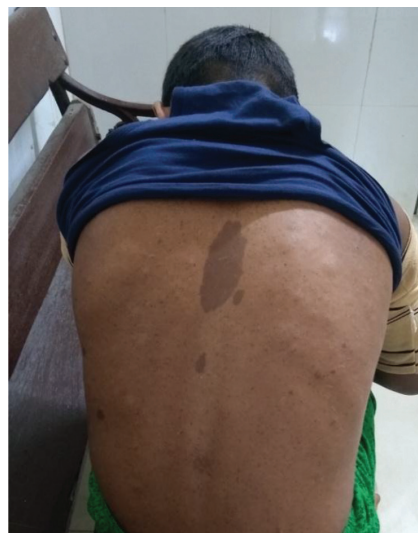

Figure-2: café-au-lait spots

However patient's mental status was normal and he don't

¹Post Graduate Trainee, Department of Ophthalmology, Assam Medical College & Hospital, Dibrugarh, Assam, ²HOD, Professor, Department of Ophthalmology, Assam Medical College & Hospital, Dibrugarh, Assam, India

Corresponding author: Dr.Sunanda Nandi, Post Graduate Trainee, Department of Ophthalmology, Assam Medical College & Hospital, Dibrugarh, Assam, India

How to cite this article: Sunanda Nandi, J.J. Kuli. Oculo-cutaneous manifestation of neurofibromatosis type 1: a rare case report. International Journal of Contemporary Medical Research 2020;7(6):F1-F3.

DOI: <http://dx.doi.org/10.21276/ijcmr.2020.7.6.2>



give any history of previous medication of any systemic ailment

Figure 2 shows light brown patches “cafe-au-lait” spots that are visible on the back and the largest swelling in the right limb is shown in figure 1

Laboratory investigations such as blood parameters, fasting blood glucose, coagulation profile, USG whole abdomen, chest X-ray, Mantoux test, rheumatoid factor and anti-nuclear antibody within normal limits.

Anterior Segment Examination

Lacrimal system, Conjunctiva, Cornea, Anterior Chamber were within normal limits.

Bilateral lisch nodules were seen in the iris of both eyes which are the tiny nodular pigmented lesions protruding above the iris surface.

Both eyes with Lisch nodules (Figure 3).



Figure-3: lisch nodules

Fundus examination

Fundus examination revealed no abnormality in right eye, however the media was hazy in the left eye. The fundus photograph (figure 4) revealed a macular scar in the left eye along with the evidence of old chorioretinitis in the same. There was no retinal breaks or retinal detachment seen bilaterally.

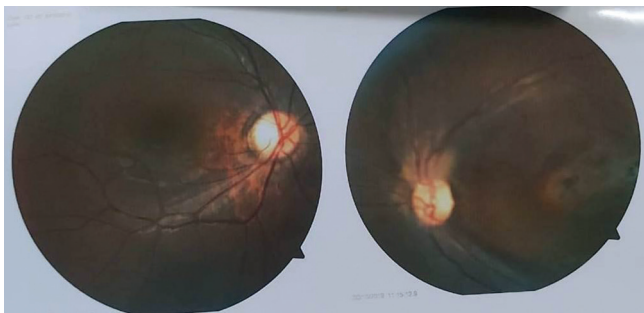

Figure-4: Fundus photograph

CT and MRI brain was ordered to rule out optic glioma, meningioma, acoustic neuroma, schwannoma and it did not show any abnormal feature. Sphenoid wing dysplasia was also not present as shown in figure 5

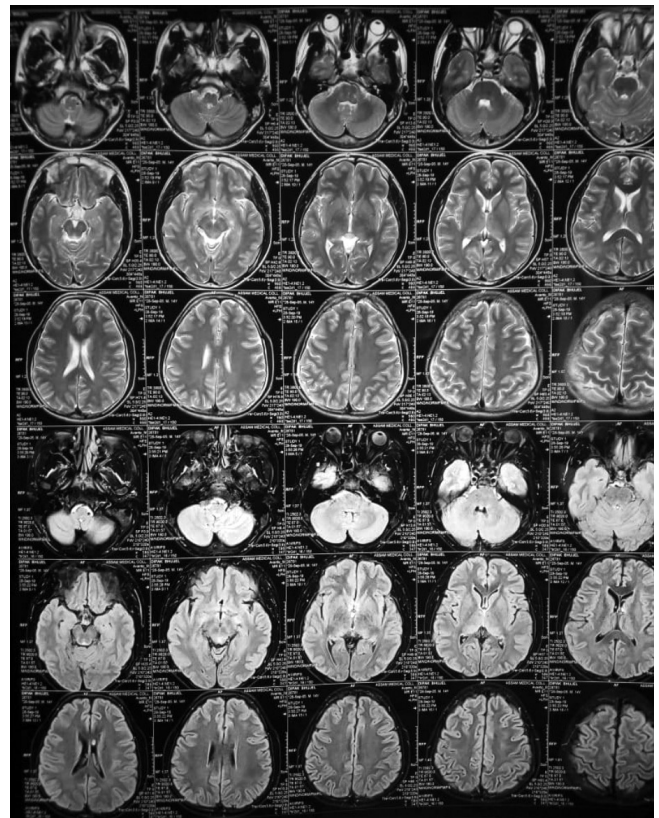


Figure-5: CT Scan picture

Based on clinical features the diagnosis of Neurofibromatosis type I was made. He is the 2nd child out of his 3 siblings. His family history was insignificant for such a disease. Patient was planned for the debulking surgery of his right limb and is in follow up for his ophthalmic manifestations.

DISCUSSION

Neurofibromatosis (NF) is the commonest neurocutaneous syndrome which involves skin and central nervous system. Inheritance is autosomal dominant affecting 1 out of 3,000 persons caused due to mutations of NF-1 gene in chromosome region 17q11.2, encoding neurofibromin protein.¹

NF-1 diagnosis is based on the presence of atleast 2 of the 7 criteria which include: six or more cafe-au-lait macules over 5mm in greatest diameter in prepubertal individuals, frecklings over the axillary and inguinal area, Lisch nodules over the iris, two or more neurofibroma or one plexiform neurofibroma, [sphenoid dysplasia], optic glioma and first-degree relative with NF-1.³ Our case met with three or more criteria and hence it can be clinically diagnosed as a case of neurofibromatosis type 1.

The ophthalmological features with NF-1 were studied in 72 consecutive patients with NF-1 in a study and it was found that the ophthalmological features are relatively rare.⁴ NF-1 presenting with ophthalmic associations like eyelid plexiform neurofibroma, optic glioma, primary congenital glaucoma have been described in the literature.^{5,6,7} Choroidal nodules, vasoproliferative tumours, unusual limbal lesion and neovascular glaucoma are the other ophthalmic manifestations that have been reported rarely.⁸

Lisch nodules are the commonest ophthalmic manifestation of NF-1.⁹ They begin to develop in early childhood and are present in over 95% adults with the disease.⁹ In our case lisch nodules were seen in both eyes along with other ophthalmic features.

Viola et al¹⁰ evaluated choroidal abnormalities in NF1 patients using NIR(near infrared reflectance) in a large group of patients and 82% of patients were found with nodules. The presence of macular scar along with evidence of chorioretinitis in one eye of the patient is in synchrony with the previous literature.

A distinctive facial appearance in the children with NF-1 was first reported by Kaplan et al., in their case series.⁸ These children were having telecanthus, anti mongoloid slant of the palpebral fissure, broad nose and tapering chin. Our case presented with similar features. Therefore, we must not overlook the abnormal facial features during the work-up of a patient with NF-1.

Nystagmus has been reported as the initial presenting sign of chiasmal glioma in young children in a series of 22 patients by Toledano et al¹¹, which was not present in our case.

Debulking of tumour mass is needed in cases of plexiform neurofibroma with NF-1. Ptosis surgery and lateral canthal fixation are the other treatment modalities in cases of plexiform neurofibroma. The clearance of visual axis and cosmetic appearance are the basic goals for surgery.

This case report represents the various clinical manifestations of NF-1 and highlights the importance of ophthalmic examination in such cases as they first presented to the ophthalmologist. As the disease requires a life long follow-up for the various clinical manifestations which may arise in the different phase of life, the early diagnosis of NF-1 becomes a crucial task for clinicians. A holistic multidisciplinary approach is required to diagnose and treat these patients. This case report provide the further knowledge about clinical features of patients with NF-1 which might be helpful for further understanding about the disease.

This is one of the rare case report to be cited in the literature, in which a patient with Neurofibromatosis Type-1 presented with macular scar and chorioretinitis unilaterally along with the other ophthalmic features.

CONCLUSION

Since the patients with NF-1 can present with ophthalmic complaints, the ophthalmic evaluation is an essential part of examination. Proper diagnosis and treatment require the understanding about the myriad of manifestations of NF-1.

REFERENCES

1. Victor Zion: Phakomatosis. In Duane TD ed. Clinical Ophthalmology. Philadelphia Harper and Row, Vol,5:Ch.36(1-3);1983.
2. Huson SM, Compston DA, Clark P, Harper PS. A genetic study of von Recklinghausen neurofibromatosis in south east Wales I. J Med Genet. 1989;26:704-11.
3. Viskochil D, Buchberg AM, Xu G, Cawthon RM, Stevens J, Wolff RK, et al. Deletions and a translocation interrupt a cloned gene at the neurofibromatosis type 1

locus. Cell. 1990;62:187-92.

4. Stumpf D, Alksne J, Annegers J. Neurofibromatosis. Conference statement. National institute of health consensus development conference. Arch Neurol. 1988;45:575-78.
5. Ruggieri M, Pavone P, Polizzi A, Di Pietro M, Scuderi A, Gabriele A, et al. Lannetti P. Ophthalmological manifestations in segmental neurofibromatosis type 1. Br J Ophthalmol. 2004;88:1429-30.
6. Tokraz-Sawinska, E, Puchalska-Niedbal, Lachowicz E, Litwinska J. Plexiform neurofibroma of the upper eyelid and orbit in a patient with von Recklinghausen disease—case report. Klein Oczena. 2014;116:267 71.
7. Levin MH, Armstrong GT, Broad GH, Zimmerman R, Bilaniuk LT, Feygin T, et al. Risk of optic pathway glioma in children with neurofibromatosis type 1 and optic nerve tortuosity or nerve sheath thickening. Br J Ophthalmol. 2016;100:510-14.
8. Li H, Liu T, Chen X, Xie L. A rare case of primary congenital glaucoma in combination with neurofibromatosis 1: A case report. BMC Ophthalmol. 2015;15:149.
9. Kaplan P, Rosenblatt B. A distinctive facial appearance in neurofibromatosis von Recklinghausen. Am J Med Genet. 1985;21:463-70.
10. Lewis RA, Riccardi VM: Von Recklinghausen neurofibromatosis. In incidence of iris hamartoma, Ophthalmology: 88:348-54: 19-81: 1988.
11. Viola F, Villani E, Natacci F, et al. Choroidal abnormalities detected by near-infrared reflectance imaging as a new diagnostic criterion for neurofibromatosis 1. Ophthalmology. 2012;119:369–375.
12. Toledano H, Muhsinoglu O, Luckman J, Goldenberg-Cohen N, Michowiz S. Acquired nystagmus as the initial presenting sign of chiasmal glioma in young children. Eur J Paediatr Neurol. 2015;19:694-700.

Source of Support: Nil; **Conflict of Interest:** None

Submitted: 30-04-2020; **Accepted:** 10-05-2020; **Published:** 12-06-2020