

A Histopathological Study of Fallopian Tube Lesions - in a Tertiary Care Centre

Mondita Borgohain¹, Gayatri Gogoi², Mustafizur Rahman³, Rashmi Roy⁴, Navonil Gogoi⁵

ABSTRACT

Introduction: The fallopian Tube or the oviduct has been named after Gabriellis Fallopius, who was the first to describe the tubes very accurately. It is one of the commonest surgical specimens received in the histopathological laboratory. It is the commonest cause of infertility and inflammatory diseases. Malignancy of the fallopian tube is rarely encountered. The present study was undertaken with the following objectives to evaluate the histological patterns of the fallopian tube in surgically resected specimens and to determine its relationship with uterine or ovarian pathology.

Material and Methods: A total number of 309 specimens of Fallopian tube were obtained from the patients who underwent pan hysterectomy with salpingectomy and salpingo-oophorectomies in Assam Medical College and Hospital during the period from October 2016 to September 2018. The clinical datas along with gross and microscopic findings were studied. Incidence and prevalence of various lesions were calculated.

Results: In our study 10cases (3%) had been marked as unremarkable. 77.4% were diagnosed as Chronic Salpingitis, 8.95% as Hydrosalpinx and 2.47% as Ectopic Pregnancy. The other cases comprised mainly of Haematosalpinx and normal histology

Conclusion: Fallopian tubes can present with different pathological findings. Malignancies of the Fallopian Tube are uncommon but it has to be examined properly to exclude a precursor Tubal Pathology.

Keywords: Chronic Salpingitis, Hydrosalpinx, Haematosalpinx, Ectopic Pregnancy, Infertility, Salpingectomy, Salpingo-Oophorectomy, Infertility, Pan Hysterectomy, Histopathology.

females. Salpingitis can lead to infertility and increase the chances of ectopic pregnancies.^{2,3}

The fallopian tube plays an essential role in fertility by acting as a duct for sperm and oocyte; and for the transport and nourishment of the fertilized ovum.⁴ The tubes are less frequently affected by ectopic tubal pregnancy followed by endometriosis and rarely by primary tumors.⁵ Secondary involvement of the Fallopian Tubes from other primary sites, mostly the Ovaries, Cervix and Endometrium, has been observed.^{6,7} Tubal metastasis usually indicates poor prognosis. Familiarity with the fallopian tube diseases is of utmost importance for accurate and timely diagnosis. The present study was undertaken with the following objectives to evaluate the histological patterns of the fallopian tube in surgically resected specimens and to determine its relationship with uterine or ovarian pathology.

MATERIAL AND METHODS

The present study comprised of specimens of fallopian tube received in the Department of Pathology Assam Medical College during the period. Approval for conduction of the study was taken from the Institutional ethics committee.

Inclusion Criteria: All specimens sent with fallopian tube to the histopathology section of the Department of Pathology, irrespective of age were included in the study.

Exclusion Criteria: The specimens without Fallopian Tube were excluded from the study.

Patient's bio data and clinical information were extracted from the requisition forms. The primary lesion which prompted the surgery was grossly examined and sampled according to routine histopathological gross examination procedures.

INTRODUCTION

The Fallopian tube or the oviduct, also known as the uterine tube, is a paired hollow muscular tube, one on either side of the uterus and lies at the upper margin of the broad ligament of the uterus. It was Gabrielio Fallopio who first described the Fallopian tube. His work on this organ was published posthumously in the year 1564. The anatomy of the fallopian tube is complex starting from its development, ciliated microstructure and vascular structure. It is the key to the conduit of ova and fertilization.¹ Fallopian Tube consist of interstitial portions (uterine end), isthmus, ampulla (wider portion) and infundibulum and opens as finger like projections toward ovary. Its average length is 11-12 cm. Salpingitis is the most common infection in women of the reproductive age group, and it occurs due to ascending infection from the vagina. It affects approximately 11% of

¹Professor, Department of Pathology, Assam Medical College, Dibrugarh, ²Assistant Professor, Department of Pathology, Assam Medical College, Dibrugarh, ³PGT, Department of Pathology, Assam Medical College, Dibrugarh, ⁴Senior Research Fellow, Department of Pathology, Assam Medical College, Dibrugarh, ⁵Senior Research Fellow, Department of Microbiology, Assam Medical College, Dibrugarh, Assam, India

Corresponding author: Dr. Mondita Borgohain, Professor, Department of Pathology, Assam Medical College, Dibrugarh, Assam, India

How to cite this article: Mondita Borgohain, Gayatri Gogoi, Mustafizur Rahman, Rashmi Roy, Navonil Gogoi. A histopathological study of fallopian tube lesions - in a tertiary care centre. International Journal of Contemporary Medical Research 2020;7(5):E5-E8.

DOI: <http://dx.doi.org/10.21276/ijcmr.2020.7.5.24>



The fallopian tubes were sampled using SEE FIM protocol in order to ensure optimal histological evaluation.

As per the protocol the distal 2 cm (the fimbrial end) of the fallopian tube was amputated from the rest of the tube and sectioned longitudinally. The remainder of the tube was cut in cross sections (bread loafed) at 2-3 mm interval. The entire specimen was submitted for processing.

This sampling technique ensured that the surface epithelium of the fimbria is extensively exposed since in situ/early neoplastic epithelial lesion was most often seen in the fimbriae.

All the sections were stained with Haematoxylin and Eosin and the slides were studied by three of the investigators to arrive at the diagnoses. Lesions were diagnosed and classified based on the criteria established in two reference text.^{8,9} STIC is defined as focal replacement of normal fallopian tube epithelium by cells with malignant features.^{10,11,12} The clinical history of the Patients as per requirements were collected in a predesigned proforma. Grossing of the specimen was performed, and the size, surface, cross-sectional surface and contents were recorded. Three cross sections were taken from each tube in the proximal, mid and distal portions for microscopic examination. The proximal portion was serially cross sectioned at 2-3 mm intervals, and the fimbriated end was longitudinally sectioned for maximal exposure. The sections were routinely processed and H& E staining was done and microscopic findings were studied.

Data obtained were statistically analyzed using frequency and cross tabulation procedures in IBM SPSS software version 20.0 for windows.

RESULTS

A total number of 309 specimens with Fallopian tube were obtained from the patients who underwent panhysterectomy with salpingectomy and salpingo - oophorectomy in Assam Medical College and Hospital during the period from October 2016 to September 2018.

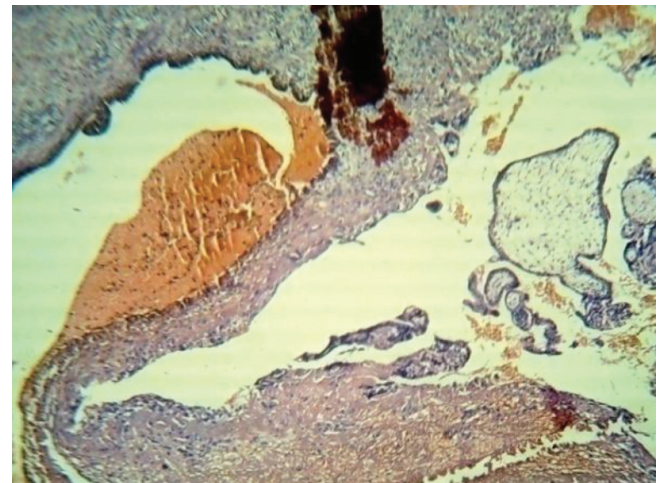


Figure-1 Photomicrograph showing Chronic Villi and Trophoblastic tissue in tubal wall in a case of ectopic tubal gestation (X4)

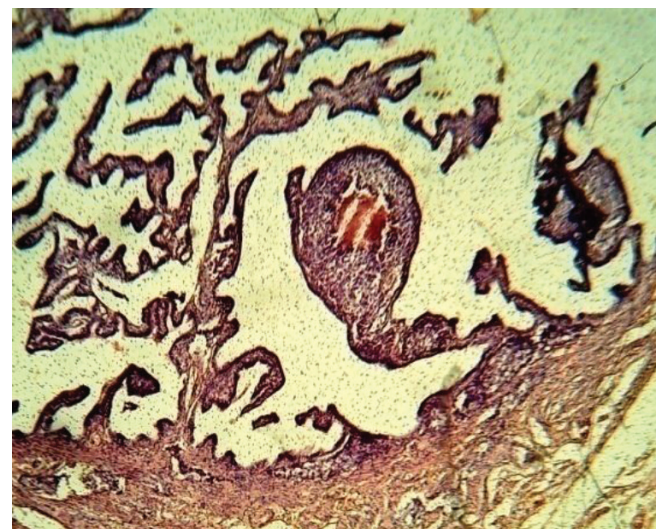

Figure-2 Photomicrograph showing secondary metastasis in the tubal folds (X4)

| Age Range | Number | Percentage |
|-----------|--------|------------|
| 20-29 | 15 | 4.85% |
| 30-39 | 88 | 28.47% |
| 40-49 | 155 | 50.16% |
| 50-59 | 36 | 11.65% |
| 60-69 | 12 | 3.88% |
| 70-79 | 3 | 0.97% |

Table-1: Showing the different Age groups in the study.

| Diagnosis | Number | Percentage |
|---------------------|--------|------------|
| Chronic Salpingitis | 251 | 77.47% |
| Hydrosalpinx | 29 | 8.95% |
| Normal Histology | 4 | 1.23% |
| Haemato salpinx | 1 | 0.31% |
| Ectopic pregnancy | 8 | 2.47% |
| Unremarkable | 10 | 3.09% |
| Others | 6 | 8.33% |

Table-2: Showing the distribution of Pathological lesions in the Fallopian Tube.

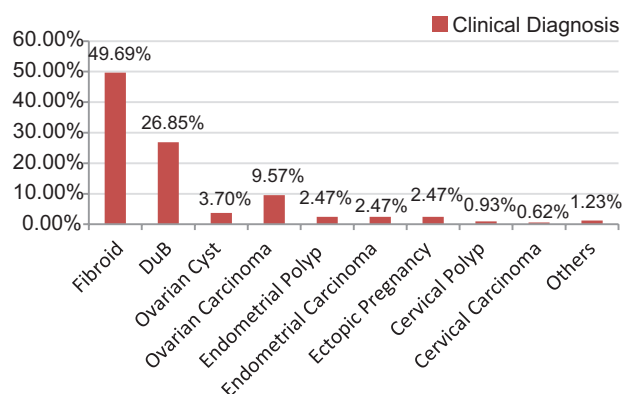


Figure-3: Distribution of cases according to clinical diagnosis.

The table 1 shows that most of the cases 155 were between the age range (40-49) yrs which accounted for 50.16% followed by the age range of (30-39) yrs that is 28.47%. The lowest age was 20yrs and the highest was 79 yrs in our study. Chronic Salpingitis of the Fallopian Tube was the commonest finding which accounted for 77.47% of the cases. This was followed by hydrosalpinx in 8.95% of cases, as shown in

above table 2. Ectopic pregnancy was diagnosed in 8 cases (2.47%) as shown in fig 1. Two cases showed secondary metastasis in the tube from dysgerminoma and krukensberg's tumour of ovary as shown in fig 2. In this study 10 cases (3.09%) had unremarkable findings and 4(1.23%) showed normal histology. No statistically significant relation existed between the cases collected (chi-square: $\chi^2 = 0.227$, $p = 0.853$)

DISCUSSION

Our study comprised of 309 specimens of Fallopian Tubes, of which 10 had been marked as unremarkable. The most common diagnosis was Inflammatory, followed by ectopic pregnancy which was consistent with the findings of Bagwan et al.¹³ In this study only 10 cases had unremarkable findings, hence the cases with tubal Pathology outnumbered the cases with unremarkable Tubes. This was consistent with the findings of Kujur et al.¹⁴

Chronic Salpingitis of the Fallopian Tube was the most common Pathological lesion which accounted for 77.4% in our study. This finding was consistent with the study done by Mahajan et al.¹⁵ Seidman et al found that 27% of the Fallopian Tubes had Chronic Salpingitis which was not associated with any ovarian pathology but these figure increased to 53% when it was associated with epithelial tumors of the ovary.^{16,17}

Salpingitis is one of the most common infections of women in reproductive age group. Commonly due to ascending infection and can vary from asymptomatic to life threatening illnesses.¹⁸ Acute salpingitis develops as a result of ascending infection from the cervix and uterus and typically occurs in young females of the reproductive age group. Chronic salpingitis was characterized by blunted plicae with a dense lymphocytic infiltrate to markedly fibrotic lesions and complete flattening of the epithelial lining.^{19,20}

In India the incidence of Ectopic Pregnancy is 3.12 per 1000 pregnancies and Fallopian Tube is the commonest site followed by the ovary and abdominal cavity.²¹ In the present study we had 8 cases of Ectopic Pregnancy which were proved histopathologically, which accounted for 2.47% of the total cases. This finding was consistent with the finding of Manjunath et al.²² These cases were received as salpingectomy specimens and most of the patients were below 30years. Trophoblastic tissue or chorionic villus structures were demonstrated in the tubal wall or in the haemorrhagic tissue in most of the cases.^{23,24}

Primary fallopian tube carcinoma (PFTC) is very rare about 0.14-1.8% of female genital malignancies. The risk factors are mostly hormonal, reproductive age group and BRCA-1 and BRCA-2 Mutations.^{25,26} The knowledge of the prevalence of PFTC and the relationship of PFTC to breast cancer requires familiarity with the imaging features. There was no case of primary tumor whether benign or malignant in our study. Metastatic Carcinoma of the Fallopian Tube was an incidental finding in our study from two patients with ovarian dysgerminoma and Krukenberg tumour. These findings were consistent with the studies done by Bagwan et

al and Kujur et al.^{13,14}

Haematosalpinx is defined as bleeding into the fallopian tubes; tubal pregnancy is the most common cause of hematosalpinx. The source of tubal pregnancy is determined by the site of the blood collection, it presents as a broad ligament hematoma if the tube ruptures at the inferior end. This can form pelvic hematocele if the tube rupture on the tube. If the bleeding occurs within the tube without ruptures or abortion, hematosalpinx can result. Paratubal cysts (PTCs) are remnants of paramesonephric or mesonephric ducts and mostly benign. These masses have been reported in all the age groups beginning from premenarchial period up to menopause, but most commonly are seen in the third and fourth decades of life. Haematosalpinx and paratubal cyst were found in 1 case each in our study. Paratubal cyst have no clinical significance and our finding was similar to the findings of Mahajan et al.²⁷

CONCLUSION

The Fallopian Tube received in histopathology must be thoroughly examined and Histopathological patterns must be well studied. This simple organ is not only important in studies of female infertility and ectopic pregnancies, but it can be the site of origin of high grade serous carcinoma of the ovary and peritoneum. Detection of the precursor tubal pathology in these carcinomas will help us to decrease the burden and treatment of these cases in time.

ACKNOWLEDGMENT

We wish to express our appreciation to Miss Sunia Roy for her assistance and cooperation in carrying out the study.

REFERENCES

1. Kumar V, Cotran R S, Robbins SL, Female genital system and breast. In Kumar V, Cotran RS, Robbins SL (eds) Basic Pathology 6th Edn Harcourt Asia PTE LTD. 2001: Pp 597-636
2. McCormack WM. Pelvic inflammatory disease. N Engl J Med 1994; 330: 115-19
3. Paavonen J. Pelvic inflammatory disease. From diagnosis to prevention. Dermatol Clin 1998; 16: 747-56
4. Poseri J. Female Reproductive system- Fallopian Tube, In Rosai J Rosai and Ackermans Surgical Pathology 10th Ed. Mosby 2011: Pp 1541-52
5. Barnhart KT. Ectopic pregnancy. N Engl J Med 2009; 361:379-87
6. Rosenblatt KA, Weiss NS, Schwartz SM. Incidence of malignant fallopian tube tumors. Gynecol Oncol 1989; 35: 236-39
7. Wilcox R, Gwin K, Montag A. The incidence of fallopian tube primaries reaches 15% of all adnexal tumours when standardized grossing protocols are followed. Lab Invest 2009; 89(Suppl 1): 241A
8. Wang R, Wheeler JE. Disease of Fallopian tube and paratubal region. In: Ellenson HL, Ronnet MB KR, editor. Blaustein's Pathology of the female genital tract. 6th ed. New York: Springer; 2011 Pp. 530-72
9. Alvarado-cabrero I, Cheung A CR. Tumours of the fallopian tube. In: Tavassoli FA DP, editor. WHO

- Classification of tumours: pathology and genetics of tumours of the breast and female genital organs. Lyon: IARC Press; 2003.
10. Kindelberger DW, Lee Y, Miron A, Hirsch MS, Feltmate C, Medeiros F, et al. Intraepithelial carcinoma of the fimbria and pelvic serous carcinoma: evidence for a causal relationship. *Am J Surg Pathol.* 2007;31:161-69.
 11. Crum CP. Intercepting pelvic cancer in the distal fallopian tube: Theories and realities. *Mol Oncol.* 2009;3:165-70.
 12. Przybycin CG, Kurman RJ, Ronnett BM. Are all pelvic (Nonuterine) serous carcinomas of tubal origin? *Am J Surg Pathol.* 2010;34:1407-16.
 13. Bagwan IN, Harke AB, Malpani MR, Deshmukh SD. Histopathological Study of Spectrum of lesions found in the fallopian tube. *J Obstet Gynecol India* 2004;54:379-82.
 14. Kujur Pratima, Kosam shashikala, Gupta Anurag. Histopathological Study of Spectrum of Lesions Seen in Surgically Resected Specimens of Fallopian Tube. *Int J of Sci Stud* 2016; 4: 39-43.
 15. Andersor JR, Cenadry R, Anatomy and Embryology. In Berek JS (ed) *Nowaks Gynecology 13th Edb*:Lippin cott Williams and Wilkins, 2002: Pp 69-121
 16. Seidman, Jeffrey D. M.D.; Sherman, Mark E. MD; Bell, Karen A. MD et al.: *Saspingitis, Salpingoliths and serous Tumours of the Ovaries: Is there a Connection?: International Journal of Gynecological Pathology* 2002;21:101-107.
 17. Patel J, Iyer RR. Spectrum of histopathological changes in fallopian tubes-a study of 350 cases. *Int J Sci Res* 2016;5:180-1.
 18. Vang R, Wheeler JE. Diseases of the fallopian tube and paratubal region. In: Kurman RJ, Ellenson LH, Ronnett BM (eds). *Blaustein's pathology of the female genital tract*, 6th Edn. Springer New York, 2011; pp. 529-78
 19. Margara RA, Trew GH. Tubal disease. In: Shaw RW, Soutter WP, Stanton SL (eds). *Gynaecology*, 2nd Edn.:Churchill Livingstone, 1997; pp. 319-28
 20. Washington AE, Aral SO, Wolner-Hanssen P, Grimes DA, Holmes KK. Assessing risk for pelvic inflammatory disease and its sequelae. *JAMA* 1991; 266: 2581-86
 21. Barnhart KT. Ectopic pregnancy. *N Engl J Med* 2009; 361: 379-87
 22. Manjunath H K et al. Spectrum of lesions encountered in Fallopian tube histopathology; Retrospective analysis: our experience; *Archives of Cytology and Histopathology Research*, July-September, 2016;1: 45-49
 23. Sharma R, Biligi DS. A study of histopathological changes in fallopian tubes in ectopic pregnancy. *Int J Cur Res Rev* 2015; 7:54-8
 24. Green LK, Kott ML. Histopathologic findings in ectopic tubal pregnancy. *Int J Gynecol Pathol* 1989; 8: 255-62
 25. Crum CP, Drapkin R, Kindelberger D, Medeiros F, Miron A, Lee Y. Lessons from BRCA: the tubal fimbria emerges as an origin for pelvic serous cancer. *Clin Med Res* 2007; 5:35-44
 26. Jarboe E, Folkins A, Nucci MR, et al. Serous carcinogenesis in the fallopian tube: a descriptive classification. *Int J Gynecol Pathol* 2008;27:1-9
 27. Mahajan D et al. Histological Patterns in Fallopian Tube Pathology- A Retrospective study of 200 Consecutive Cases. *JK Science* 2016;18:23-30.

Source of Support: Nil; **Conflict of Interest:** None

Submitted: 17-03-2020; **Accepted:** 28-04-2020; **Published:** 28-05-2020