

# Hyaluronic Acid: Glimmer of Optimism for Black Triangles

Neha Taneja<sup>1</sup>, Praveen Kudva<sup>2</sup>, Kulvinder Singh<sup>3</sup>

## ABSTRACT

**Introduction:** Interdental papilla reconstruction, in esthetic areas is proven to be one of the most challenging tasks in periodontology. Hyaluronic acid is a glycosaminoglycan molecule with anti-inflammatory, anti-edematous properties on periodontal tissues invaded by submicrobial flora.

**Case report:** A 35 years old male patient reported to department of periodontics and oral implantology, Jaipur dental college with the chief complaint of loss of gum (inter dental papilla), i.e. black triangle, in the upper front teeth (anterior maxillary teeth). Patient was esthetically concerned about this. Treatment planning was to reconstruct the lost interdental papilla by injecting 0.2% hyaluronic acid via nonsurgical approach. The procedure was performed after a standardized working protocol of injecting dermal fillers in papillae, digital photographing and measuring the outcomes for observation periods between 2 weeks to 3 months.

**Conclusion:** Injecting dermal fillers in gingiva resulted in a volume raise of papillae height.

The use of dermal fillers is a minimally invasive way to optimize gingival contours. It is a non-invasive approach which reduces patient's postoperative discomfort with marked variations in the volume of interdental papilla before and after the procedure.

**Keywords:** Hyaluronic Acid, Black Triangle, Interdental Papilla, Linear Threading, Aesthetic.

## INTRODUCTION

The space that exists between two adjacent teeth is called as inter dental space. The cervical pyramid is covered by the interdental gingival papilla.

Histologically it is formed by a dense connective tissue covered by oral epithelium. Factors determining its shape are contact relationships between the teeth, width of the approximal tooth surfaces, and course of the cemento-enamel junction (CEJ).<sup>1,2</sup>

Loss of interdental papilla can be caused by a variety of factors and leads to formation of black triangle between teeth by the virtue of plaque associated lesions being the most common cause. Apart from this, abnormal tooth shape, improper contours of prosthetic restorations and traumatic oral hygiene are the other contributory factors to the formation of black triangle.<sup>2</sup>

Black triangles are one of the most important aspects of the decision making process of a clinician. According to Tarnow et al (1992) this condition may create aesthetic impairments and food impactions.<sup>3</sup>

One of the major aesthetic challenges in micro facial enhancement is related to the ability of rejuvenation of the lost papilla in the maxillary anterior segment.

Several surgical and non-surgical techniques have been proposed to treat black triangle and to manage the interproximal space. The non-surgical treatment modalities include orthodontic, prosthetic and restorative procedures. They modify the interproximal space, thereby inducing modifications of the soft tissues.

On the other hand, surgical techniques aim to recontour, preserve or reconstruct the soft tissue between two teeth or in between teeth and the implants.<sup>2</sup>

The recent non surgical approach includes use of hyaluronic acid based dermal fillers as a biocompatible volumizing gels that are used to restore volume and structure in areas which have lost collagen or fat. Dermal fillers can be injected into the interdental papilla to volumize the triangle.

## CASE REPORT

A 35 years old male patient reported to department of periodontics and oral implantology, Jaipur dental college with the chief complaint of loss of gum (inter dental papilla), i.e. black triangle, in the upper front teeth (anterior maxillary teeth). Patient was esthetically concerned about this.

**Diagnosis:** Patient was diagnosed with black triangle in maxillary anterior teeth.

**Treatment plan:** after examination use of hyaluronic acid derivative (Restylane) dermal fillers in treatment of black triangle was decided.

Patient's oral hygiene was found to be good. A written informed consent was taken from the patient before the procedure, and ethical clearance certificate was obtained from the institution.

At baseline radiographic and clinical records (RVG and Adobe software) were taken and scaling and root planing was done. Same procedure was repeated at 3 and 6 months. He was included in the study based on

1. **Papilla Presence Index-** Score II (Papilla is no longer completely present and lies apical to the contact point and not at the same level as the adjacent papillae, but the CEJ is still not visible) (had a complaint of at least one black

<sup>1</sup>Dental Private Practitioner, Sriganganagar, Rajasthan, <sup>2</sup>Professor & HOD, Department of Periodontology, <sup>3</sup>Medical Private Practitioner, Sriganganagar, Rajasthan, India

**Corresponding author:** Dr. Neha Taneja, SI-5, Ridhi Sidhi Enclave First, Hanumangarh Road, Sriganganagar, Rajasthan (India), 335001.

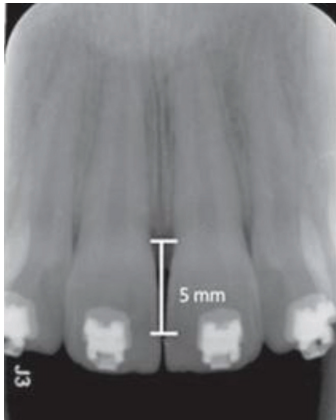
**How to cite this article:** Neha Taneja, Praveen Kudva, Kulvinder Singh. Hyaluronic acid: glimmer of optimism for black triangles. International Journal of Contemporary Medical Research 2020;7(5):E8-E12.

**DOI:** <http://dx.doi.org/10.21276/ijcmr.2020.7.5.8>

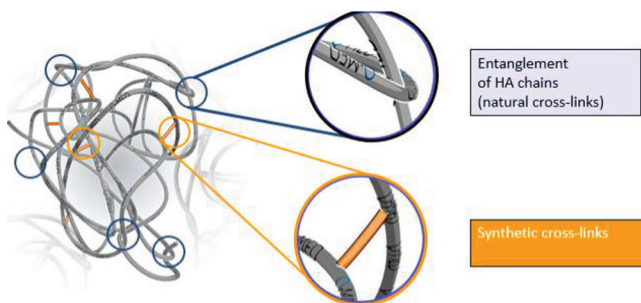


triangle(loss of interproximal papilla) in the maxillary anterior region falling under Papilla presence index score 2 given by Cardaropoli et al (2004).

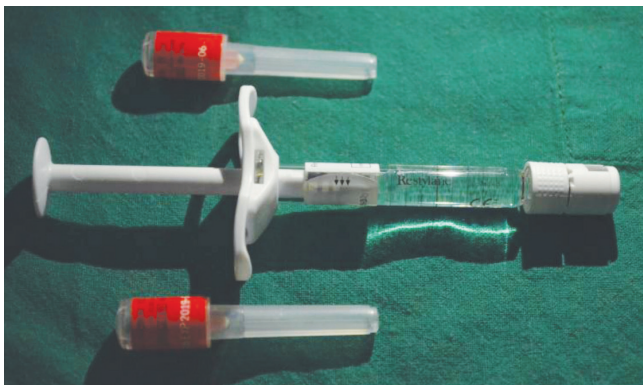
**2. Tarnow's 5mm law:** When the distance from the contact point to the alveolar bone was less or equal to 5 mm, the papilla was present in 98% of the times, while at 6 mm it dropped to 56% and at 7 mm it was only present 27% of the



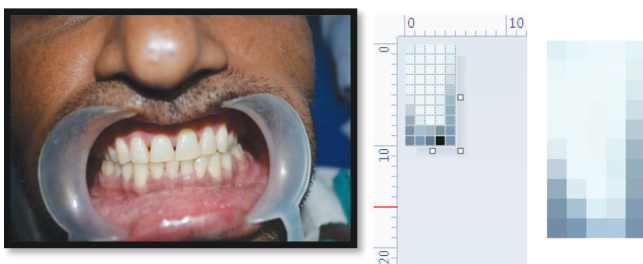
**Figure-1:** Tarnow's 5mm law



**Figure-2:** Stabilization of NASHA gel



**Figure-3:** Armamentarium



**Figure-4:** Pre-operative photograph with baseline RVG and adobe software reading

times.[fig.1]

3. Age 25-45 years
4. Thin gingival biotype
5. Scalloped periodontal bioform
6. Narrow contact points
7. Vertical brushing technique
8. Maxillary incisors

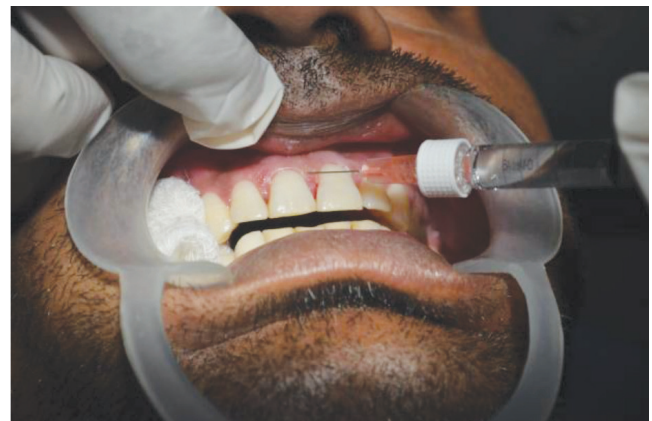He was explained about the procedure and it's outcomes.

Symmetry was analysed and recorded

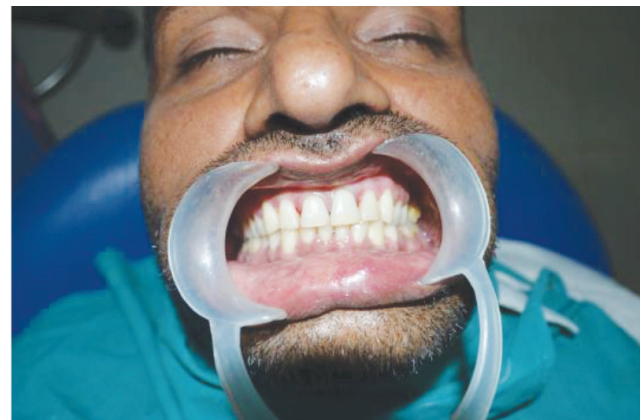Gingival thickness was measured using vernier's calipers.

Post giving infraorbital block, the dermal filler (Restylane) was injected using Linear threading method in retrograde manner.[figure 3-7].

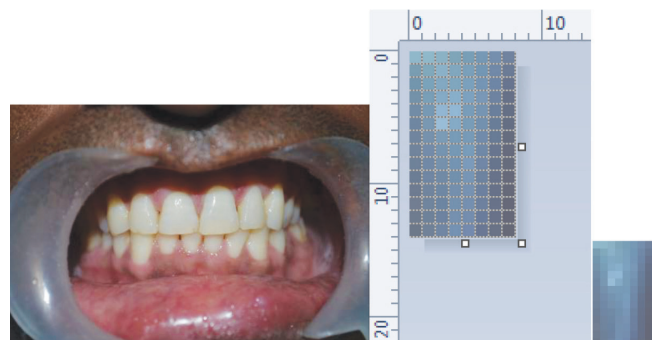
Patients having hypersensitivity reaction, Autoimmune disease, diabetes, hypertension, pregnancy, lactation and



**Figure-5:** Insertion technique



**Figure-6:** Immediate post-operative photograph



**Figure-7:** 3 months post operative photograph with RVG and adobe software reading



Unrealistic expectations are not ideal candidates for study.

Post-operative instructions:- Patient was asked to refrain from massaging for two weeks and refrain from exposing to extreme of temperature. Recalled at 1 week, 3 months, 6 months. At recalls, intra-oral photographs were taken and comparison was done using these images. This treatment modality resulted in significant gain in papillary volume and esthetic improvements. Therefore the desired result was obtained with the multiple use of hyaluronic acid.

## DISCUSSION

Macro facial esthetics enhancement with soft tissue augmentation started as early as in 1800s when Neuber used small pieces of fat from the upper arm to reconstruct depressed facial defects.<sup>4</sup>

micro facial enhancement was first of all done by Gersuny by using low melting point paraffin as an injectable filler to correct cosmetic deformities.<sup>5</sup> The use of this material, however, was discontinued around the 1930s because it was associated with high incidences of inflammatory reactions and foreign-body granuloma formation.<sup>6</sup>

over the years other injectable materials that have been tried include vegetable oil, mineral oil, lanolin, and beeswax. They were later discarded because they were associated with undesirable tissue reactions such as movement of the material, chronic edema, scarring, and granuloma formation. Such kind of material led to investigations using highly purified polymers such as silicone as dermal fillers. Introduced in 1962, medical grade liquid silicone was widely used to correct a variety of cosmetic defects. Presently, it is banned in the United States due to its high abuse potential and adverse effects such as foreign body granuloma formation from adulterated compounds.

In past few years alternative materials, both tissue-derived and synthetic have been discovered. These include injectable bovine collagen, autologous fat, hyaluronic acid derivatives, and allogenic and synthetic products.

Popularly used dermal fillers are of two types: permanent and non-permanent. We most commonly use non-permanent fillers that are hyaluronic acid based, containing no animal proteins or allergens, ensuring their safety. They are biodegradable after injection into the skin. They are available in different thicknesses, suitable for applications ranging from fine smokers lines to cheek enhancement. They last from four months to two years after the initial treatment depending on the strength of the product used. Longer lasting and permanent fillers are also available, however, it is recommended that first dermal filler should be non-permanent to ensure that both the clinician and patient are happy with the visual result of the treatment before proceeding with a permanent filler. secondly, permanent fillers sometimes may require surgical intervention also.

The treatment takes approximately 20 to 30 minutes depending on the volume required and the area to be covered. Swelling and a small amount of bruising are possible, which usually resolve within a couple of days.<sup>7</sup>

## Hyaluronic Acid

HA was discovered in 1934 from cow's eye by Karl Meyer and John Plamer and was first used in 1942 by Endre Balazs as a substitute for egg white in bakery products.<sup>8,9</sup>

Hyaluronic acid is a constituent of the ground substance of normal dermis and has considerable water-binding capabilities which influence dermal volume and compressibility. It is a glycosaminoglycan composed of repeating dimeric units of D-glucuronic acid and N-acetyl-glucosamine, which provide a fluid matrix on which collagen and elastic fibres can develop. It is obtained from either avian or bacterial culture sources.

It contributes in tissue hydrodynamics, cell migration, and proliferation, and improves healing properties of the tissue.<sup>10</sup> It is critically beneficial in tissue regeneration.<sup>11</sup> It has also been reported that HA shows osteoinductive properties, which is useful for treatment of periodontal disease.<sup>12</sup> Other beneficial effects have also been seen for the treatment of recurrent aphthous ulcer,<sup>13</sup> for treating gingival lesions,<sup>14</sup> and promote healing in extraction socket.<sup>15</sup> Recent investigations have indicated that HA induces mineralization of dental pulp cells through CD44 cell surface glycoprotein and is considered to be a principle ligand for receptor CD44.<sup>16</sup>

Hyaluronic acid is highly suited for soft tissue augmentation because it is insoluble, resists degradation, does not migrate, and retains a high water content. Its derivatives that are used for soft tissue augmentation are cross-linked to decrease proteolytic degradation rates. its degradation takes place inside the cell by a family of enzyme called hyaluronidases. It is a naturally occurring polysaccharide. HA molecule with the flexible molecular network entangles with its neighbours forming a complex structure resulting in a 3D HA network that preserve the natural HA chains with only minimal modification

- HA used in the manufacture of NASHA is biosynthesized from non-animal source
- NASHA® gel

## Stabilization

The unique and patented NASHA technology preserves the natural entanglement of the HA network by introducing a small amount of synthetic cross-links with minimal modification

NASHA® based HA will be recognised as endogenous HA. It will be slowly degraded by the same mechanisms as endogenous HA.

With the major advantage of uniformity of its chemical structure throughout all living species, rendering a minimal chance of immunogenicity. Therefore, pretreatment allergic skin testing is not necessary. Also, unlike collagen products, these products are colorless; therefore, they can be injected superficially without concern of discolorations showing through the skin. The handling of these products is generally considered to be superior to bovine collagen because of easier flow rates. Additionally, they need not be refrigerated; however, if they are exposed to heat, monomers will form which can contribute to inflammation. They do not contain

lidocaine, so slight pain may be associated with injection. Several studies have been proposed regarding the effects of HA on periodontium. Becker et al.<sup>17</sup> concluded that HA gel is a synthetic material and can be used with no drug interference and is a safe material, which significantly decreases the interdental black triangle in the esthetic zone. It has also been approved by the Food and Drug Association.

Vedamurthy<sup>18</sup> reported HA to be a dermal filler and applied it for soft tissue augmentation, observing significant improvements. Monheit et al.<sup>19</sup> discussed the inherent properties of HA that make them ideal for cosmetic surgeries. Prato et al.<sup>20</sup> Studied gingival augmentation with an autologous cell HA and reported significant results with the complete coverage.

A recent randomized, double-blind, multicentre clinical trial comparing a bacterial cultured hyaluronic acid derivative (Restylane) with bovine collagen (Zyplast) was conducted. 138 patients with prominent nasolabial folds were treated and followed up for 6 months. Results showed that less injection volume was required to achieve optimal cosmetic results when hyaluronic acid was used. Both patients and investigators judged hyaluronic acid gel to be more effective in maintaining cosmetic correction. The frequency, intensity, and duration of local injection site reactions were similar for the 2 products. The investigators concluded that nonanimal stabilized hyaluronic acid provides a more durable esthetic improvement than bovine collagen.<sup>21</sup>

Another study of 158 patients receiving Restylane with a follow-up of 8 months revealed satisfactory results as evaluated by both physicians and patients. Photographic evaluation revealed even better results with an 80.4% chance of moderate or marked improvement. Histologically, at 1 year, the product was shown to be long-lasting and well-tolerated.<sup>22</sup> A drawback of this study is that there were no positive or negative control groups.

A recent multicenter, longitudinal clinical trial, however, included collagen filler (Zyplast) as a control group. Blinded examiners evaluated 68 patients randomized to receive either filler for the treatment of nasolabial folds. Evaluations were performed up to 1 year after treatment. Clinically significant better results were found in the group of patients that received hyaluronic acid as a filler. Optimal cosmetic results were achieved with a smaller volume of the test filler. Additionally, the test group demonstrated less local injection site inflammation.<sup>23</sup>

Since hyaluronic acid fillers are less expensive than the bovine collagen products, these products may be a better option.

Various surgical and nonsurgical approaches are proposed in the periodontal literature to provide satisfactory interdental papilla reconstruction.

The present study treated black triangle using hyaluronic acid derived (Restylane) dermal fillers. Result showed significant changes, it can be used as a noninvasive method, which will reduce the use of surgical procedures for regenerating soft tissues in upcoming years. This study can be limited by the amount of the interproximal tissue loss, depending upon

the size of the black triangle, which might require surgical intervention to gain complete coverage. The main advantage of this study is that it is nontoxic to the patient and there is reduced discomfort after the procedure as compared to surgical procedure done. Furthermore, this study can be elaborated by more number of patients depending upon the size and type of the black triangle.

## CONCLUSION

In recent years, derma fillers have made their way into dentistry for both dental esthetic and dental therapeutic uses in the oral and maxillofacial areas. They are here to stay and with more and more intra oral uses of these materials, they are fast becoming an integral part of everyday dental practice including restorative, aesthetic, periodontal, orthodontic and prosthodontics implications. They provide patients with most significant, predictable, minimally invasive, aesthetic and therapeutic outcomes available for many everyday clinical situations. These treatments are more than a complement to esthetic Dentistry dermal fillers are now an integral part of every esthetic dental treatment plan. Randomized, long-term clinical trials are still needed to evaluate efficacy, longevity, and long-term effects of these products. Continuing research promises that advances, such as recombinant human collagen, are on the horizon.

## REFERENCES

1. Plato Palathingal, Jaideep Mahendra, Treatment of Black Triangle: A Novel Approach, Journal of Clinical and Diagnostic Research. 2011 December, Vol-5(8): 1688-1691
2. PiniPrato G, Rotundo R, Cortellini P, Tinti C, Azzi R. Inter-dental papilla management: A review and classification of the therapeutic approaches. Int J Periodontics Restorative Dent 2004; 24:246-55.
3. Tarnow DP, Wagner AW, Fletcher P. The effect of the distance from the contact point to the crest of the bone on the presence or absence of the inter-proximal papilla. J Periodontol 1992; 63:995-96.
4. Neuber F. Fetttransplantation [in German]. Kongressband/Deutsche Gesellschaft für Chirurgie. 1893;22:66.
5. Gersuny JS. Hard-paraffin prosthesis. Zentralblatt für Chirurgie. 1903;1:86-88.
6. Maas CS, Papell ID, Greene D, Stoker DA. Complications of injectable synthetic polymers in facial augmentation. Dermatol Surg. 1997;23:871-877.
7. Internet sources:- cosmetic image clinics
8. Dahiya P1, Kamal R. Hyaluronic Acid: A Boon in Periodontal Therapy. N Am J Med Sci 2013;5:309-15.
9. Tanwar J, Hungund SA. Hyaluronic acid: Hope of light to black triangles. J Int Soc Prevent Communit Dent 2016;6:497-500
10. Mansouri SS, Ghasemi M, Salmani Z, Shams N. Clinical Application of Hyaluronic Acid Gel for Reconstruction of Interdental Papilla at the Esthetic zone. J Islamic Dent Assoc Iran 2013;25:152-7.
11. Sahayata VN1, Bhavsar NV, Brahmabhatt NA. An Evaluation of 0.2% Hyaluronic Acid Gel (Gengigel®) in the Treatment of Gingivitis: A Clinical and

- Microbiological Study. *Oral Health Dent Manag* 2014;13:779-85.
12. Abdulhameed BS, Ibraheem LM. Periodontal effect of 8% Hyaluronan as an Adjunct to Scaling and Root Planning in the treatment of Chronic Periodontitis (Comparative Study). *J Dent Med Sci* 2014;13:76-81.
  13. Nolon A, Baillie C, Badminton J, Rudralinglam M, Seymour RA. The efficacy of topical hyaluronic acid in the management of recurrent aphthous ulceration. *J Oral Pathol Med* 2006;35:461-5.
  14. Jentsch H, Pomowski R, Kundt G, Göcke R. Treatment of gingivitis with hyaluronan, *J Clin Periodontol* 2003;30:159-64.
  15. Mendes RM1, Silva GA, Lima MF, Calliari MV, Almeida AP, Alves JB, et al. Sodium hyaluronate accelerates the healing process in tooth sockets of rats. *Arch Oral Biol* 2008;53:1155-62.
  16. Chen KL, Yeh YY, Lung J, Yang YC, Yuan K. Mineralization Effect of Hyaluronan on Dental Pulp Cells via CD44. *J Endod* 2016;42:711-6.
  17. Becker W, Gabitov I, Stepanov M, Kois J, Smidt AE, Becker B. Minimally invasive treatment for papillae deficiencies in the esthetic zone: A pilot study. *Clin Implant Dent Relat Res* 2010;12:1-8.
  18. Vadamurthy M. Soft tissue augmentation: Use of hyaluronic acid as dermal filler. *Indian J Dermatol Venereol Leprol* 2004;70:383-7.
  19. Monheit GD, Coleman KM. Hyaluronic acid fillers. *Dermatol Ther* 2006;19:141-50.
  20. Prato GP, Rotundo R, Magnani C, Soranzo C, Muzzi L, Cairo F. An Autologous Cell Hyaluronic Acid Graft Technique for Gingival Augmentation: A Case Series. *J Periodontol* 2003;74:262-7.
  21. Narins RS, Brandt F, Leyden J, Lorenc ZP, Rubin M, Smith S. A randomized, double-blind, multicenter comparison of the efficacy and tolerability of Restylane versus Zyplast for the correction of nasolabial folds. *Dermatol Surg*. 2003;29:588–595.
  22. Duranti F, Salti G, Bovani B, Calandra M, Rosati ML. Injectable hyaluronic acid gel for soft tissue augmentation. A clinical and histological study. *Dermatol Surg*. 1988;24:1317–1325.
  23. Lindqvist C, Tveten S, Bondevik BE, Fagrell D. A randomized, evaluator-blind, multicenter comparison of the efficacy and tolerability of Perlane versus Zyplast in the correction of nasolabial folds. *Plast Reconstr Surg*. 2005;115:282–289.

**Source of Support:** Nil; **Conflict of Interest:** None

**Submitted:** 30-03-2020; **Accepted:** 11-04-2020; **Published:** 14-05-2020