

Evaluating the Effect of Dextrose Prolotherapy on Temporomandibular Disorders by Choosing Different Injection Sites- A Comparative Clinical Study

Mubashir Younis¹, Ajaz A. Shah², Abina Rashid³

ABSTRACT

Introduction: Prolotherapy is a minimally invasive technique used in the treatment of temporomandibular disorders. Prolotherapy agent induces an inflammatory process in the joint, stimulates fibroblast proliferation, hence facilitates the healing process and strengthens the joint and associated ligaments and tendons. The main aim of this article was to study the effect of 25% dextrose prolotherapy on temporomandibular joint pain, clicking and maximum mouth opening by using different injection sites.

Material and methods: Sixty patients with established diagnosis of unilateral disc displacement with reduction who complained of unilateral symptoms (pain and clicking) were included in the study. They were randomly allocated to three groups (Group A, Group B and Group C) of 20 patients each. Group A patients received intra-articular injections into the superior joint space, Group B patients received injections into the inferior joint space where as Group C patients were given injections into the retrodiscal tissues. Each group received subsequent injections at first, second and third weeks at the respective sites. Pain, clicking and maximum mouth opening (MMO) was recorded pre-operatively, post-operatively at 3 weeks and 2 months.

Results: Group B and Group C patients showed a significant decrease in the pain score at 3 weeks and 2 months post-operatively while as no significant pain relief was observed in Group A. Maximum mouth opening improved significantly in Group B and Group C patients at 3 weeks and 2 months and was highest in Group C. Reduction in clicking was best seen in Group C.

Conclusion: Prolotherapy is more effective when injection site is selected as per the type of symptoms of the patients with temporomandibular disorders.

Keywords: Prolotherapy, Temporomandibular Disorders, Intra-Articular Injection, Retrodiscal Tissues

INTRODUCTION

Temporomandibular Joint Disorders (TMD) is a general term used for a group of disorders that cause pain and dysfunction of the temporomandibular joint (TMJ) and associated structures. TMDs are among one of the most common causes of facial pain. Trauma is a well-known cause and may occur in the form of an acute injury like whiplash or may be as a result of repetitive microtrauma. Other possible causes include parafunctional habits, bruxism, longstanding occlusal interferences, joint overloading, psychological factors and non-ergonomic position of head.^{1,2} Common symptoms include pain at TMJ region, generalized orofacial

pain, limited and painful mouth opening, locking of the jaw, clicking, popping or crepitation sounds during opening or closing of the mouth associated with hypomobility or hypermobility of TMJ. Other symptoms include otalgia, tinnitus and chronic headaches.^{3,4}

The first line approach includes non-invasive treatment like analgesics, muscle relaxants, anxiolytics, antidepressants, soft diet, application of heat or ice, massage, occlusal splints, ultrasonography, phonophoresis, transcutaneous electrical nerve stimulation (TENS), iontophoresis and physiotherapy. Minimally invasive treatment options include dry needling, trigger-point injections into the muscle, intra-articular injections with local anesthetic or steroid, acupuncture, arthrocentesis and arthroscopy. Surgical option is kept as a last resort especially for refractory cases.⁵

Prolotherapy or proliferation therapy has been defined in Webster's dictionary as "the rehabilitation of an incompetent structure, such as a ligament or tendon, by the induced proliferation of cells." Prolotherapy is based on the principle that the cause of most chronic musculoskeletal pain is the laxity of the associated ligaments and tendons. Prolotherapy agent induces an inflammatory process in the joint, stimulates fibroblast proliferation, hence facilitates the healing process and strengthens the joint and associated ligaments and tendons.^{6,7} A similar concept is used in the treatment of TMDs. The main aim of this article was to study the effect of 25% dextrose prolotherapy on temporomandibular joint pain, clicking and maximum mouth opening by using different injection sites.

MATERIAL AND METHODS

The study was approved from the Institutional Ethical Committee. Sixty patients reporting to the department of Oral

¹Fellow Craniomaxillofacial Trauma, Elite Mission Hospital Thrissur, Kerala, ²Professor and Head, Department of Oral & Maxillofacial Surgery, Govt. Dental College, Srinagar, J&K, ³Consultant Endodontist, Bangalore, Karnataka, India

Corresponding author: Mubashir Younis, Fellow Craniomaxillofacial Trauma, Elite Mission Hospital Thrissur, Kerala, India

How to cite this article: Mubashir Younis, Ajaz A. Shah, Abina Rashid. Evaluating the effect of dextrose prolotherapy on temporomandibular disorders by choosing different injection sites- a comparative clinical study. International Journal of Contemporary Medical Research 2020;7(1):A1-A3.

DOI: <http://dx.doi.org/10.21276/ijcmr.2020.7.1.32>



and Maxillofacial Surgery Govt. Dental College Srinagar with established diagnosis of unilateral disc displacement with reduction who complained of unilateral symptoms (pain and clicking) were included in the study and informed consent was taken from each patient. Patients with bilateral involvement, systemic diseases, previous TMJ surgeries and blood dyscrasias were excluded from the study. The patients were randomly allocated to three groups (Group A, Group B and Group C) using random number cards, each group consisting of twenty patients.

Prolotherapy technique

All the patients received auriculotemporal nerve block under aseptic conditions using 0.5 ml of 2% lignocaine with 1:100000 adrenaline. We used 2 ml of 25% dextrose as the proliferant solution in each case.

Group A (injection site- superior joint space): Keeping the patient’s mouth closed, the condyle was palpated and marked. The needle was then advanced from below upwards until it reached the upper bony surface of the glenoid fossa and the proliferant solution was injected. Twenty patients received intra-articular injection into the superior joint space.

Group B (injection site- inferior joint space): The condyle was palpated and marked with the patient’s mouth closed. The needle was introduced from top downwards until it reached the superior bony surface of the condyle and the proliferant solution was injected. Twenty patients received intra-articular injection into the inferior joint space.

Group C (injection site-retrodiscal tissues): Keeping the patient’s mouth wide open, the condyle was palpated and marked. The solution was the injected into the space between the posterior surface of the condyle and the tragus. Twenty patients received injection into the retrodiscal tissues.

Each group received subsequent injections at first, second and third weeks at the respective sites. Pain score was assessed pre-operatively, at 3 weeks and at 2 months using VAS scale with a score of 0 indicating no pain and a score of 10 indicating worst possible pain. Similarly maximum mouth opening (MMO) was recorded pre-operatively, at 3 weeks and 2 months.

RESULTS

A total of 60 patients were included in the study out of which 47 were females and 13 males. Pre-operative pain score was comparable among all three groups. Group A patients showed no statistically significant difference

in the pain score both at 3 weeks and 2 months. Group B and Group C patients showed a significant decrease in the pain score at 3 weeks and 2 months post-operatively. Maximum mouth opening improved significantly in Group B and Group C patients at 3 weeks and 2 months and was highest in Group C. Clicking improved in 16 patients at 3 weeks and 23 patients at 2 months and best results were seen in Group C. The results are tabulated in Tables 1, 2, 3, 4 and 5 and graphically represented in Figures 1 and 2.

Group	Mean difference compared to pre-operative	p value
Group A		
At 3 weeks	-0.4	0.588
At 2 months	-0.7	0.324
Group B		
At 3 weeks	-3.5	<0.001
At 2 months	-4.4	<0.001
Group C		
At 3 weeks	-4.4	<0.001
At 2 months	-5	<0.001

Table-2: Mean difference in pain score of each group at different stages when compared to pre-operative pain score

Group	Pre-operative	At 3 weeks	At 2 months
Group A	33.2(3.385)	33.8(2.749)	33.8(2.749)
Group B	32.6(3.352)	35.1(2.964)	35(2.966)
Group C	32.3(2.722)	39.7(1.791)	40.2(1.469)

Table-3: Mean maximum mouth opening in mm of each group at different stages

Group	Mean difference (in mm) compared to pre-operative	p value
Group A		
At 3 weeks	+0.6	0.542
At 2 months	+0.6	0.542
Group B		
At 3 weeks	+2.5	0.017
At 2 months	+2.4	0.022
Group C		
At 3 weeks	+7.4	<0.001
At 2 months	+7.9	<0.001

Table-4: Mean difference in maximum mouth opening in each group at different stages when compared to pre-operative mouth opening

Group	At 3 weeks	At 2 months
Group A	2	3
Group B	4	6
Group C	10	14
Total	16	23

Table-5: Number of patients in each group who showed an improvement in clicking at different stages

	Pre-operative	At 3 weeks	At 2 months
Group A	6.1(2.142)	5.7(2.471)	5.4(2.289)
Group B	5.9(2.487)	2.4(2.497)	1.5(1.658)
Group C	6.3(2.215)	1.9(1.841)	1.3(1.584)

Table-1: Mean pain score of each group at different stages

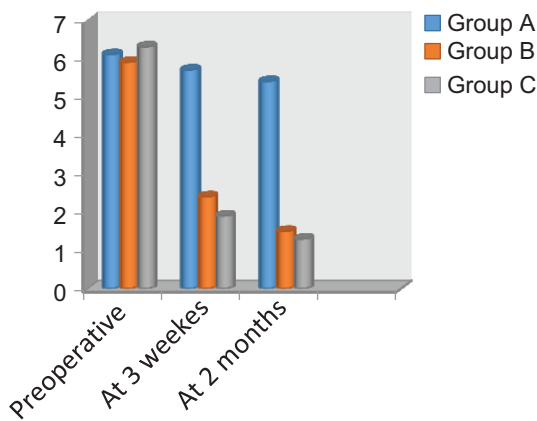


Figure-1: Mean pain score (VAS) of each group at different stages

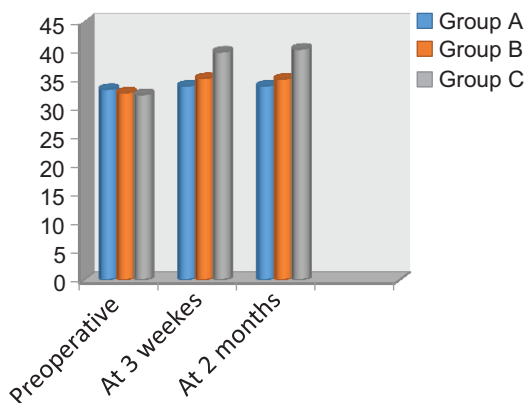


Figure-2: Mean maximum mouth opening (mm) of each group at different stages

DISCUSSION

TMDs are more common in young females and same was the case with our study in which 78.3% of the patients were females with mean age of 28.6 years. Prolotherapy is a non-invasive technique that stimulates proliferation and regeneration of the tendons and ligaments, promotes joint healing and stabilizes the fibro-osseous junctions.⁸ In our study, we evaluated the effect of 25% dextrose prolotherapy on pain, maximum mouth opening and clicking associated with TMDs by injecting it at different sites. Although injections into the superior joint space decreased some pain but pain relief was better with injections into the inferior joint space and retrodiscal tissues. Similarly mouth opening improved significantly in patients receiving injections into the inferior joint space and retrodiscal tissues while as improvement in clicking was best seen in cases with retrodiscal injections. Our results are in accordance with the study conducted by A.A. Fouda.⁵

Prolotherapy also has a vital role in the treatment of hypermobility disorders of temporomandibular joint. Injections around the TMJ capsule limit mouth opening by strengthening the capsule and the ligaments thereby effectively decreasing the episodes of recurrent TMJ dislocation or sub-luxation.^{9,10,11}

CONCLUSION

Prolotherapy is economical and an acceptable method of

treating TMDs. It provides good pain relief, improves joint movements and mouth opening and decreases clicking sounds of the joint. Injections into the retrodiscal tissues and inferior joint space provide better pain relief while patients complaining of only clicking achieve better results with retrodiscal injections. Hypermobility disorders of TMJ are better treated with pericapsular injections.

REFERENCES

1. Tanaka E, Detamore MS, Mercuri LG. Degenerative disorders of the temporomandibular joint: etiology, diagnosis, and treatment. *J Dent Res* 2008; 87:296–307.
2. Green CS. Orthodontics and temporomandibular disorders. *Dent Clin North Am* 1988;32:529–38.
3. Kumar AV, Jaishankar HP, Kavitha AP, Naik PR. Prolotherapy: A new hope for temporomandibular joint pain. *Indian J Pain* 2013;27:49-52.
4. Hauser RA, Hauser MA, Blakemore KA. Dextrose prolotherapy and pain of chronic TMJ dysfunction. *Pract Pain Manage* 2007;1:49-55.
5. Fouda AA. Change of site of intra-articular injection of hypertonic dextrose resulted in different effects of treatment. *Br J Oral Maxillofac Surg* (2017).
6. Kaul R, Shilpa PS, Bhat S. Management of Temporomandibular Disorders using Prolotherapy: A Review of Current Concepts. *Int J Sci Stud* 2014;2:73-76.
7. Hakala RV. Prolotherapy (proliferation therapy) in the treatment of TMD. *Cranio* 2005;23:283-8.
8. Lewis J: Tendon and ligament repair in fractures and dislocations. In: Gustilo RB, ed. *The fracture classification manual*. St. Louis MO: Mosby-Year Book Inc., 1991:90-91.
9. Zhou H, Hu K, Ding Y. Modified dextrose prolotherapy for recurrent temporomandibular joint dislocation. *Br J Oral Maxillofac Surg* 2014; 52:62–66
10. Cömert Kilic S, Güngörmüş M. Is dextrose prolotherapy superior to placebo for the treatment of temporomandibular joint hypermobility? A randomized clinical trial. *Int J Oral Maxillofac Surg* 2016; 45:813–9.
11. S. K. Majumdar, Shreya K, Aritra C, Rajib C, Nazrealam A. Single injection technique prolotherapy for hypermobility disorders of TMJ using 25% dextrose: A clinical study *J. Maxillofac. Oral Surg.* 2016.

Source of Support: Nil; **Conflict of Interest:** None

Submitted: 14-11-2019; **Accepted:** 31-12-2019; **Published:** 26-01-2020