To Evaluate Sono-Elastography Features of Inguinal Lymph Node in cases of Carcinoma Penis

Rishi Raj Vohra[1], Ujwal Kumar[2], Sher Singh Yadav[3], Vinay Tomar[4], Usha Jaipal[5]

ABSTRACT

Introduction: Inguinal lymph nodes are the commonest site of penile metastasis whose incidence varies from 50% to 70% depending on the stage of disease . To differentiate reactionary to metastatic lymph node fine needle aspiration cytology, tru-cut needle biopsy and dissection of inguinal lymph node has been used. We tried to evaluate sono-elastography features of inguinal lymph node in cases of Carcinoma Penis. Study aimed to evaluate sono-elastography, B-mode ultra-sonography and their combination for characterization of palpable inguinal lymph node in patients of carcinoma penis.

Material and method: 34 lymph node evaluated with sono-elastography for elastogram and strain ratio, B-mode ultra-sonography and their combination which were compared with trucut needle biopsy taken as gold standard

Results: The overall sensitivity, specificity and accuracy of B-mode ultra-sonography, sono-elastography and their combination is 78%, 82%, 86%; 84%, 80%, 81% and 89%, 73%, 79% respectively. Sensitivity and specificity of elastography strain ratio by taking 2.3 as cutoff is 89.5% and 86.7% respectively.

Conclusion: US elastography appears to be a promising tool for differentiating benign and malignant lymph nodes. Further studies are needed to fully standardize the clinical application of this technique with large sample size at multiple centers.

Keywords: Sonoelastography, Inguinal, L Ymph Node, Trucut

INTRODUCTION

Penile cancers accounts for 0.4 to 0.6% of all malignant neoplasm among males in United States[1] with higher incidence in developing world, where this malignancy contributes 1-2% of all malignant diseases.[2] Inguinal lymph nodes are the commonest site in penile metastasis whose incidence varies from 50% to 70% depending on the stage of disease.[3]

To differentiate reactionary to metastatic lymph node fine needle aspiration cytology, trucut needle biopsy and dissection of inguinal lymph node has been tried. Fine needle aspiration cytology has sensitivity and specificity of > 87%[4], groin dissection has the highest sensitivity while trucut biopsy has 89% sensitivity and 97% specificity.[5] Search for a non invasive technology which has sensitivity and specificity same to that of invasive technique is still ongoing.

Sonoelastography is emerging as a new tool to diagnose metastasis in lymph nodes. In this technique elasticity of tissue is not only assessed but its hardness is also being quantified. Initial results of this modalities are encouraging when used in cervical and axillary lymphadenopathy.[6-7] As inguinal lymph nodes are also superficial so we contemplated this study where we compared outcome of sono-elastography in reference to tru-cut needle biopsy.

In sono-elastography, image representation of tissue hardness can be obtained using a conventional sonography machine with special software.[8,9] In brief, sono-elastography works in the following steps: first, elastography receives digital radiofrequency echo lines from the tissue; second, on slight manual compression to the tissue with the transducer along the radiation axis for making some displacement; and third, it receives another, post compression digitized radiofrequency echo line from the same tissue.[9] Then this data from the two echo lines undergo processing, and ultimately an elastographic image (elastogram) appears on the monitor. There are two types of elastograms, gray-scale and color. The hard and soft areas (i.e., areas of high and low elasticity, respectively) appear in the gray-scale elastogram as dark and bright.[10,11] In the color elastogram, increasing hardness of a tissue appears in ascending order as red, yellow, green, and blue. Strain ratio is calculated by comparing tissue under investigation with the surrounding normal tissue as reference.

Study aimed to evaluate sono-elastography, B-mode ultra-sonography and their combination for characterization of palpable inguinal lymph node in patients of carcinoma penis.

MATERIAL AND METHODS

This prospective interventional study was approved by ethics committee of Swai Man Singh medical college and attached hospitals. Informed consent was taken from the patients. Patients of all stages of carcinoma penis admitted in surgical

[1]Ex Resident, Department of Urology and Renal transplant, SMS Medical College and Hospital, Jaipur, [2]Assistant Professor, Department of Urology and Renal Transplant, IKDRC, Ahmedabad, [3]Professor, Department of Urology and Renal transplant, SMS Medical College and Hospital, Jaipur, [4]Professor, Department of Urology and Renal transplant, SMS Medical College and Hospital, Jaipur, [5]Professor, Department of Radiology, SMS Medical College and Hospital, Jaipur, India

Corresponding author: Dr Ujwal Kumar, D 701, Akshardham towers, Near Shahibaug underbridge, Shahibaug, Ahmedabad-380004 (Gujarat), India

How to cite this article: Rishi Raj Vohra, Ujwal Kumar, Sher Singh Yadav, Vinay Tomar, Usha Jaipal. To evaluate sono-elastography features of inguinal lymph node in cases of carcinoma penis. International Journal of Contemporary Medical Research 2019;6(12):L1-L6.

DOI: http://dx.doi.org/10.21276/ijcmr.2019.6.12.15

specialties were taken as subjects.

Study duration was from November 2015 to February 2017. Patients having persistent palpable inguinal lymph nodes in single or both groin after treatment of primary lesion and 4-6 weeks of antibiotic treatment were included in this study. History of any groin surgery, bleeding diasthesis, fixed or fungating lymph nodes were the exclusion criteria. All of these patients underwent ultra-sonography of both the groins for the presence of lymph nodes. In cases of multiple nodes most superficial and prominent node in each groin was included in our study. Each lymph node was considered as a discrete subject. Tru cut needle biopsy of these was performed with Bard 18G tru-cut needle gun.

These lymph node were evaluated by hitachi hi-vision preirus ultrasonography machine with a linear transducer (L-74M) 5-13 MHz. A single experienced radiologist performed all the sono-elastography. Images of elastography were obtained by continuous manual compression and strain ratio was calculated by comparing lymph node with surrounding subcutaneous tissue by the inbuilt software. Node was considered malignant when the strain ratio was more than 2.3.[7] Strain elastogram of the subject node was also calculated. Elastography score was calculated according to scoring system proposed by Furkawa *et al*.[12,13] from strain elastogram. Elastography score of <2 were taken as reactive node and more than two as metastatic.[7,14]

B-mode ultra-sonography was done by the same radiologist for following characteristics of nodes: short axis diameter, longitudinal to transverse axis ratio, echogenicity of cortex, presence of hilum and margins of lymph node. An echogenic, centrally located hilum is a feature of normal lymph nodes which is because of parallel arrangement of lymphatic sinuses. Due to metastatic involvement of nodes, the hilum may be eccentric, thinned, or absent. Metastatic nodes tend to have an absent hilum, but echogenic hilum may be seen in their early stage of involvement, as medullary sinuses have not been sufficiently disrupted to obliterate it. In this study, node was considered metastatic when short axis diameter >8mm, longitudinal to transverse axis ratio was <2, abnormal or absent hilum, inhomogeneous echotexture of cortex and irregular margins of lymphnode.[15]

Subsequently enlarged nodes underwent Trucut needle biopsy for histological confirmation.

STATISTICAL ANALYSIS

SPSS 20 was used for statistical analysis. To identify

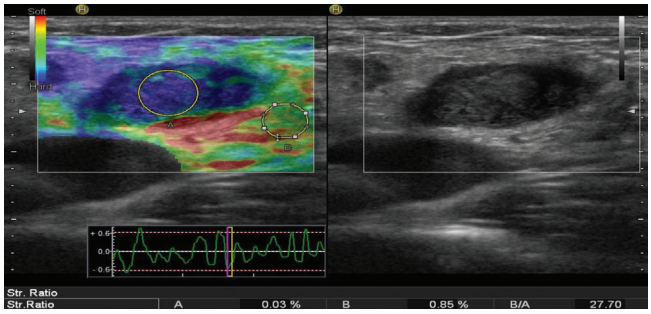

Figure-1: Elastography strain ratio of the subject node with surrounding tissue

Criteria	Lymph nodes		Accuracy	Sensitivity	Specificity
	Benign	Malignant			
B mode					
Size of short-axis diameter (8mm)					
≤ Cutoff value	13 (86.67)	4 (21.05)	83.1	78.9	86.7
>Cutoff value	2 (1.33)	15 (78.95)			
L/S axis ratio					
>2	9 (60)	8 (42.1)	58.4	57.9	60
<2	6 (46)	11 (57.89)			
Border					
Regular	11 (73.33)	6 (31.58)	72	68.4	73.3
Irregular	4 (26.67)	13 (68.42)			
Hilum					
Present	12 (80)	2 (10.53)	88.6	89.5	80
Abnormal or Absent	3 (20)	17 (89.47)			
Echogenicity					
Homogeneous	10 (66.67)	3 (18.75)	77	84.21	66.7
Inhomogeneous	5 (33.33)	16 (81.25)			
Elastography Score					
1	10	1			
2	3	2	81	84	80
3	1	2			
4	1	14			
Strain ratio					
< 2.3	12	2	85.3	89.5	80
>2.3	3	17			

Table-1: Results According to Criteria for Reactive and Metastatic Lymph Nodes

Performance Measure	B-Mode Sonography	Elastography	Combined
Sensitivity (%)	78 (71–89)	84(60–96)	89 (85–98)
Specificity (%)	82 (72-91)	80 (52–96)	73 (64–82)
Accuracy (%)	86 (74–92)	81 (72–93)	79.1 (68–92)
Positive predictive value	79 (70–88)	84 (66–94)	70 (61–88)
Negative predictive value	74 (66–83)	80 (58–92)	81 (77–99)

Table-2: Diagnostic Performance of B-Mode Sonography, Elastography and Combined

Color elastogram of palpable lymph node	% of blue area	Elastoscore[16,17]
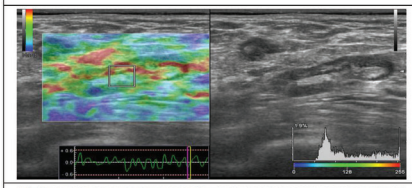	6.2	1
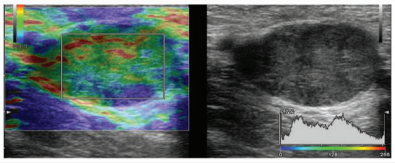	36.7	2
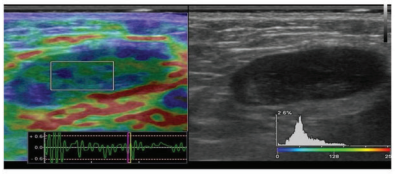	56.4	3
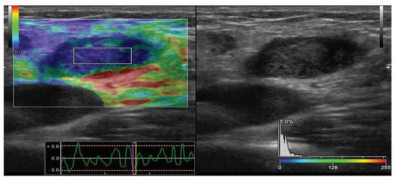	98.9	4

Figure-2: Features of lymphnode of sono-elastgraphy with color elastogram and elastography score

statistically significant differences between mean values, we used Student t-test and X^2 test. All standard calculations for the sensitivity, specificity, positive predictive value, negative predictive value, accuracy and receiver operating characteristic curve analysis were performed.

RESULT

A total of 29 patient's representing all stages of Carcinoma penis undergone sono-elastography of both the groins. Five of these patients had cN1 (clinically palpable) node in both the groins. In total 34 lymph nodes were examined, and there findings was correlated with the pathologic outcome of trucut needle biopsy. Nineteen (55.44%) lymph nodes were metastatic and fifteen (44.11%) were reactive on pathology.

B mode Sonography

The mean size of reactive lymph nodes was 20.075 ± 4.121 mm and metastatic node had 18.46 ± 5.038 mm which was statistically insignificant. Of the 19 metastatic nodes, 15 (78.95%) malignant nodes had > 8mm of short axis diameter and 11(57.9%) had longitudinal to transverse axis ratio of <2. Irregular borders were the characteristic of 13 (68.4%) metastatic lymph node. Abnormal or absent hilum was seen in 17(89.5%) metastatic lymph nodes and 16 (81.25%) nodes with inhomogeneous hilum were malignant. (Table 1) Taking only one of the above mentioned criteria to characterize lymph node as metastatic or reactive, sensitivity and specificity of B mode sonography ranged from 57.9-89.5% and 60-86.7% respectively. Within the above mentioned criteria abnormal or absent hilum has the best sensitivity (89.5%) while short axis diameter has best specificity (86.7%) for metastatic lymph node. (Table1).

Elastography

On evaluating strain ratio for differentiating metastatic and reactive lymph node, seventeen (89.47%) of the metastatic nodes had strain ratio more than 2.3 whereas 12 (80.0%) of the reactive nodes had ratio of less than 2.3 (Figure 1).

Elastography score calculated from the strain elastogram was >2 for sixteen (84.2%) of the metastatic lymph node compared to only three (15.8%) for reactive lymph node. Table 1 shows the distribution of lymph node according to elastography score (Figure 2). On comparision with histopathology the sensitivity and specificity of elastography score for metastatic lymph node was 84% and 80% respectively. The outcome of this study shown as a flow chart (Figure 3)

For combined evaluation of B mode ultra-sonography and elastography, combined score was calculated as; short axis diameter (<8mm score 1and >8mm score2), long to short axis diameter ratio (>2 score 1 and <2 as score 2), echogenicity of cortex (homogenous score 1 and inhomogenous score 2), presence of hilum (present score 1 and abnormal or absent score 2) and margins of lymph node (regular score 1 and irregular as score 2). Similarly strain elastogram was given score of 1 to 4 as discussed previously. A statistically supported cutoff line between reactive and metastatic was set between 8 and 9, depending on best accuracy. Score of 6-8 were determined to be reactive and score of 9-14, metastatic. After calculation of combined score as described above, overall sensitivity and specificity and accuracy for B mode ultrasound score, elastography score and there combination was 78%, 82%, 86%; 84%, 80%,81% and 89%,73%, 79% respectively in reference to tru cut needle biopsy. (Table 2).

Evaluation (on basis of B mode score and elastography score)

The ROC curves for B mode, elastography, and the combined evaluation in the differentiation of reactive and metastatic lymph nodes are shown in Figure 4. The areas under the curves for Bmode sonography, elastography, and

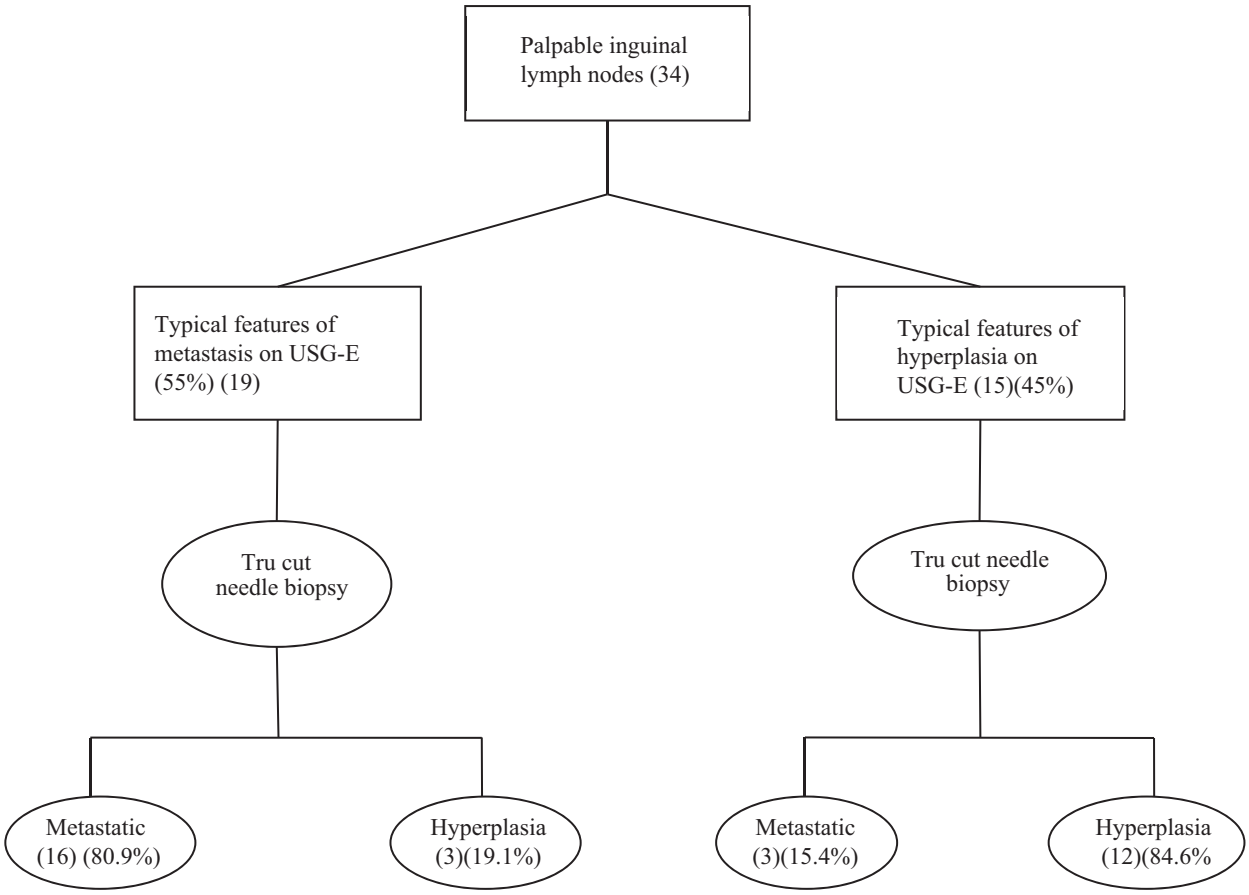

Figure-3: Schematic flowchart of the study (elastography score)

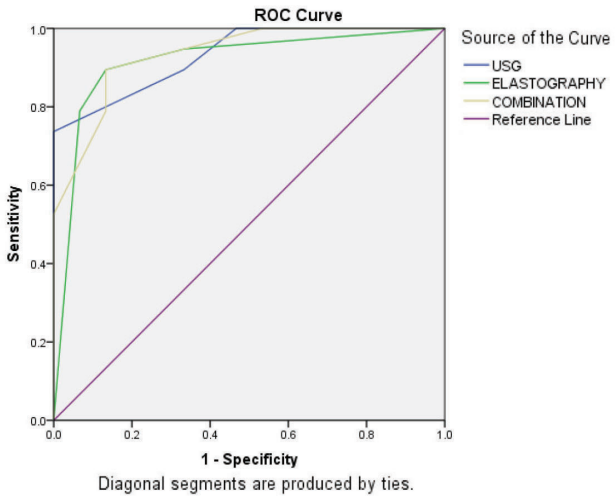

Area Under the Curve

Test Result Variable(s)	Area	Std. Error[a]	Asymptotic 95% Confidence Interval	
			Lower Bound	Upper Bound
USG	.911	.040	.853	1.000
Elastography	.898	.054	.809	1.000
Combination	.933	.041	.884	1.000

The test result variable(s): USG, elastography, combination has at least one tie between the positive actual state group and the negative actual state group. Statistics may be biased.

a. Under the nonparametric assumption

b. Null hypothesis: true area = 0.5

Figure-4: ROC curve with area under curve for B mode ultrasonography (USG), elastography and their combination

the combined evaluation were 0.911, 0.898, and 0.933, respectively. Figure 5 shows results of Sono-Elastography according to T stage of disease.

DISCUSSION

In era of ever-changing technology there is movement towards minimal invasive approach. It is best for patient to have correct diagnosis in hand before undergoing any surgical procedure reducing the overall cost of treatment. Sensitivity and specificity of ultrasonography was 95 and 65 respectively[16] Very few studies are available for inguinal staging with CT scan. Study by Horenblas et al[17] had only 14 subjects with sensitivity of 36% and specificity of 100%. MRI with lymhotrophic nano-particals furromuxtron -10 has high sensitivity (96%) and specificity (100%) in a study by Tabatabei et al[18] in there series of 7 patients. However, ferrumoxtran-10 is not approved by the US Food and Drug Administration (FDA); hence it is currently unavailable. Study by Scher et al[19] while evaluating primary lesion and inguinal lymphadenopathy with FDG[18] PET had sensitivity of 80% for metastatic lymph node.

Keeping longitudinal to transverse axis (L/T) ratio of more than 2 Krishna et al[16] found sensitivity, specificity and positive predictive value of 81%, 69% and 60% respectively while in our study results were 57.89%, 60% and 64.71% respectively.

On evaluating inguinal nodes for metastasis taking short axis diameter of 8mm Krishna et al[16] reported sensitivity

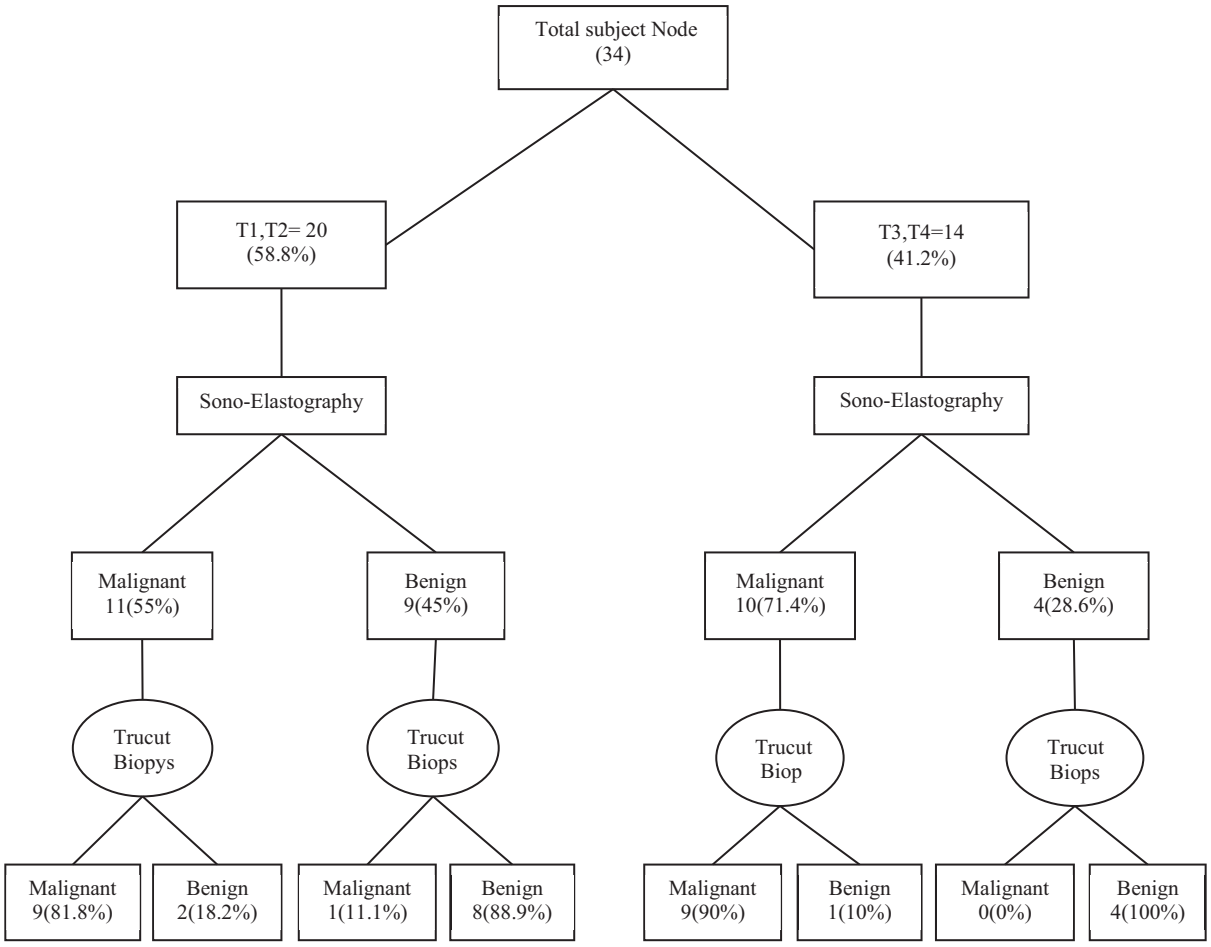

Figure-5: Results of Sono-Elastography according to T stage of disease

of 81% and specificity 69%. In present study keeping same parameters sensitivity, specificity and positive predictive value is 79.0%, 86.24% and 88.24% respectively.

The hilum is the site with initial deposition of malignant cells leading to array of hilum abnormality. Hence, the presence or absence of echogenic hilum should not be the sole criterion used in the diagnosis of metastatic disease.[20] In present study metastatic node had sensitivity, specificity and diagnostic accuracy of 89.5%, 80.0% and 88.6% respectively when taking hilum abnormalities into consideration which is comparable to Alam et al[15] having sensitivity of 88.7%, specificity of 81.3%.

Very few studies have evaluated lymph node borders. Ahuja et al[21] and Ying et al[22] evaluated lymph node borders as sharp and unsharp. In our study, we evaluated regular and irregular lymph node borders as a criterion of reactive and metastatic lymph nodes, respectively, that showed 72% accuracy.

The strain ratio, a semi quantitative measurement, is defined as the proportion of strain between target and reference tissue. Few studies have shown that the strain ratio is useful for differentiating benign and malignant lesions in breast masses and cervical lymph nodes.[11,23] Although there is controversy over selection of the reference tissue. In our study, we used surrounding fat tissue as reference and strain ratio of greater than 2.3 was useful for distinguishing metastatic inguinal lymph nodes with sensitivity, specificity and positive predictive value of 89.3%, 80% and 85% respectively. However, further studies will be required to verify the reference tissue and reproducibility of the strain ratio.

Elastography score was calculated according to 4 score elastography classification by Furkawa et al.[12] Study by Zang et al[24] on evaluating superficial lymphadenopathy from multiple sites had sensitivity, specificity and accuracy of 74.4%, 97.1% and 84.5%. In similar study by Teng et al[6] on cervical nodes had sensitivity, specificity and accuracy of 88.4%, 35.1% and 66.3%.Our study has sensitivity, specificity and accuracy of 82%, 76% and 81% for metastatic lymph node taking score more than 2.

The result of our study shows near equal sensitivity of elastography and B mode ultrasound. On combination of two modalities sensitivity improves but there is no significant change in specificity. The results with strain ratio are encouraging which needs to be replicated in other study before application.

To our knowledge, this is the first English language study evaluating elastography individually and in combination with Bmode sonography to differentiate reactive versus metastatic inguinal lymph nodes in cases of carcinoma penis. Both the modalities provide nearly equal sensitivity with B-mode sonography providing better specificity. Combining both the modalities significantly improves the sensitivity for metastatic nodes. There are many limitations

of this study. Interobserver and intraobserver variability in strain elastography still need to be analyzed. We compared our results by taking the histological outcome of trucut needle biopsy as the gold standard. We used lymph node as our units, not the patient and only included superficial and prominent lymph node in our study. Role in nonpalpable nodes still needs to be evaluated. The score calculated for combined evaluation has not been validated. Strain ratio cut off taken by us need further studies before confirmation. A sample size of our study is small.

CONCLUSION

In conclusion, US elastography appears to be a promising tool for differentiating benign and malignant lymph nodes. However, some unresolved issues remain. Further studies are needed to fully standardize the clinical application of this modality with large sample size at multiple centers.

REFERENCES

1. Wein A, Kavoussi L, Partin A, Peters C. Campbell-Walsh Urology: Tumors of penis.2016;37:847-49.
2. Parkin DM, Whelan SL, Ferlay J, et al. Cancer Incidence in Five Continents. Vol. VIII. IARC Scientific Publications. No. 155. Lyon, France: IARC, 2002.
3. Lont AP, Kroon BK, Gallee MP, et al. Pelvic lymph node dissection for penile carcinoma: extent of inguinal lymph node involvement as an indicator for pelvic lymph node involvement and survival. J Urol 2007;177:947-52.
4. Saisorn I, Lawrentschuk N, Leewansangtong S, et al. Fine-needle aspiration cytology predicts inguinal lymph node metastasis without antibiotic pretreatment in penile carcinoma. BJU Int 2006; 97:1225.
5. Demharter J, Müller P, Wagner T, Schlimok G, Haude K, Bohndorf K. Percutaneous core-needle biopsy of enlarged lymph nodes in the diagnosis and subclassification of malignant lymphomas. Eur Radiol. 2001;11:276-83.
6. Teng DK, Wang H, Lin YQ, et al. Value of ultrasound elastography in assessment of enlarged cervical lymph nodes. Asian Pac J Cancer Prev. 2012;13, 2081-5.
7. Choi JJ, Kang BJ, Kim SH, et al. Role of sonographic elastography in the differential diagnosis of axillary lymph nodes in breast cancer. J Ultrasound Med 2011;30:429–36.
8. Ophir J, Cespedes I, Ponnekanti H, Yazdi Y, Li X.Elastography: a quantitative method for imaging the elasticity of biological tissues. Ultrason Imaging 1991; 13:111–134.
9. Ophir J, Garra B, Kallel F, et al. Elastographic imaging. Ultrasound Med Biol 2000; 26[suppl 1]:S23–9.
10. Lyshchik A, Higashi T, Asato R, et al. Thyroid gland tumor diagnosis at US elastography. Radiology 2005; 237:202–11.
11. Lyshchik A, Higashi T, Asato R, et al. Cervical lymph node metastases: diagnosis at sonoelastography—initial experience. Radiology 2007; 243: 258–67.
12. Furukawa MK, Fujita Y, Kubota A, Furukawa M, Hanamura H. Diagnosis of cervical lymph node metastasis of head and neck squamous cell carcinoma - usefulness of Power Doppler ultrasonography and elastography. Medix 2007; Suppl: 20-23.
13. Furukawa MK, Kubota A, Hanamura H, Furukawa M. Clinical application of real-time tissue elastography to head and neck cancer—evaluation of cervical lymph node metastasis with realtime tissue elastography. [abstract] Nippon Jibiinkoka Gakkai Kaiho 2007; 110: 503-505.
14. Lo WC, Cheng PW, Wang CT, Liao LJ. Real-time ultrasound elastography: an assessment of enlarged cervical lymph nodes. Eur Radiol 2013;23:2351-2357.
15. Alam F, Naito K, Horiguchi J, Fukuda H, Tachikake T, Ito K. Accuracy of sonographic elastography in the differential diagnosis of enlarged cervical lymph nodes: comparison with conventional B-mode sonography. AJR Am J Roentgenol 2008; 191:604–610.
16. Krishna R, Sistla S, Smile R, Krishnan R. Sonography: An Underutilized Diagnostic Tool in the Assessment of Metastatic Groin Nodes. Journal of clinical ultrasound 2008;36:212-17.
17. Horenblas S, Van Tinteren H, Delemarre JF, et al. Squamous cell carcinoma of the penis: accuracy of tumor, nodes and metastasis classification system, and role of lymphangiography, computerized tomography scan and fine needle aspiration cytology. J Urol 1991;146:1279–83.
18. Tabatabaei S, Harisinghani M, McDougal WS.Regional lymph node staging using lymphotropic nanoparticle enhanced magnetic resonance imaging with ferumoxtran-10 in patients with penile cancer. J Urol 2005;174:923–7.
19. Scher B, Seitz M, Reiser M, et al. 18F-FDG PET/CT for staging of penile cancer. J Nucl Med 2005;46:1460–5.
20. Evans RM, Ahuja A, Metreweli C. The linear echogenic hilus in cervical lymphadenopathy—a sign of benignity or malignancy? Clin Radiol 1993;47:262-4.
21. Ahuja A, Ying M. An overview of neck node sonography. Invest Radiol 2002; 37:333–42.
22. Ying M, Ahuja A, Brook F. Sonographic appearances of cervical lymph nodes: variations by age and sex. J Clin Ultrasound 2002; 30:1–11.
23. Cho N, Moon WK, Kim HY, Chang JM, Park SH, Lyou CY. Sonoelastographic strain index for differentiation of benign and malignant nonpalpable breast masses. J Ultrasound Med 2010; 29:1–7.
24. Zhang YR, Lv Q, Yin YH, et al. The value of ultrasound elastography in differential diagnosis of superficial lymph nodes. Front Med China 2009;3:368–74.

Source of Support: Nil; **Conflict of Interest:** None

Submitted: 01-11-2019; **Accepted:** 30-11-2019; **Published:** 26-12-2019