Cadaveric Study of Renal Artery Variations

S.N. Rajakumari[1], K. Arumugam[2]

ABSTRACT

Introduction: Cadaveric study of renal artery variations, to make aware the clinician, in order not to jeopardize valuable nephrons in the era of rampant MRD. Study aimed to record the presence of Extra Renal Arteries (ERA) in adult human cadaveric kidneys.

Material and Methods: This study was done in embalmed cadavers in Tirunelveli Medical College- Anatomy department between 2015 and 2018.

Results: We found EBRA in10%, accessory renal arteries in 30% and aberrant renal arteries in 22% of cadavers studied.

Conclusion: with the advent of laparoscopic renal surgeries and renovascular interventions, we hope our study of ERA will be of great benefit.

Keywords: Cadaveric, Renal Artery Variations

INTRODUCTION

Anatomical nomenclatures describing the accessory renal artery like-supernumerary, multiple, aberrant, additional, and so on is confusing and controversial.[1,2] Graves suggested the term accessory to an artery arising from the aorta in addition to the main renal artery and aberrant means the renal arteries arising from sources other than the aorta.

Post interventional complications and risk of nephron loss is more in patients with multiple renal arteries when compared to kidneys having single renal artery. Accessory renal artery usually arises from aorta from a separate from main renal ostium and goes into the hilum. Aberrant renal artery has a separate aortic origin but goes to the poles.[3] Early branching of renal artery is defined as a renal artery that branches within 15 mm distance from renal ostium. Renal arteries arise as lateral branches of aorta at L1 –L2 interval. Extra renal arteries usually arise from abdominal aorta close to the origin of main renal artery. Rarely may they arise from coeliac trunk, SMA, aortic bifurcation or common iliac arteries. Level of origin of renal artery may vary- upper or lower border of L1, L2 or at L3 level. ERA may be accessory or aberrant with an incidence of 27%–30%.[4] Deficiency in the development of lateral splanchnic arteries – mesonephric arteries result in more than one renal artery. One ostium can be obtained during lap donor nephrectomy if early branches are beyond 10 mm distance from the origin of main renal artery.[5] Otherwise renal arteries have to be constructed on the back table or separate renal artery anastomosis to the recipient need to be performed. With the advent of lap donor nephrectomy, lap nephron sparing surgery, renovascular surgical and radiological interventions including those for RAS and Catheter based renal sympathetic denervation and repair of aortic aneurysm, for a few to mention, prior mapping of renal arteries is beneficial.

Study aimed to investigate the presence of ERA (Accessory / Aberrant) and to look for early branching renal artery and to estimate the distance at which it branches from the main renal ostium

This study was done at TVMC – study period January 2015 – December 2018. 40 kidney specimens from 20 adult human embalmed cadavers were studied in the department of Anatomy by dissection method and morphometric data of dissected specimens were obtained using Vernier caliper.

Renal arteries were dissected and explored meticulously to study the morphological and numerical variation. Arteries originating from the abdominal aorta and supplying the kidney were defined as renal artery. Artery originating from the renal artery before hilum and supplying the kidney were defined as pre-hilar artery. Variance of renal artery including accessory and aberrant renal arteries are studied. We also noted early branching of renal artery which is important in donor nephrectomy.

RESULTS

We studied 40 cadaveric kidneys for accessory renal artery, aberrant renal artery and early branching renal artery. Out of 40 specimens studied, 4 of them (10%) of the cadaveric kidneys showed renal arteries with early branching. (Figure

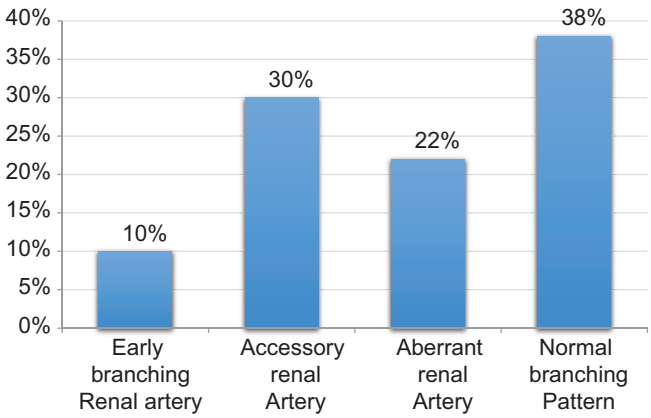

Figure-1: Early branching arteries and extra renal arteries

[1]Senior Assistant Professor, Department of Anatomy, Tirunelveli Medical College and Hospital, Tamilnadu, [2]Senior Assistant Professor, Department of Anatomy, Tirunelveli Medical College and Hospital, Tamilnadu, India

Corresponding author: Dr. K. Arumugam, Senior Assistant Professor, Department of Anatomy, Tirunelveli Medical College and Hospital, Tamilnadu, India

How to cite this article: S.N. Rajakumari, K. Arumugam. Cadaveric study of renal artery variations. International Journal of Contemporary Medical Research 2019;6(12):L1-L3.

DOI: http://dx.doi.org/10.21276/ijcmr.2019.6.12.3

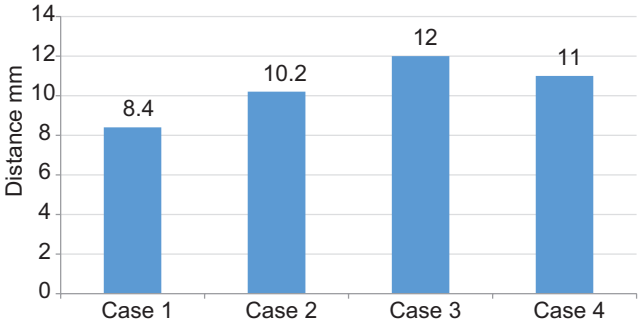

Figure-2: Distance from main renal main ostium

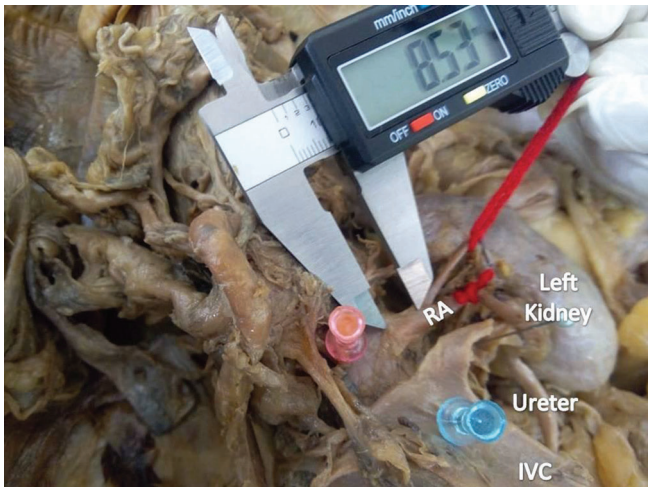

Figure-3: Left kidney with early braching of renal artery-Measuring the distance from origin

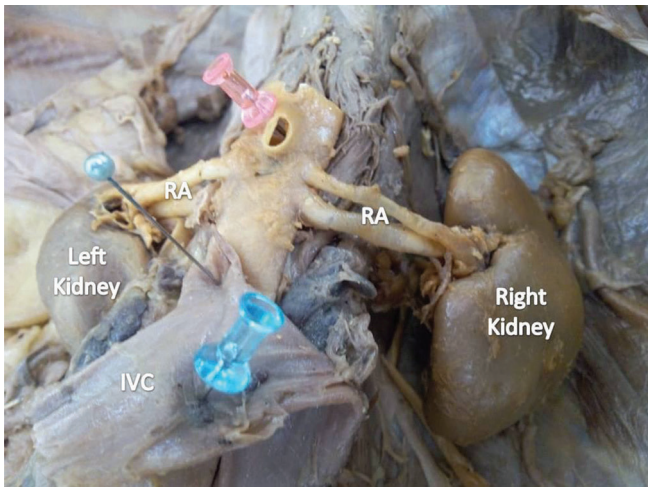

Figure-4: Both kidneys with double renal arteries

1) The average distance from main renal ostium was 10.35mm. (Figure 2) Out of 40 specimens studied 12 of them (30%) had accessory renal arteries, 10 of them (22%) had aberrant renal arteries which originated from aorta and reached either the upper or lower pole of the kidney. 43% of arteries reached upper pole and 57% of arteries reached lower pole. (Figure 3 to 7)

DISCUSSION

Renal arteries arise as lateral branches of aorta at L1 – L2 interval. Aberrant or accessory arteries have been of interest to the clinicians for some years, mainly because

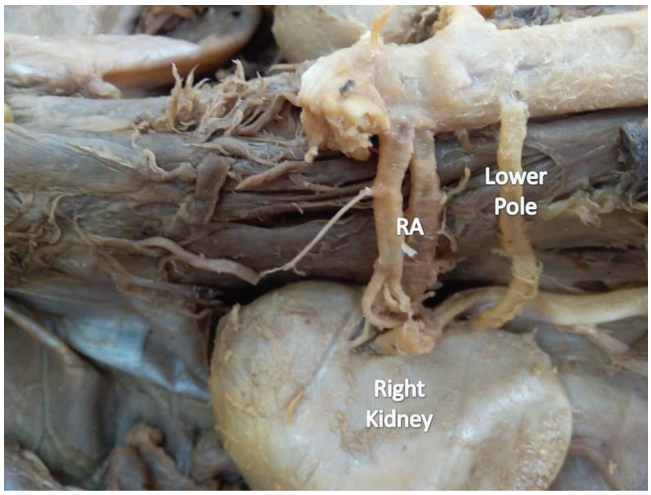

Figure-5: Right kidney with double renal artery and lower polar artery

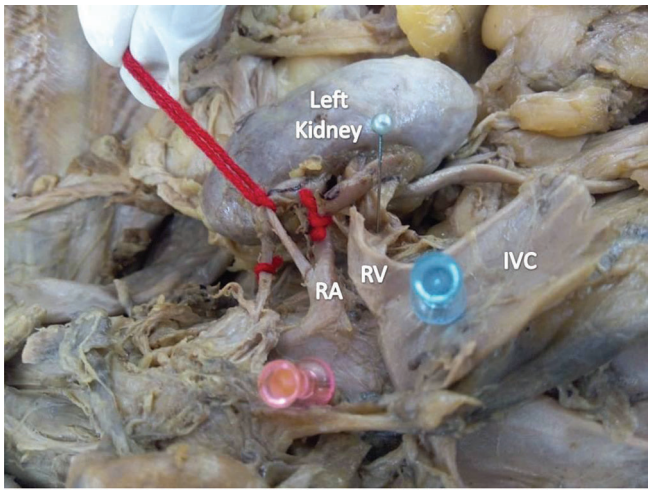

Figure-6: Left kidney with early branching of renal artery

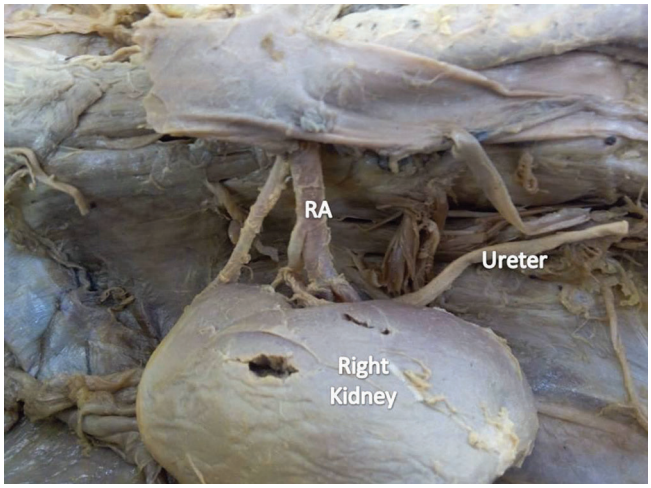

Figure-7: Right Kidney with polar artery

of the possible part the vessel may play in the causation of hydronephrosis. However, judging by the many descriptions of these vessels in the literature, it is evident that there is no established criterion for aberrance; the term has been applied equally to an additional artery in the renal pedicle, or to a vessel entering the kidney at either pole, whether derived from the main renal artery, from the aorta or from a branch

of the aorta.[6] Rarely may they arise from coeliac trunk, SMA, aortic bifurcation or common iliac arteries. Level of origin of renal artery may vary- upper or lower border of L1, L2 or at L3 level. ERA may be accessory or aberrant with an incidence of 27 – 30% Deficiency in the development of lateral splanchnic arteries – mesonephric arteries result in more than one renal artery. Presence of additional renal artery is probable when the main renal artery has a diameter of less than 4.15 mm. The incidence of EBRA is 10 -12%.

Saldarriaga et al. analyzed the number of accessories and found single accessory renal artery in 22.3% and two in 2.6% of the population, of which, 52.4% of specimens arose from the lateral aspect of the abdominal aorta and entered the kidney through its hilum.[7] Kara et al. found the frequency of single, double, or more accessory renal arteries in 17.6%, 2.3%, and 1% respectively.[8]

Laparoscopic donor nephrectomy can be safely performed in the donor with multiple renal arteries with equivalent transplant results to those kidney grafts with a single renal artery. The technique for reconstruction of multiple renal arteries has also been established with satisfactory results.[9-12] It is essential to interpret CTA accurately prior to surgery and identify the excess renal artery during surgical dissection. One ostium can be obtained during lap donor nephrectomy if early branches are beyond 10 mm distance from the origin of main renal artery. Otherwise renal arteries have to be constructed on the back table or separate renal artery anastomosis to the recipient need to be performed. With the advent of lap donor nephrectomy, lap nephron sparing surgery, renovascular surgical and radiological interventions including those for RAS and Catheter based renal sympathetic denervation and repair of aortic aneurysm, for a few to mention, prior mapping of renal arteries is beneficial. In our study we found EBRA in 10%, accessory renal arterery in 30% and aberrant renal artery in 22% of cadaveric specimens.

CONCLUSION

With the advent of laparoscopic renal surgeries, renovascular surgical and radiological interventions, we hope our study of ERA will be of benefit to clinicians.

REFERENCES

1. Standring S, ed. In: Gray's Anatomy. The Anatomical Basis of Clinical Practice 40th ed. London: Elsevier Churchill Livingstone; 2008:1231.
2. Ames SA, Krol M, Nettar K, et al. Assessment of kidneys by magnetic resonance angiography and venography: accuracy and impact on outcomes. Am J Transplant. 2005;5:1518–1528.
3. Graves FT. The aberrant renal artery. J Anat. 1956;90:553–558.
4. Munnusamy K, Kasirajan SP, Gurusamy K, et al. Variations in Branching Pattern of Renal Artery in Kidney Donors Using CT Angiography. J Clin Diagn Res. 2016;10:AC01-3.
5. He B, Hamdorf J. Clinical importance of anatomical variations of renal vasculature during laparoscopic donor nephrectomy. OA Anatomy. 2013;1(3).
6. Graves FT. The aberrant renal artery. J Anat. 1956; 90: 553–558.
7. Saldarriaga B, Perez AF, Ballesteros LE. A direct anatomical study of additional renal arteries in a Colombian mestizo population. Folia Morphol. 2008;67:129–134.
8. Kara A, Kurtoglu Z, Oguz I ˙dt., et al. Two accessory renal arteries with histological properties. Turk J Med Sci. 2006;36:133–138.
9. Husted TL, Hanaway MJ, Thomas MJ, Woodle ES, Buell JF. Laparoscopic living donor nephrectomy for kidneys with multiple arteries. Transplant Proc. 2005;37629-30.
10. Kok NF, Dols LF, Hunink MG, Alwayn IP, Tran KT, Weimar W. Complex vascular anatomy in live kidney donation: imaging and consequences for clinical outcome. Transplantation 2008;851760-5.
11. Chedid MF, Muthu C, Nyberg SL, Lesnick TG, Kremers WK, Prieto M. Living donor kidney transplantation using laparoscopically procured multiple renal artery kidneys and right kidneys. J Am Coll Surg. discussion 152 2013;217144-52.
12. He B, Mou L, Mitchell A, Delriviere L. Meticulous use of techniques for reconstruction of multiple renal arteries in live donor kidney transplantation. Transplant Proc. 2013;451396-8.

Source of Support: Nil; **Conflict of Interest:** None

Submitted: 27-02-2019; **Accepted:** 30-03-2019; **Published:** 11-12-2019