

Classical Closed Technique by Veress Needle Insertion Versus Direct Trocar Insertion in the Creation of Pneumoperitoneum in Various Laparoscopic Surgeries

Umer Mushtaq¹, Ghulam Mohammad Naikoo², Ishfaq Ahmad Gilkar³, Javid Ahmad Peer⁴, Waseem Ahmad Dar⁵, Yaser Hussain Wani⁶

ABSTRACT

Introduction: Laparoscopy has revolutionised Surgery with its widespread acceptance as predominantly minimally invasive to intraabdominal surgical procedures. Creation of pneumoperitoneum is indispensable primary step of the procedure as it allows creation of operative field. It can be achieved by various techniques viz Classical open method as described by Hasson. The aim of the study was to ascertain safety of direct trocar insertion in creation of pneumoperitoneum in laparoscopic surgeries and adopt the same as an alternative to veress technique.

Material and methods: A total of 576 patients were included in the study, Group A comprised of patients in whom we created pneumoperitoneum by classical veress needle insertion and included 327 patients. Group B comprised of 249 patients in whom we created pneumoperitoneum by direct trocar insertion method.

Results: The mean age of patients was 47.54 years SD 11 with a male female ratio of 1:1.56. Laparoscopic cholecystectomy (52.08%) was most frequent followed by laparoscopic appendectomy (13.02%). Group A patients witnessed omental emphysema (7.95%) as commonest complication followed by preperitoneal insufflation (5.19%) while as the most common complication in group B was omental emphysema (0.81%). Port site infection (4.28%) and subcutaneous emphysema (3.36%) predominated in group A and port site infection (1.2%) and seroma formation (1.2%) were common in group B.

Conclusion: There are many methods to create pneumoperitoneum. The closed technique modified to direct trocar insertion versus classical method by Veress were compared in patients undergoing laparoscopic procedures at SMHS hospital for a period of one and a half year. The results are fascinating as the modified technique overshadows its classical version in terms of feasibility, efficacy and consumption of time.

Keywords: Laparoscopy, Pneumoperitoneum, Veress

procedure as it allows creation of operative field. It can be achieved by various techniques viz Classical open method as described by Hasson, Classical closed method by Veress needle, direct trocar insertion and by visual entry method with optical needle or a trocar. The direct trocar insertion is also a modified closed technique with advantage of bringing down steps in blind from 3 (needle insertion, insufflation and trocar insertion) to single step (trocar introduction).⁴⁻⁷ The unfortunate part of the laparoscopy is the risk associated with initial entry depending upon any of the above methods adopted. Complications like bowel perforation, major intraabdominal vessel injury or ventral abdominal wall vessel injury are the mostly encountered but very rarely. Bowel perforates in about 0.1% to 0.5% and vessel injury occurs in about 0.01% to 1%.⁸⁻¹⁰

This study included all the patients admitted for routine elective laparoscopic surgeries, we compared classical closed method of creating pneumoperitoneum by a veress needle with modified closed technique of creating pneumoperitoneum by direct trocar insertion among 576 patients who underwent laparoscopic surgery for various surgical disorders.

The aim of the study was to ascertain safety of direct trocar insertion in creation of pneumoperitoneum in laparoscopic surgeries and adopt the same as an alternative to veress technique, time taken to create pneumoperitoneum (from skin incision to introduction of camera scope) and its

¹Senior Resident, Department of General Surgery, Government Medical College, Srinagar, J&K, ²Consultant, Department of General Surgery, Government Medical College, Srinagar, J&K, ³Senior Resident, Department of General Surgery, Government Medical College, Srinagar, J&K, ⁴Senior Resident, Department of General Surgery, Government Medical College Srinagar, J&K, ⁵Junior Resident, Department of General Surgery, Government Medical College, Srinagar, J&K, ⁶Junior Resident, Department of General Surgery, Government Medical College, Srinagar, J&K, India

Corresponding author: Ishfaq Ahmad Gilkar, Government Medical College, Srinagar, Kashmir, India

How to cite this article: Umer Mushtaq, Ghulam Mohammad Naikoo, Ishfaq Ahmad Gilkar, Javid Ahmad Peer, Waseem Ahmad Dar, Yaser Hussain Wani. Classical closed technique by veress needle insertion versus direct trocar insertion in the creation of pneumoperitoneum in various laparoscopic surgeries. *International Journal of Contemporary Medical Research* 2019;6(7):G9-G13.

DOI: <http://dx.doi.org/10.21276/ijcmr.2019.6.7.34>

INTRODUCTION

Laparoscopy has revolutionised Surgery with its widespread acceptance as predominantly minimally invasive to intraabdominal surgical procedures. With its advent to lighter our toil comes a responsibility to ensure safety of the patient. A massive record of over 50% of the operative complications occur during creation of pneumoperitoneum or in other words on initial entry to abdomen.¹⁻³ Creation of pneumoperitoneum is indispensable primary step of the

complications.

MATERIAL AND METHODS

The study was undertaken in the department of general surgery and allied of SMHS Hospital, an associated hospital of Government Medical College Srinagar between December 2016 to July 2018. The study was prospective observational in design. Patients admitted for routine elective laparoscopic surgeries were included in the study. The patients were evaluated on opd basis beforehand and follow up in the postoperative period continued for one month for each patient. Records of the age, sex, type of surgery done, intraoperative complications, operative time, postoperative complications were noted and results were subjected to statistical analysis. A total of 576 patients were included in the study and grouped in to group A and group B. Group A comprised of patients in whom we created pneumoperitoneum by classical veress needle insertion and included 327 patients. Group B comprised of 249 patients in whom we created pneumoperitoneum by direct trocar insertion method.

As both of these procedures are routinely performed in our hospital so ethical clearance was not required.

Veress needle insertion method: With patient under general anaesthesia, a small 5mm incision in the skin was made in the skin just infraumbilical. Veress needle was introduced into the incision through the layers of ventral wall after properly lifting the ventral abdominal wall at or near the umbilicus. Position of the needle tip was confirmed in the peritoneal cavity by saline drop and aspiration test. The peritoneal cavity was insufflated with CO₂ until the peritoneal cavity distended with average intraabdominal pressure of about 10 to 12 mmHg or at least 2.5 L to 3 L of gas was introduced.

The trocar was then introduced followed by introduction of camera cope to inspect for any possible injuries. The intended operation was then carried out.

Direct trocar insertion method: In this method, infraumbilical incision is made just over 10 mm in length. Anterior abdominal wall is held up at or near umbilicus and trocar is introduced with graded progression into general peritoneal cavity in a twisting maneuver until peritoneum is felt to have been pierced. The stop cock of the trocar canula is ensured to remain open during insertion to allow air rush in on entry to peritoneum to counter the negative pressure inside potentiated by lifting of anterior abdominal wall thereby decreasing the chances of injury to vital structures. Once the trocar is introduced the camera scope is introduced and the intended operation is carried out.

Time taken from infraumbilical incision to introduction of camera scope was recorded and compared. Immediate intra operative complications and post-operative complication with regard to the techniques involved in creation of pneumoperitoneum.

RESULTS

In our study The mean age of patients was 47.54 years SD 11. The patients in the age group 26-50 years predominated the study (Fig-1) with Female patients outnumbered males with a male female ratio of 1:1.56 (Fig-2). The various surgical operations that were carried out with laparoscopy are shown in Figure 3. Laparoscopic cholecystectomy (52.08%) was most frequent followed by laparoscopic appendectomy (13.02%). The others included Laparoscopic inguinal and incisional hernia repairs with TAPP (10.93%) and IPOM (6.94%), laparoscopic hepatic hydatid cystectomy (4.16%), diagnostic laparoscopy (7.63%), varicocelelectomy (2.95%)

	Group A	Group B	p- Value
Time taken to create Pneumoperitoneum (In Minutes)	3.94 ± 1.21	1.06 ± 0.3	0.57

Table-1: Showing Time taken to create Pneumoperitoneum

Complications	Group A		Group B		p-Value
Failed pneumoperitoneum	6	1.8%	1	0.40%	0.12
preperitoneal insufflation	17	5.19%	0	0	0.003
Gut Perforation	2	0.61%	1	0.40%	0.72
Mesenteric Injury	4	1.22%	0	0	0.08
Major vessel Injury	0	0	0	0	1
Port site bleeding	5	1.52%	1	0.40%	0.19
Omental injury	13	3.97%	0	0	0.001
Omental emphysema	26	7.95%	2	0.81%	0.0001
Cardiovascular complication	2	0.61%	11	4.42%	0.002

Table-2: Intraoperative complications

Complications	Group A		Group B		p-Value
Hematoma	2	0.61%	0	0	0.2
Seroma	1	0.30%	3	1.20%	0.2
Port site infection	14	4.28%	3	1.20%	0.035
Port Site Echymosis	6	1.84%	0	0	0.03
Subcutaneous Emphysema	11	3.36%	0	0	0.004

Table-3: Post operative complications.

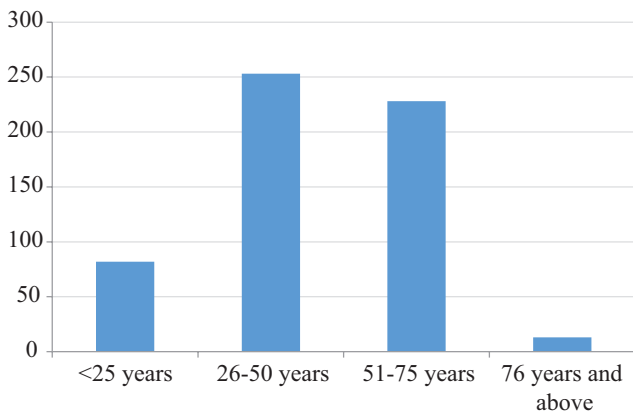


Figure-1: Age distribution

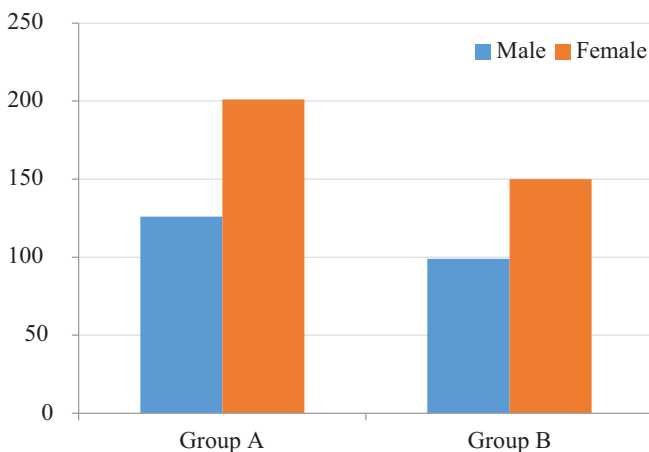


Figure-2: Sex distribution

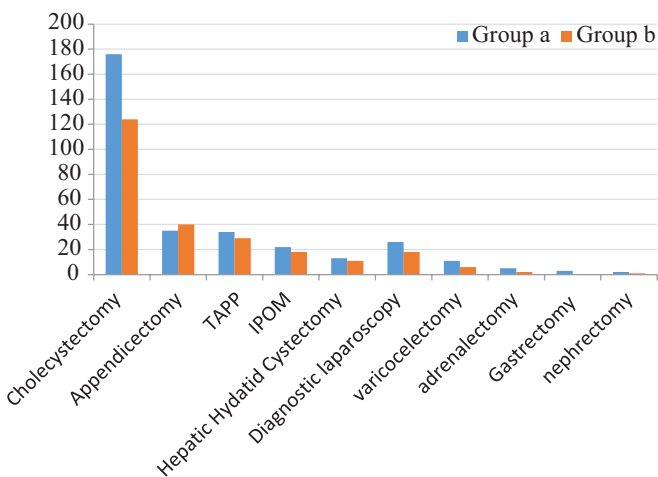


Figure-3: Showing Type of Surgery

and other advanced laparoscopic procedures like gastrectomy (0.52%), nephrectomy (0.52%) and adrenalectomy(1.21%) as shown in Fig 3. the interval between skin incision at umbilicus to introduction of camera scope was recorded. In Group A, time taken from skin incision through insertion of veress needle, its confirmation inside the peritoneal cavity, insufflation and then introduction of trocar cannula, introduction of camera scope took longer than pneumoperitoneum by DTI (direct trocar insertion) method. DTI method was swift from skin incision through direct insertion of trocar, insufflation and introduction of camera

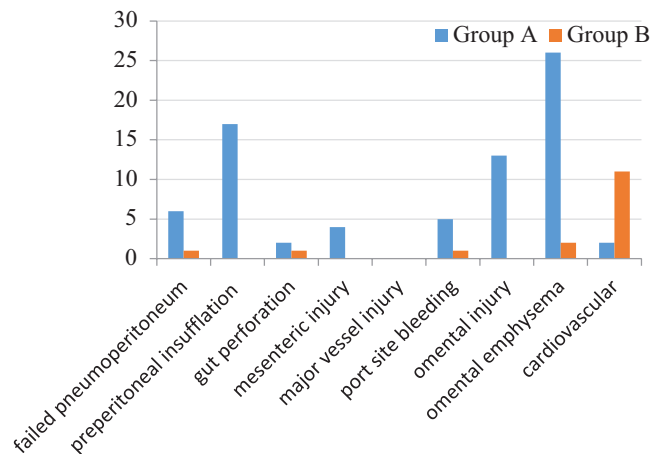


Figure-4: Intraoperative complications

scope as shown in Table 1. Complications arising during procedures were identified and recorded. Group A patients witnessed omental emphysema (7.95%) as commonest complication followed by preperitoneal insufflation (5.19%) while as the most common complication in group B was omental emphysema (0.81%). Gut perforation was 0.61% on group A and 0.40% in group B. The patients were followed up for immediate postoperative complications (Fig-4). Port site infection (4.28%) and subcutaneous emphysema (3.36%) predominated in group A and port site infection (1.2%) and seroma formation (1.2%) were common in group B in the immediate postoperative period (Fig-5).

The patients were followed up for immediate postoperative complications. Port site infection (4.28%) and subcutaneous emphysema (3.36%) predominated in group A and port site infection (1.2%) and seroma formation (1.2%) were common in group B in the immediate postoperative period. In group A Post-operative complications subcutaneous emphysema, port site ecchymosis, port site infection, seroma and hematoma were 11, 6, 14, 1 and hematoma respectively. In group B Post-operative complications subcutaneous emphysema, port site ecchymosis, port site infection, seroma and hematoma were 0, 0, 3, 3 and 0 respectively (table-3).

In our study of 576 patients, The mean age of patients was 47.54 years SD 11. The patients in the age group 26-50 years predominated the study. Number of patients below 25 years of age were 82, in 26-50 were 253, in 51-75 were 228 and number of patients above 76 years were 13 (figure-1).

Female patients outnumbered males with a male female ratio of 1:1.56. males in group A were 126 and in group B were 99. Females in group A were 201 and in group B were 150 respectively (figure-2).

The various surgical operations that were carried out with laparoscopy are shown in Figure 3. Laparoscopic cholecystectomy (52.08%) was most frequent followed by laparoscopic appendectomy (13.02%). In group A the number of patients undergoing cholecystectomy, appendectomy, TAPP, IPOM, hydatid cystectomy, Varicocelelectomy, adrenalectomy, gastrectomy and nephrectomy were 176, 35, 34, 22, 13, 26, 11, 5, 3 and 2 respectively (%). In group B the number of patients undergoing cholecystectomy,

appendicectomy, TAPP, IPOM, hydatid cystectomy, Varicolectomy, adrenalectomy, gastrectomy and nephrectomy were 124, 40, 29, 18, 11, 18, 6, 2, 0 and 1 respectively.

Complications arising during procedures were identified and recorded. Group A patients witnessed omental emphysema (7.95%) as commonest complication followed by preperitoneal insufflation (5.19%) while as the most common complication in group B was omental emphysema (0.81%). In group A number of patients suffering complications as failed pneumoperitoneum, preperitoneal insufflation, gut perforation, mesenteric injury, major vessel injury, port site bleeding, omental injury, omental emphysema and cardiovascular were 6, 17, 2, 4, 0, 5, 13, 26 and 2 respectively. In group B number of patients suffering complications as failed pneumoperitoneum, preperitoneal insufflation, gut perforation, mesenteric injury, major vessel injury, port site bleeding, omental injury, omental emphysema and cardiovascular were 1, 0, 1, 0, 0, 1, 0, 2 and 11 respectively (table-2, figure-4).

DISCUSSION

The creation of pneumoperitoneum is quintessential in performing a laparoscopic surgery. It allows creation of working field centered around an organ in dealing inside the peritoneal cavity. With many techniques in vogue for creating the pneumoperitoneum there is still a longing to evolve to a safe, technically feasible, quick method. First to get adopted was classical open technique by Hasson. Veress techniques was introduced as classical closed method that followed. It was Dingfelder in 1978 who reported a modified version of closed technique of creating pneumoperitoneum with direct trocar insertion which was later described by Copeland et al. in 1983.^{11,12} and according to whom the prerequisite for the technique are adequately relaxed abdominal wall, adequate skin incision and sharp trocars for insertion with ease.

This study was done in the department of general surgery in SMHS hospital, an associated hospital of GMC Srinagar and included 576 patients from December 2016 until July 2018. The mean age of the patients included in the study was 5th decade, 47.54 ± 11 years and female patients outnumbered males in number as shown in figure 1, 2 which cooresponds to age distribution and male:female ratio found in the study done by Mehmet Ali Yerdel et al 1999.¹³ Laparoscopic cholecystectomy (52.08%) was the most frequent procedure done, followed by laparoscopic appendicectomy (13.02%), findings similar to study by K. Theodoropoulou et al¹⁴ (Figure 3).

The mean time taken to create pneumoperitoneum was less in group B (1.06 ± 0.3 mins) than group A (3.94 ± 1.21 mins). Pneumoperitoneum creation by Veress needle insertion, insufflation and trocar introduction takes longer than direct introduction of trocar where in the steps to create pneumoperitoneum are reduced and hence the time. The similar findings were reported by Issam Merdam et al.¹⁵ and Sushma sinha et al.¹⁶ (Table-1). The intra-operative complications (Table-2) encountered in group

A and B included omental emphysema (7.95% vs 0.8%) as predominant complication in group A followed by preperitoneal insufflation (5.19% Vs 0%). Group B patients however predominated in cardiovascular complications like bradycardia (4.42% vs 0.6%) due to rapid insufflation, which had to be managed by atropine or with lowering intra abdominal pressures during procedure. Among the intraoperative 'preperitoneal insufflation, omental emphysema, omental injury and cardiovascular complications were statistically significant. The intraoperative complication rate in group A exceeded those of group B (22.9% vs 6.4%). The post-operative complications (table-3) included subcutaneous emphysema (3.36% vs 0), port site infection (4.28% vs 1.2%), port site echymosis (1.84% vs 0) in group A and B. Similar findings were seen by Issam Merdam et al.¹⁵, Sushma sinha et al.¹⁶, Prieto-Díaz-Chávez E et al.¹⁷, zakerah et al.¹⁸ Among post-operative complications Port site infection, Port Site Echymosis, Subcutaneous Emphysema were statistically significant (Table-3, Figure 4).

CONCLUSION

Laparoscopy is a modern day armour in surgical practice. With its revolutionary patient friendly prospectus, it becomes imperative to explore the process involved with one important step for its commencement in surgical procedures being creation of pneumoperitoneum which allows creation of working space during surgery. There are many methods to create pneumoperitoneum viz classical closed methods by Veress technique, classical open technique by Hasson. The closed technique modified to direct trocar insertion versus classical method by Veress were compared in patients undergoing laparoscopic procedures at SMHS hospital for a period of one and a half year. The results are fascinating as the modified technique overshadows its classical version in terms of feasibility, efficacy and consumption of time.

Acknowledgments

e are really thankful to the head of the department of general surgery Prof. Shaukat Jeelani for his constant help and cooperation in guiding and compiling this manuscript. The authors have no conflicts of interest to declare.

REFERENCES

1. Hashizume M, Sugimachi K. Needle and trocar injury during laparoscopic surgery in Japan. *Surg Endosc* 1997;11:1198–1201.
2. Vilos GA. Laparoscopic bowel injuries: Forty litigated gynecological cases in Canada. *J Obstet Gynecol Can* 2002;24:224–230.
3. Jansen FW, Kolkman W, Bakkum EA, de Kroon CD, Trimbos Kemper TCM, Trimbos JB. Complications of laparoscopy: An inquiry about closed versus open-entry technique. *Am J Ob-stet Gynecol* 2004;190:634–63
4. Lalchandani S, Phillips K. Laparoscopic entry technique—a survey of practices of consultant gynaecologists. *Gynecol Surg* 2005;22:245–249.
5. Kroft J, Aneja A, Tyrwhitt J, Ternamian A. Laparoscopic peritoneal entry preferences among Canadian gynaecologists. *J Obstet Gynaecol Can* 2009;31:641–

- 648.
6. Ahmad G, Duffy JMN, Watson AJS. Laparoscopic entry techniques and complications. *Int J Gynecol Obst* 2007;99:52–55.
 7. Molloy D, Kaloo PD, Cooper M et al. Laparoscopic entry: a literature review and analysis of techniques and complications of primary port entry. *Obstet Gynaecol*. 2002;42:246.
 8. Magrina JF. Complications of laparoscopic surgery. *Clinical Obstetrics and Gynaecology* 2002;45:469-80.
 9. Wind J, Cremers J, van Berge Henegouwen M, Gouma D, Jansen F, Bemelman W. Medical liability insurance claims on entry-related complications in laparoscopy. *Surgical Endoscopy*. 2007; 21:2094-2099.
 10. Rabl C, Palazzo F, Aoki H, Campos GM. Initial Laparoscopic Access Using an Optical Trocar Without Pneumoperitoneum Is Safe and Effective in the Morbidly Obese. *Surgical Innovation*. 2008; 15: 126-31.
 11. Dingfelder JR. Direct laparoscopic trocar insertion without prior pneumoperitoneum. *J Reprod Med*. 1978;21:45–47
 12. Copeland C, Wing R, Huka JF. Direct trocar insertion at laparoscopy: an evaluation. *Obstet Gynecol*. 1983;62:665–669
 13. Yerdel MA, Karayalcin K, Koyuncu A, Akin B, Koksoy C, Turkcapar AG, Erverdi N, Alaçayir I, Bumin C, Aras N. Direct trocar insertion versus Veress needle insertion in laparoscopic cholecystectomy. *Am J Surg*. 1999; 177:247-9.
 14. K. Theodoropoulou, D. R. Lethaby, H. A. Bradpiece, T. L. Lo, A. Parihar. Direct Trocar Insertion Technique: an Alternative for Creation of Pneumoperitoneum. *JSLs* 2008;12:156–158.
 15. Issam Merdan, Sadq Ghleb Kadem, Yaqoob Ayoob Yaqoob. Safety and efficacy of modified open technique as a first laparoscopic entry in comparison with direct trocar entry and veress needle technique. *Bas J. Surg*. 2016;22:15-20.
 16. Sushma Sinha, Surya Malik. Veress needle versus direct trocar entry for laparoscopy: a retrospective study. *IJRCOG* 2019;8:127-130.
 17. Prieto-Díaz-Chávez E, Medina-Chávez JL, González-Ojeda A, Anaya-Prado R, Trujillo-Hernández B, Vásquez C *Acta Chir Belg*. Direct trocar insertion without pneumoperitoneum and the Veress needle in laparoscopic cholecystectomy: A comparative study. 2006;106:541-4.
 18. Zakherah, Mahmoud S. Direct Trocar Versus Veress Needle Entry for Laparoscopy: A Randomized Clinical Trial. *Obstetrical & Gynecological Survey*. 2010;65:307-308.

Source of Support: Nil; **Conflict of Interest:** None

Submitted: 01-06-2019; **Accepted:** 28-06-2019; **Published:** 25-07-2019