

# Cytodiagnosis of Filariasis – A Retrospective Study of 8 Years

Rajib Kumar Mondal<sup>1</sup>, Suman Ghosh<sup>2</sup>

## ABSTRACT

**Introduction:** In India Filariasis is considered to be a major public health problem. India constitutes about 20% of total global burden. Microfilaria are released and circulate in the peripheral blood with nocturnal periodicity. Due to its extremely rarity it is difficult to detect them in routine peripheral blood smears, Fine Needle Aspiration (FNAC) Smears and body fluids. The objective of our study was to emphasise on having a high index of suspicion of filarial infection in any swelling especially in patients from endemic zones. This study also aims to highlight the importance of FNAC as a cheap and effective tool to diagnose microfilaria.

**Material and Methods:** A total of 9590 cases, with lesions in different sites were encountered in this study. The patients underwent thorough clinical examination and routine investigations. The cystic lesions that were included in this study were aspirated. The material centrifuged and smears prepared were stained with Leishman-Giemsa and PAP stain.

**Results:** In this study out of a total of 9590 cases of superficial swellings that were subjected to fine needle aspiration cytology, 11 cases of filariasis were diagnosed on routine FNAC material from various sites. Out of these 11 cases, maximum cases of filariasis were reported in lymph nodes (3 cases), breast swelling (2 cases), followed by scrotal swellings (2 cases), thyroid swellings (2 cases), parotid (1 case) and Pleural (1 case).

**Conclusions:** Filariasis is an uncommon condition and need a high index of suspicion and careful screen of FNA smears especially in asymptomatic patients belonging to endemic zones, so as not to miss this incidental finding especially in patients from endemic areas. This study also highlights the importance of FNAC as a cheap and effective tool to diagnose microfilaria.

**Keywords:** Microfilaria, Scrotal, Lymph Node, Pleural Fluid, Thyroid, Breast, Parotid, FNAC, Cytodiagnosis

For quick diagnosis of these cases FNAC plays a significant part. The disease is transmitted by the Culex mosquito. It caused by two nematodes: *W. bancrofti* and *B. malayi*. Microfilaria are released and circulate in the peripheral blood with nocturnal periodicity. Majority of men have genital disease (most commonly hydrocoele) and women have lymphoedema or elephantiasis of the leg. Filariasis affects the lymphatic system with a predilection for lower limbs, retroperitoneal tissues, spermatic cord, and epididymis.<sup>1</sup> Filaria can affect other sites rarely. Majority of infected individuals are asymptomatic. Small number of cases on microfilaremia at various sites as lymphnode, breast lump, bone marrow, bronchial aspirates, nipple secretion, pleural and pericardial fluid, ovarian cyst fluid and cervico vaginal smear have been reported. Thyroid is another site from which microfilaria has been isolated.

Filariasis is considered to be a major health problem in tropical areas of the world specially in South East Asia.<sup>1</sup>

Microfilaria may remain viable for a long duration in the lymphatics. The disease may remain asymptomatic for years or it may manifest in the form of hydrocele, lymphatic channels or Acute adeno lymphangitis.<sup>1</sup> Due to its extremely rarity it is difficult to detect them in routine peripheral blood smears, Fine Needle Aspiration (FNAC) Smears and body fluids. Demonstration of microfilaria in peripheral blood smear is used for diagnosis of filariasis.

Our aim in this study was to assess the role of FNAC in diagnosis of filariasis in asymptomatic patients having palpable swelling but clinically asymptomatic.

The objective of our study was to emphasise on having a high index of suspicion of filarial infection in any swelling especially in patients from endemic zones. This study also aims to highlight the importance of FNAC as a cheap and effective tool to diagnose microfilaria and also to assess the role of FNAC in diagnosis of filariasis at all possible sites.

## MATERIAL AND METHODS

This study was conducted in the Pathology Department of N.R.S.M.C & H. Total 9590 cases of superficial swellings

<sup>1</sup>Associate Professor, Department of Pathology, <sup>2</sup>Assistant Professor, Department of Pathology, NRS Medical College and Hospital, Kolkata, India

**Corresponding author:** Suman Ghosh, 44 D, Vivekananda Road, Kolkata - 700006, India

**How to cite this article:** Rajib Kumar Mondal, Suman Ghosh. Cytodiagnosis of filariasis – a retrospective study of 8 years. International Journal of Contemporary Medical Research 2019;6(7):G12-G16.

**DOI:** <http://dx.doi.org/10.21276/ijcmr.2019.6.7.26>

## INTRODUCTION

In India Filariasis is considered to be a major public health problem. India constitutes about 20% of total global burden. Microfilaria are released and circulate in the peripheral blood with nocturnal periodicity. Due to its extremely rarity it is difficult to detect them in routine peripheral blood smears, Fine Needle Aspiration (FNAC) Smears and body fluids. India constitutes about 20% of total global burden. Many people are living in areas endemic for lymphatic filariasis Southeast Asia Region. Mostly people requiring chemotherapy live in the South- East Asia Region and the rest in the African Region. In heavy parasitic load they may appear in the blood, urine with chyle and at times in scrotal aspirates. Endemic regions in India includes all over India except few areas in Northern India and Northeast India.<sup>2</sup>

at various sites were subjected to fine needle aspiration cytology. The study was performed in the Pathology Department, N.R.S.M,C.& H during a period of 8 years i.e. 2010-2018. A total of 9590 cases, with age ranging from 10-80 years, having swellings at various sites were included in the present study.

The patients in this study underwent thorough clinical examination and routine investigations. The cystic lesions that were included in this study were aspirated. The material centrifuged and smears prepared were stained with Leishman-Giemsa and PAP stain.

These smears were wet fixed immediately in 95% alcohol and stained by hematoxylin and eosin and Papanicolaou stain. Air dried smears were stained by Leishman- Giemsa(LG) stain. Lesions from unusual sites eg. including lymph nodes, salivary glands, thyroid, pleural fluid and breast have been included in the study. The cases were correlated with relevant history, physical examination findings and other available investigations. FNAC was performed using 23 gauge needle and 10 ml sterile syringe.Smears of the aspirated material and fluid were stained with Leishman Giemsa (LG) stain. Some of the FNAC smears were air dried for Leishman-Giemsa stain and others fixed in 95% ethanol and stained with Papanicolaou (PAP) stain and mounted in DPX & cover slipped. The smears were studied under light microscope. Parameters to be studied were Clinical History,FNAC examination, Laboratory investigations and Treatment records.

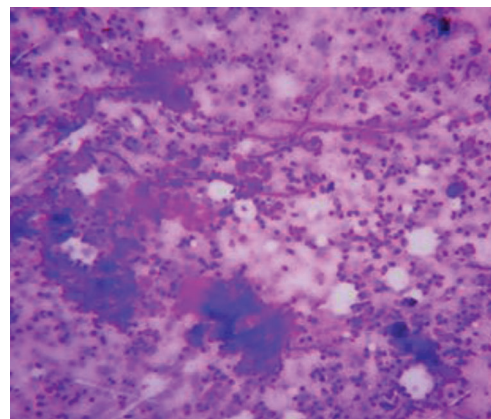
**RESULTS**

At our institution from January, 2010 to January, 2018, a total of 9590 FNAC were performed from palpable swelling. The material centrifuged and smears prepared were stained with Leishman-Giemsa and PAP stain.

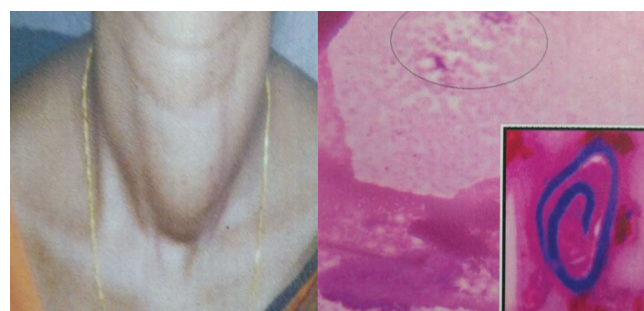This study was showed 11 cases of filariasis diagnosed on routine FNAC material from various sites. Out of these11 cases, maximum cases of filariasis were reported in lymph nodes (3 cases),breast swelling (2 cases), followed by scrotal swellings (2 cases), thyroid swellings (2 cases), parotid (1 cases) and Pleural (1 case). [Table-1]

Smears showed microfilaria had tails that were free from nuclei and were ensheathed, some of which formed curves. The microfilariae had blunt head and pointed tail with a sheath projected slightly beyond the extremities of the embryo. Somatic cells or nuclei appeared as granule in the central axis of the body and were absent at the tip of the tail. All the features distinguish M. bancrofti from the other

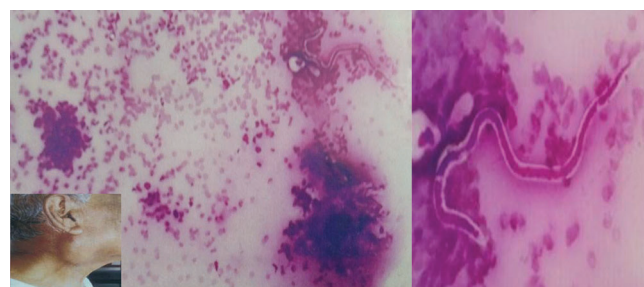
sheathed larvae. The male worm is thinner and smaller than the female worm. Eosinophilia was present in 4 out of 11 cases. Blood smear study of nocturnal venous blood showed microfilaria of W. bancrofti in 1 out of 11 cases accounting for only 0.11% of total FNACs carried out at the center. The prevalence of the disease in males and females were in



**Figure-1:** FNAC from a 42 year old female with a history of lump in the right breast for 3 months measuring about 2.5x2cm in the lower outer quadrant. Smears showing multiple coiled and uncoiled microfilariae along with benign ductal epithelial cells and an inflammatory background.



**Figure-2:** A 40 year old female with a slow painless enlargement of thyroid gland for 3 years.Examination revealed a 3cmx3cm soft to firm swelling in front of the neck which moved on deglutition.No cervical lymphnode enlargement was noted.Thyroid function test was within normal limits.Peripheral smear showed eosinophil count 9%Smears showed microfilaria (encircled)with benign follicular cells of thyroid in monolayered sheets(LG 100x), inset shows higher magnification of microfilaria.

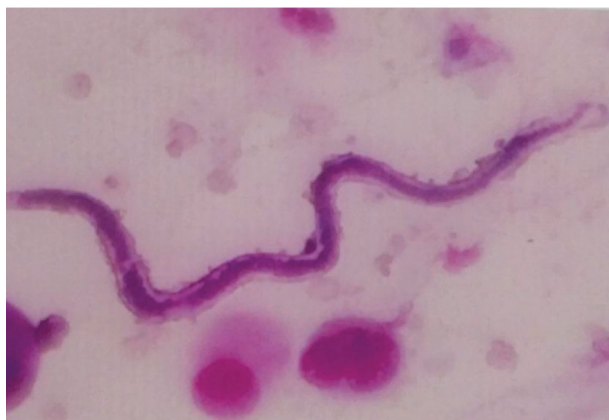

**Figure-3:** a) A 52 year old male with painless swelling over right parotid for 6 months. On examination it was a soft to firm non-tender swelling over right parotid region. No cervical lymph node was palpable (inset). FNAC smears show (LG stain 100x)microfilaria along with salivary duct epithelial cells.b)Microfilaria: W. Bancrofti with sheath larger than body and tail tip free from nuclei.

Sl No.	Site	Number of cases	%
1	Lymph node	3	26
2	Breast swelling	2	18
3	Scrotal swellings	2	18
4	Thyroid	2	18
5	Parotid	1	10
6	Pleural fluid	1	10
Total		11	

**Table-1:**





**Figure-4:** 32 year old male with a low grade fever for 1 month. Examination revealed a dullness on the right side of chest. Chest X-Ray showed a right sided pleural effusion. Diagnostic pleurocentesis showed a straw coloured fluid with a cell count of 3000 / cmm. Pleural fluid smears showing microfilariasis along with reactive mesothelial cells and a few lymphocytes (LG stain, 400x)

the ratio of 1:1. Treatment of microfilariasis was instituted after the cytological diagnosis. On FNAC, clear fluid was aspirated in 6 cases, blood mixed in 4 and purulent in one. Three cases of superficial lymph nodes (2 cervical and 1 axillary) accounted for 30% of the total diagnosed cases. Smears prepared from the aspiration of lymph nodes showed microfilariasis with a background comprising of reactive lymphoid cells. Previous workers reported similar findings in their studies.<sup>5,6,7,12</sup>

Microfilariasis rarely manifest as breast swelling. We had only two cases of breast aspirates. FNAC from a 42 year old female with a history of lump in the right breast for 3 months measuring about 2.5cmx2cm in the lower outer quadrant. Microscopic examination of smears from breast swellings showed multiple coiled and uncoiled microfilariae along with benign ductal epithelial cells and an inflammatory background. [Fig 1]

Two cases of swellings in testicular-scrotal region showed microfilariae. Most of Indian studies have also reported testicular-scrotal region to be quite common for involvement of microfilariasis in Indian scenario. complications of Filariasis in India.<sup>2</sup> *W. bancrofti* commonly involves the lymphatics of spermatic cord in men and may be asymptomatic.<sup>6-8</sup> Noroes et al.,<sup>15</sup> also reported a case of adult worm *W. bancrofti* in scrotal swelling

Colloid was aspirated in two cases of thyroid swellings. The aspirated material showed cytological features suggestive of colloid goiter, while the other showed features of lymphocytic thyroiditis with only an occasional microfilaria. A 40 year old female with a slow painless enlargement of thyroid gland for 3 years. Examination revealed a 3cmx3cm soft to firm swelling in front of the neck which moved on deglutition. No cervical lymph node enlargement was noted. Thyroid function test was within normal limits. Peripheral smear showed eosinophil count 9%. Slides were stained with Leishman-Giemsa stain. Smears showed the presence of microfilarial larvae with benign follicular cells of thyroid in monolayered sheets in the background of colloid. [Fig 2].

A 52 year old male presented with painless swelling over right parotid for 6 months. On examination it was a soft to firm non-tender swelling over right parotid region. No cervical lymph node was palpable. The finding was similar to previous work<sup>14</sup> FNAC smears showed microfilariasis along with salivary duct epithelial cells with microfilariasis: *W. Bancrofti* with sheath larger than body and tail tip free from nuclei. [Fig 3].

A 32 year old male with a low grade fever for 1 month. Examination revealed a dullness on the right side of chest. Chest X-Ray showed a right sided pleural effusion. Diagnostic pleurocentesis showed a straw coloured fluid with a cell count of 3000 / cmm. Centrifuged deposit of pleural fluid aspirate stained with Leishman stain showed presence of several microfilariae of *W. Bancrofti*. Pleural fluid smears showing microfilariasis along with reactive mesothelial cells and a few lymphocytes [Fig 4]

## DISCUSSIONS

In India filariasis is considered to be a public health problem. Most of the infected persons remain asymptomatic. Causative agents include the nematodes *W. bancrofti*, *B. malayi*, *B. timori*, *Loa-loa*, *O. volvulus*, *M. perstans*, *M. ozzardi* and *M. ozzardi*.<sup>1</sup> *W. bancrofti* (95%) and *B. malayi* (5%) are the most common species causing filariasis in India.<sup>5</sup> In definitive hosts adult worms live inside the lymphatic channels. The embryo measures 290 micrometer in length and 6-7 micrometer in thickness. The male measures 2.5-4cm in length by 0.1mm in thickness and the female measures 8-10 cm in length by 0.2-0.3 cm in thickness. In definitive host adult worms live in lymphatic channels of spermatic cord, retroperitoneum, lower extremities and breasts.<sup>4,5</sup>

Microfilariasis was detected only in 0.11% of total cases of FNAC cases (Total 11 cases). It was an incidental finding to detect microfilariasis in the above mentioned sites. Some workers have also studied and reported similar findings of very low incidence of microfilariasis from these superficial sites.<sup>5,6</sup> In our observation, the etiology was *Wuchereria bancrofti* which was similar to the study conducted by national survey in India that estimates of 95% cases caused by the same agent.<sup>21</sup>

Eosinophilia was present in 4 out of 11 cases. Our observations were similar to the finding of other workers,<sup>5,6,21</sup> who reported that filariasis can exist without microfilaremia. Aspirates from lymph nodes showed presence of microfilariasis along with reactive lymphoid cells. Varghese *et al.*<sup>3</sup> and Joshi *et al.*<sup>12</sup> also reported similar cytological features.

Breast swelling is quite an uncommon site for presence and detection of microfilariasis. Microfilariasis in FNAC smears of breast swelling have been reported as incidental finding by only a few authors.<sup>5,6,18,22</sup> The above patients presented with breast lumps with tenderness.

Presence of microfilariasis was seen in 2 cases of scrotal swelling. In asymptomatic cases of microfilariasis in men *W. Bancrofti* commonly resides in the lymphatics of spermatic cord. Noroes *et al.*<sup>15</sup> also reported similar observations. In India scrotal region is reported as a common site of

involvement of microfilaria.<sup>2</sup> Colloid was aspirated in two cases of thyroid swellings. The aspirated material showed cytological features suggestive of colloid goiter, while the other showed features of lymphocytic thyroiditis with only an occasional microfilaria. Varghese<sup>3</sup>, Sodhani<sup>4</sup>, Chowdry.<sup>12</sup> and Yenkeswar<sup>5</sup> reported similar observations. One case of pleural fluid showed microfilaria along with inflammatory cell including eosinophils, lymphocytes and macrophages. The patient presented with massive haemorrhagic non-chylous pleural effusion primarily suggesting tuberculosis, as this the most common cause of pleural effusion in India.<sup>11,12</sup> There was no co existing malignancy, which is the most common cause of haemorrhagic pleural effusion.<sup>11,12</sup> The subsequent extensive search for microfilaria in blood did not yield any result. Other workers have also reported microfilaria detection from these sites.<sup>16,17</sup> Similar finding was also observed by Sivakumar, et al.<sup>13</sup> Microfilaria probably appear in tissue fluids and exfoliated surface material due to lymphatic obstruction. The host immune response directed against the parasite lying in different lymphatic vessels appears to be the major factor in determining the clinical presentation.

Adherent inflammatory cells to microfilariae was present in 2 out of 11 cases. Cell adherence was reported by Pandit *et al.*<sup>16</sup> and also by Walter *et al.*<sup>19</sup> Degenerated microfilaria and coiled larvae were also seen surrounded by inflammatory cells.

New techniques like Filaria antigen detection tests, PCR, FISH are specific but highly expensive and available at specialised centres and therefore out of reach for many people. They are mostly used when there is a prior suspicion of tissue filariasis.

## CONCLUSION

In conclusion, filariasis is an uncommon condition and need a high index of suspicion and careful screen of FNA smears especially in asymptomatic patients belonging to endemic zones, so as not to miss this incidental finding especially in patients from endemic areas. This study also highlights the importance of FNAC as a cheap and effective tool to diagnose microfilaria and as such is very important in the management of these cases, avoiding unnecessary surgical intervention in many of them. Filariasis should be considered a differential diagnosis of swelling at any site. Although filariasis incidence is quite high, in FNAC microfilaria is an uncommon finding. FNAC smears has be thoroughly examined because one can diagnose filariasis within a short time, even in situations where the clinician has not suspected the disease. Early diagnosis by demonstration of parasite can reduce significant morbidity, in due course of the disease before lymphatic filariasis sets in, by institution of specific treatment. A simple procedure like FNA helpful to detect the hidden burden of microfilaria guiding proper management and sparing unnecessary investigations.

## REFERENCES

1. Faust EC, Russell PF, Jung RC. Craig and Faust's Clinical Parasitology, 8th ed. Philadelphia: Lea &

Febiger; 1970.

2. Park K, Lymphatic Filariasis: Park's textbook of preventing and social medicine 2013 22nd Edition Jabalpur Banarasidas Bhanot: 245-50.
3. Varghese R, Raghuvver CV, Pai MR, Bansal R, Microfilariae in cytologic smear: A report of six cases Acta Cytol 1996;40:299-301.
4. Sodhani P, Nayar M, Microfilariae in a thyroid aspirate smear: An incidental finding Acta cytol 1989;33:942-43.
5. Yenkeswar PN, Dinkar T, Sudhakar K, Bobhate K. Microfilariae in fine needle aspirates: A report of 22 cases. Indian J Pathol Microbiol 2006;49:365-9.
6. Mitra SK, Mishra RK, Verma P, Cytological diagnosis of microfilariae in filariasis endemic areas of eastern Uttar Pradesh J of Cytol 2009;26:11-14.
7. Kishore B, Khare P, Gupta RJ, Bisht SP, Microfilaria of Wuchereria bancrofti in cytologic smears: a report of 5 cases with unusual presentations Acta Cytol 2008 52:710-12.
8. Kumar B, Karki S, Yadava SK, Role of Fine Needle Aspiration Cytology in Diagnosis of Filarial Infestation DiagnCytopathol 2011;39:8-12.
9. Kapila K, Verma K. Diagnosis of parasites in fine needle breast aspirates. Acta Cytol. 1996;40:653– 6.
10. Yelkar, B. R., et al. Filariasis presenting as non-resolving pleural effusion. International Journal of Biological and Medical Research 2012;3: 2284-2286.
11. Patil, Prashant, et al. Parasites (filaria & strongyloides) in malignant pleural effusion. Indian journal of Medical Sciences 2005;59: 455-456.
12. Joshi AM, Pangarkar MA, Ballal MM. Adult female Wuchereria bancrofti: Nematode in a fine needle aspirate of the lymphnode (left) Acta Cytol. 1995;39:138.
13. Singh, S. K., Mukta Pujani, and Meenu Pujani. Microfilaria in malignant pleural effusion: An unusual association. Indian Journal of Medical Microbiology 2010;28: 392-394.
14. Sahu KK, Pai P, Raghuvver CV, Pai RR. Microfilaria in a fine needle aspirate from the salivary gland. Acta Cytol. 1997;41:954.
15. Noroes J, Addiss D, Amara F, Coutinho A, Medeiros Z, Dreyer G, Occurrence of living adult Wuchereria bancrofti in scrotal area of men with microfilaremia Trans R Soc Trop Med Hyg 1996 90:55-56.
16. Pandit CG, Pandit SR, Iyer IV. The adhesion phenomenon in filariasis: A preliminary note. Indian J Med Res. 1929;16:946–53.
17. Walter A, Krishnaswami H, Cariappa A. Microfilariae of Wuchereria bancrofti in cytologic smears. Acta Cytol. 1983;27:432–6.
18. Rukmangadha N, Shanthi V, Kiran CM, Nalini PK, Sarella JB. Breast filariasis diagnosed by fine needle aspiration cytology: A case report. Indian J Pathol Microbiol. 2006;49:243–4.
19. Chowdry M, Langes S, Agarwal M, Agarwal C, Microfilaria in thyroid gland nodule Indian J Pathol Microbiol 2008;51:94-96.
20. Mondal RK, Ray R, Kawsar H, Ali MS. A rare case of microfilaria in thyroid aspirate. Bangladesh Journal of Medical Science Vol. 13 No. 01 January'14
21. India. Ministry of Health and Family Welfare. Annual

- report. 2010-2011. New Delhi: Department of Health and Family Welfare, Government of India; 2011. p. 349.
22. Pratima Khare, Pooja Kala, Aditi Jha, Nidhi Chauhan, Priyanka Chand. Incidental Diagnosis of Filariasis in Superficial Location by FNAC: A Retrospective Study of 10 Years. Journal of Clinical and Diagnostic Research. 2014;8:FC05-FC08

**Source of Support:** Nil; **Conflict of Interest:** None

**Submitted:** 01-06-2019; **Accepted:** 29-06-2019; **Published:** 24-07-2019