

Penile Fracture with Rupture of Bilateral Corpora Cavernosa and its Management by Emergency Surgeon

Syed Tausif Ahmed¹, Vivek Dubey², Kumar Pankaj³, Azhar Alam⁴

ABSTRACT

Introduction: Penile fracture is rarely encountered by the emergency surgeon. It is defined as the rupture of the tunica albuginea of the corpus cavernosum due to a blunt trauma on an erect penis. Usually one corporal body undergoes a transverse tunical rupture but involvement of both corpora cavernosa, corpus spongiosum and urethra have also been reported.

Case report: The authors report a case of penile fracture in a 38 years old male patient which was managed by an emergency surgeon. The diagnosis was reached on the basis of clinical presentation. We also highlight the etiology, the process of diagnosis, the surgical repair and prognosis of penile fracture.

Conclusion: Early repair has the best prognosis. As a urologist may not be available at all emergency centers, an emergency surgeon should be well versed with it.

Keywords: Bilateral Corpora Cavernosa, Emergency Repair, Penile Fracture

INTRODUCTION

Penile fracture is a rare emergency. Earliest surgical repair provides the best prognosis. Expertise of an urologist may not be available in the emergency room at all centres. Hence, an emergency surgeon should be abreast with the clinical features, diagnosis, management and prognosis of patients with penile fracture. The penile fractures that have been reported in the literature are usually on one side. Tear of tunica albuginea of bilateral corpora cavernosa is a very rare case. We present a case of penile fracture with tear in corpora spongiosum, urethra and both corpora cavernosa.

CASE HISTORY

A 38 years old man presented in the emergency department with the chief complaint of pain in the penis since six hours. The pain started after accidental trauma during coitus with a woman on top. There was history of a snap feeling at the time of the accident followed immediately by detumescent of the erect penis.

On examination the penis was swollen, tender and there was blood present at the meatus. The penis was shaped like an eggplant (figure 1 and figure 2). On careful palpation of the penis a rolled up thing was observed. A diagnosis of penile fracture was made. Routine blood investigations were done. Ultrasonography of the penis was performed but, it was not able to diagnose the lesion in the corpora cavernosa.

The patients underwent emergency surgical exploration of the penis under spinal anaesthesia. Just before exploration a single attempt at catheterization was done at the operation

table. The catheter helps the surgeon in identifying the urethra. A sub coronal incision was given. The corpora cavernosa was explored. The lacerations were noted on tunica albuginea of both sides of the corpora cavernosa along with tear in corpus spongiosum and the urethra (figure 3). Hematoma was thoroughly washed with saline. The urethral injury was repaired with 3/0 polyglactin 910. Tunica albuginea of both corpora cavernosa were repaired with 3/0 prolene. Haemostasis was achieved.

Post operatively the patient recovered uneventfully. In the follow up at 1 year no recurrence occurred.

DISCUSSION

Penile fracture is rarely encountered by the emergency surgeon. It is defined as the rupture of the tunica albuginea of the corpus cavernosum due to a blunt trauma on an erect penis. Trauma must have occurred in the erect state and not in the flaccid state of the penis for the lesion to be included in the definition.¹ Usually one corporal body undergoes a transverse tunical rupture but involvement of both corpora cavernosa, corpus spongiosum and urethra have also been reported.^{2,3}

The most common mode of injury reported is injury at the time of coitus with woman on top. Other modes of injuries that have been reported are fall on erect penis, manipulation during masturbation, normal sexual intercourse etc.⁴

Penile fracture is diagnosed on the basis of typical history and physical findings. The clinical features of penile fracture are very consistent.^{5,6} The patient reports hearing a snap sound at the time of trauma.⁷ It is followed by pain in the penile region. The erect penis undergoes instant detumescence. Gradually, the swelling appears around the penile region giving the penis a classical eggplant shape.^{8,9} If urethral

¹Resident, Department of General Surgery, Rochester Regional Health Center, Rochester, New York, ²Senior Resident, Department of Orthopaedics, H.B.T. Medical College and Dr. R.N. Cooper Municipal General Hospital, Mumbai, ³Senior Resident, Department of General Surgery, Narayan Medical College, Sasaram, Bihar, ⁴Consultant, Department of General Surgery, EMC Hospital, Amritsar, India

Corresponding author: Vivek Dubey, Room no. 305, RMO Quarters, Dr. R.N. Cooper Hospital, N.S. Road, 1, Vile Parle (W), Mumbai - 400056, India

How to cite this article: Syed Tausif Ahmed, Vivek Dubey, Kumar Pankaj, Azhar Alam. Penile fracture with rupture of bilateral corpora cavernosa and its management by emergency surgeon. International Journal of Contemporary Medical Research 2019;6(2):B15-B17.

DOI: <http://dx.doi.org/10.21276/ijcmr.2019.6.2.39>

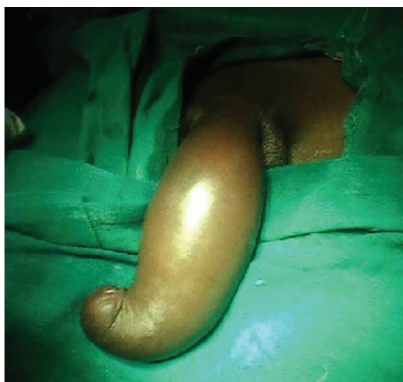

Figure-1: Preoperative view of penis (ventral surface)

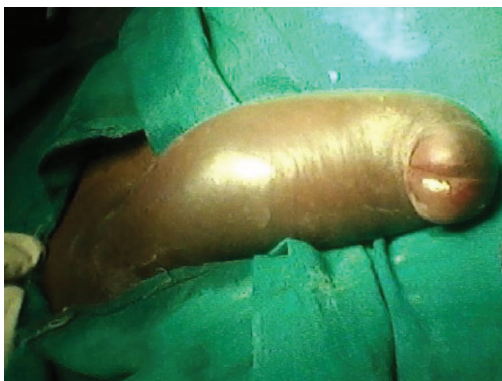

Figure-2: Preoperative view of penis (Dorsal surface)

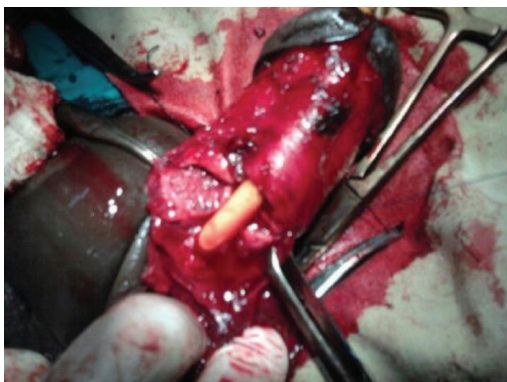


Figure-3: During operation

injury is present then the patient may present with blood at the meatus, hematuria and difficulty in voiding.^{8,10}

The diagnosis of penile fracture is mainly clinical with investigations play very little role. There have been reports of use of ultrasound. It suffers from the disadvantage that the lesion on tunica albuginea may be easily missed as it is covered with hematoma.¹¹ Magnetic resonance imaging though costly may be needed in atypical presentations. It allows accurate diagnosis as it can differentiate high intensity of corpora cavernosa sinusoids from low intensity of tunica albuginea.¹²

Current management of penile fracture is immediate surgical repair. Historically, conservative management was used in its management. These consisted of cold compresses, pressure dressings, penile splinting, anti-inflammatory medications, fibrinolytics, and suprapubic urinary diversion with delayed repair of urethral injuries. But because of a very high rate of

complication associated with conservative management (29-53%), it has gradually been replaced with immediate surgical repair. The main complications associated with conservative management are penile abscess, missed urethral injury, permanent penile curvature, nodule formation at the site of rupture, erectile dysfunction, painful erection, painful coitus, corporourethral fistula, arteriovenous fistula, and fibrotic plaque formation.¹³

Early surgical primary repair eliminates most of these complications. Apart from decreasing the duration of hospital stay, it has a high success rate (92%) compared to conservative management (59%).¹⁴

In surgical repair, the site of injury may be approached by two methods- either by giving an incision directly at the site of injury or by giving a sub coronal incision. Sub coronal incision is favoured by most surgeons. After the incision, the penile skin is degloved and the corpora cavernosa explored. Any hematoma is washed away. Any urethral injury is noted. The urethral injury is repaired with polyglactin 910. The tunica is repaired with either 3-0 prolene or polyglactin 910. Haemostasis is achieved and the skin closed.

Post operative recovery is usually uneventful. Sexual intercourse and masturbation may cause hematoma formation at the suture line. Any hematoma leads to weak scar.¹⁵ Hence sexual intercourse and masturbation should be avoided for 6-8 weeks.¹⁶ The main complications include wrong curvature and nodularity at the site of injury.¹⁷

CONCLUSION

Penile fracture with rupture of bilateral corpora cavernosa, corpus spongiosum and urethra is a very rare case. Penile fracture is diagnosed on the basis of typical history and physical findings.

Current management of penile fracture is immediate surgical repair. In surgical repair the site of injury may be approached by two methods- either by giving an incision directly at the site of injury or by giving a sub coronal incision. Sub coronal incision is favoured by most surgeons. In the post operative period sexual intercourse and masturbation should be avoided for 6-8 weeks.

REFERENCES

1. El-Sherif AE, Dauleh M, Allowneh N, et al. Management of fracture of the penis in Qatar. *Br J Urol.* 1991; 68:622-5.
2. El-Bahansawy MS, Gomha MA. Penile fractures: the successful outcome of immediate surgical intervention. *Int J Imp Res* 2000; 12: 273-7.
3. Penson DF, Seftel AD, Krane RJ, et al. The hemodynamic pathophysiology of impotence following blunt trauma to the erect penis. *J Urol* 1992; 148: 1171-80.
4. Schonberger B: Verletzungen der mannlichen Genitalorgane. *Z Urol Nephrol.* 1982; 5:879-83.
5. Cole FL, Vogler RW. Fractured penis. *J Am Acad Nurse Pract* 2006;18:45-48.
6. Kochakarn W, Viseshsindh V, Muangman V. Penile fracture: long-term outcome of treatment. *J Med Assoc Thai* 2002;85:179-82.
7. Meares EM: Traumatic rupture of the corpus

- cavernosum. J Urol. 1971; 105:407-9.
8. Mydlo JH, Hayyeri M, Macchia RJ: Uretrography and cavernosography imaging in a small series of penile fractures: a comparison with surgical findings. Urology 1998; 51:616-9.
 9. Ruckle CH, Hadley HR, Lui PD: Fracture of the penis: Diagnosis and management. Urology 1992; 40:33-5.
 10. Tsang T, Demby AM: Penile fracture with urethral injury. J Urol. 1992; 147:466-8
 11. Dierks PR, Hawkins H. Sonography and penile trauma. J Ultrasound Med. 1983; 2: 417-9.
 12. Fedel M, Venz S, Andressen R, et al. The value of magnetic resonance imaging in the diagnosis of suspected penile fracture with atypical clinical findings. J Urol. 1996; 155:1924-7.
 13. Nale Dj, Nikic P, Vukovic I, et al. Surgical or conservative treatment of penile fracture. Acta Chir Jugosl 2008;55:107-14
 14. Cole FL, Vogler RW. Fractured penis. J Am Acad Nurse Pract 2006;18:45-48
 15. Muentener M. Long-term experience with surgical and conservative treatment of penile Fracture. J Urol 2004;172:576-79.
 16. Ateyah A, Mostafa T, Nasser TA, et al. Penile fracture: Surgical repair and late effects on erectile function. J Sex Med 2008;5:1496-1502.
 17. Naraynsingh V, Maharaj D., Kuruvilla T., et al. Simple repair of fractured penis. J. R. Coll. Surg. Edinb., 43, April, 97-98

Source of Support: Nil; **Conflict of Interest:** None

Submitted: 13-01-2019; **Accepted:** 14-02-2019; **Published:** 28-02-2019