

A Study to Confirm the Position of Endotracheal Tube using Ultrasonography and Standard Auscultation Method

Nandita Kad¹, Ashish Sikarwar², Vineet Kumar³, Deepak Kumari⁴

ABSTRACT

Introduction: Endotracheal intubation is a life saving procedure that is routinely performed by anesthesiologist, emergency medicine physicians and critical care physicians. Study aimed to confirm the position of endotracheal tube using point-of-care ultrasonography and standard auscultation method.

Material and methods: The present study was conducted in the Department of Anaesthesiology and Critical Care, Pt.B.D.Sharma, PGIMS, UHS, Rohtak in a prospective cross over manner. One hundred patients belonging to American Society of Anaesthesiologists (ASA) physical status 1 or 2 of either sex (18-60 years) presenting for surgery under general anaesthesia were included in the study. After intubation, five points of auscultation was done and position of ETT was noted. Auscultation was followed by Point-of-Care ultrasonography. Assessment by ultrasonography consisted of: Step 1-Tracheal dilation assessment:-ultrasound probe placed transversely on the anterior neck approximately 2 cm superior to the suprasternal notch and scanned cranially to the cricothyroid membrane. The marker of endotracheal cuff is tracheal dilatation with balloon inflation. Step 2-Pleural sliding assessment:-probe placed vertically on the anterior chest at the third rib space midclavicular line bilaterally. Assessment of lung expansion evaluated by the detection of horizontal movement of the pleural linings with respiration.

Results: Better confirmation of endotracheal tube placement with ultrasonography as compared to standard auscultation method.

Conclusion: Point of care ultrasonography is more sensitive and specific in detecting location of endotracheal tube.

Keywords: Endotracheal Tube, Placement, Ultrasonography.

directly correlated with the patient's presenting signs and symptoms. It is used by various specialities e.g. anesthesia, critical care medicine and general surgery in diverse situations and broadly divided into procedural, diagnostic and screening applications.³ In patients undergoing emergent tracheal intubation, there is currently no universally accepted gold-standard test to confirm the location of the endotracheal tube (ETT). End-tidal carbon dioxide (ET CO₂) detection is the best of the tests that are routinely utilized to confirm ETT placement, however, it has been shown to have an error rate as high as 1/10 for proper determination of ETT location in emergency intubations. As a result, multiple modalities are necessary to confirm ETT location, which can delay mechanical ventilation and other treatments.⁴⁻⁵ The lack of a single, reliable test to confirm ETT placement can potentially lead to confusion regarding the location of the tube. This confusion can result in both unrecognized oesophageal intubations ("false positive"), as well as successful tracheal intubations that are subsequently removed ("false negative"), subjecting the patient to further unnecessary attempts at airway management.⁶

Study aimed to confirm the position of endotracheal tube using point-of-care ultrasonography and standard auscultation method

MATERIAL AND METHODS

The present study was conducted in the Department of Anaesthesiology and Critical Care, Pt.B.D. Sharma, PGIMS, UHS, Rohtak in a prospective cross over manner. One hundred patients belonging to American Society of Anaesthesiologists (ASA) physical status 1 or 2 of either sex (18-60 years) presenting for surgery under general anaesthesia were included in the study.

Exclusion criteria

Patients with:-

- Anticipated difficult intubation (MPG 3 and 4)

¹Professor, Department of Anesthesia, ²Junior Resident, Department of Anesthesia, ³Senior Resident, Department of Anesthesia, ⁴Junior Resident, Department of Anesthesia, PT BD Sharma PGIMS, Rohtak, India

Corresponding author: Dr Vineet Kumar, H. N 11 /29 Chanakyapuri Colony Behind Sheila Theatre, Rohtak, India

How to cite this article: Nandita Kad, Ashish Sikarwar, Vineet Kumar, Deepak Kumari. A study to confirm the position of endotracheal tube using ultrasonography and standard auscultation method. International Journal of Contemporary Medical Research 2018;5(12):L12-L16.

DOI: <http://dx.doi.org/10.21276/ijcmr.2018.5.12.31>

INTRODUCTION

Numerous techniques exist for discriminating between endotracheal and esophageal placement.¹ It is now straightforward to discriminate between tracheal intubation from esophageal intubation however identifying correct location of the endotracheal tube (ETT) within the trachea remains challenging. Endobronchial intubation is the most common malposition encountered, and it carries potential serious complications such as hypoxemia, atelectasis, hyperinflation and barotrauma.²

Point of care ultrasonography (POCUS) is defined as ultrasonography brought to the patient and performed by the provider in real time. Point of care ultrasonography images can be obtained nearly immediately and the clinician can use real time dynamics images rather than images recorded by a sonographer and interpreted later allowing findings to be

- Oropharyngeal pathology e.g. haematoma, abscess, tumour etc.
- Pregnancy
- Refusal to consent

were not included in the study.

Preparation of the patients

The patients were kept fasting for 6 hours prior to the scheduled time of surgery. They were premedicated with a tablet of alprazolam 0.25 mg and ranitidine 150 mg orally, the night before surgery and in the morning. On arrival in the operating room, i.v. line was secured and monitoring of NIBP,HR,ECG,ETCO₂ and SpO₂ will be done by using Drager Primus monitor. Ultrasound was performed with Sonosite M-Turbo ultrasound machine with a 6-13 MHz linear probe, two dimensional M-mode modalities.

Anesthesia technique

In all the patients a uniform anaesthetic technique will be used. Prior to intubation, all patients will be preoxygenated for 3 minutes and induction will be done with i.v. glycopyrrolate 0.2mg, fentanyl 2.0µgkg⁻¹ and thiopentone sodium 5mgkg⁻¹. Neuromuscular blocking agent vecuronium 0.10mgkg⁻¹ will be given to facilitate intubation. Direct laryngoscopy and intubation will be done with endotracheal tube of 7mm ID (Internal Diameter) in female and 7.5mm ID in males. All ETT (endotracheal tube) cuffs will be inflated with air for the study duration. If there is bucking, coughing, bronchospasm and laryngospasm on laryngoscopy, patients will not be taken for study.

Method of examination

After intubation, five points of auscultation was done and position of ETT was noted. Auscultation was followed by Point-of-Care ultrasonography. Assessment by ultrasonography consisted of: Step 1-Tracheal dilation assessment:-ultrasound probe placed transversely on the anterior neck approximately 2cm superior to the suprasternal notch and scanned cranially to the cricothyroid membrane. The marker of endotracheal cuff is tracheal dilatation with balloon inflation. Step 2-Pleural sliding assessment:-probe placed vertically on the anterior chest at the third rib space midclavicular line bilaterally. Assessment of lung expansion evaluated by the detection of horizontal movement of the pleural linings with respiration. During the whole examination SpO₂ will be carefully monitored for patient safety. Patient was not disturbed till the study period is over. Thereafter, anaesthesia was continued with nitrous oxide, oxygen, isoflurane and analgesics were administered based on the requirements. At the end of surgery, when patients having spontaneous respiratory efforts, residual neuromuscular blockade was reversed with inj.glycopyrrolate and inj. neostigmine. Recovery was assessed and extubation was done after throat suction. After complete recovery patient was shifted to post anaesthesia care unit.

Method of collection of data

Auscultation

Detection of breath sounds in each lung

	Right lung	Left lung
Not present		
Faintly present		
Fully present		

Based on above findings, location of tube could be endotracheal/right main bronchus/left main bronchus/oesophagus

Ultrasound

A. Tracheal dilation

-YES/NO

B. Lung sliding sign

	Right Lung	Left lung
Absent		
Present		

Based on above findings, interpretation for location of tube could be endotracheal/right main bronchus/left main bronchus.

STATISTICAL ANALYSIS

The data is summarized using frequencies and/or mean±sd supported by appropriate graphs. Qualitative variables are expressed as frequencies/percentages and compared between groups using Chi-square/Fisher's Exact Test. Quantitative variables are written in terms of mean±sd and compared using Unpaired t-test. The competing procedures are compared with gold standard using Sensitivity, Specificity, PPV, NPV, Diagnostic Accuracy and Kappa Statistic. A p-value < 0.05 is considered statistically significant. The data is tabulated in MS Excel and analysis performed using Statistical Package for Social Sciences (SPSS) version 16.0 software.

RESULTS

The patients demographic profile including age, sex, height, weight, BMI, ASA physical status between the two groups were comparable with each other.

	N	%
Right endobronchial	15	93.75%
Left endobronchial	01	6.25%
Total	16	100%

Table-1:

Auscultation	N	%
Trachea	72	76.60%
Bronchial	22	23.40%
Total	94	100%

Table-2: Shows the location of endotracheal tube according to auscultation

Location	Trachea	Bronchial	p-value
Distance	Mean ±S.D.	Mean ±S.D.	
D anterior trachea	1.05±0.07	1.06±0.09	0.343
D lung pleura	3.06±0.08	3.08±0.09	0.260

Table-3: Shows the distance of anterior trachea and distance of lung pleura in the studied group

Location	Trachea Mean ±S.D.	Bronchial Mean ±S.D.	p-value
T usg(s)	151.23±10.69	148.19±12.39	0.203
T aus(s)	43.24±4.46	45.31±6.35	0.108

Table-4: Shows time duration to perform point-of-care ultrasonography and auscultation after intubation



Figure-1: Distribution of endobronchial intubation

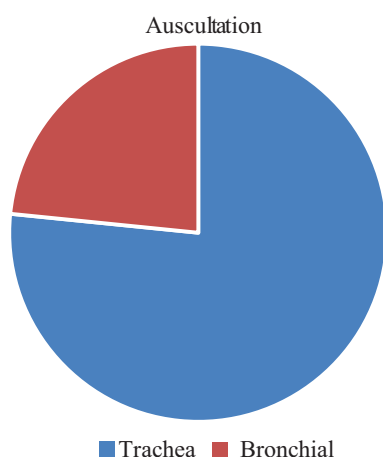


Figure-2: Distribution of endotracheal tube according to auscultation.

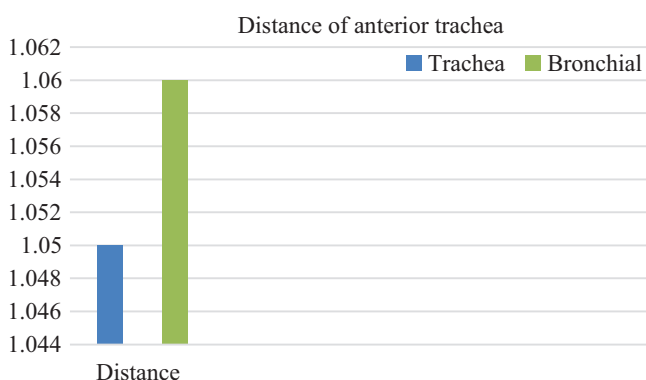


Figure-3(a): Mean distance of anterior trachea in the two groups.

Location of endobronchial tube

Table 1 and figure -1 shows the location of endobronchial tube. The number of right endobronchial intubation was 15 and the number of left endobronchial intubation was 01.

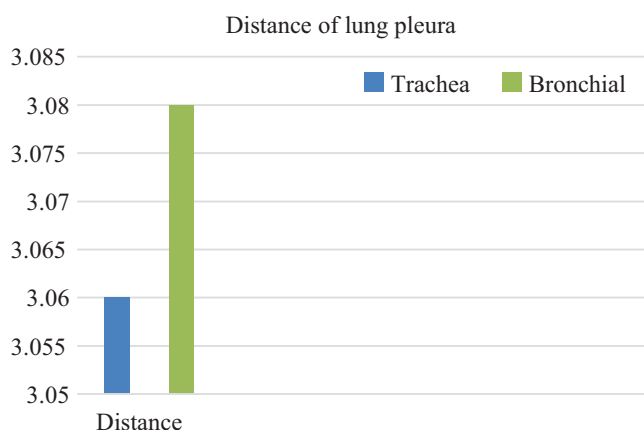


Figure-3(b): Mean distance of lung pleura in the two groups

Auscultation

The number of endotracheal intubation according to auscultation were 76.60% and number of endobronchial intubations were 23.40% (table-2, figure-2).

Distance of anterior trachea and pleura

The mean distance of anterior trachea was 1.05±0.07 cms in endotracheal intubation and mean distance of anterior trachea in endobronchial intubation was 1.06±0.09 cms. We found no statistically significant difference between the two groups (p value=0.343) (table-3, figure-3).

The mean distance of lung pleura in endotracheal intubation was 3.06±0.08 cms and mean distance of lung pleura in endobronchial intubation was 3.08±0.09 cms. We found no statistically significant difference between the two groups (p value=0.260) (figure 3b).

DISCUSSION

Auscultation to confirm position of endotracheal tube

The present study observed that location of endotracheal tube can be detected by using standard auscultation technique. All the 100 patients had undergone auscultation. In 6 patients accidental esophageal intubation occurred which was subsequently corrected and placed. The average duration of auscultation was 43.60±4.86 seconds. The sensitivity of study was 80.77% and specificity was 43.75%. The positive predictive value (PPV) was 87.50% and negative predictive value (NPV) was 31.82%. The diagnostic accuracy of study was 74.47%. The kappa coefficient (k) value was 0.21 which showed minimal level of agreement, and percentage of data that are reliable lies between 4-15%. This data was clinically insignificant with p-value <0.001. Our study shows that auscultation is not as reliable as ultrasonography to confirm the position of endotracheal tube.

These observations were in agreement with that of Ramsingh et al who also confirmed the position of endotracheal tube by standard auscultation technique and point of care ultrasonography. Forty two patients were included in study which required general anaesthesia with ETT. Patients were randomised to the right main stem bronchus, left main stem bronchus or tracheal intubation. The sensitivity of auscultation was 66% (95% CI, 0.39 to 0.87) and a specificity of 59% (95% CI, 0.39 to 0.77). The positive predictive value (PPV)

was 48% and negative predicted value (NPV) was 76%. The study also concluded that results of auscultation depends upon the clinical experience of the anesthesiologist and there are high chances of missing endobronchial intubations.⁷

Our study was also in accordance with that of Sitzwohl et al who conducted a prospective double blind randomized study to detect endobronchial intubation by depth of endotracheal tube, bilateral auscultation and observation of chest movements who randomly assigned patients in 8 study groups. First year residents and experienced anaesthetists were randomly assigned to independently perform bilateral auscultation of the chest, observation and palpation of symmetrical chest movements. The sensitivity of auscultation was 65% and sensitivity of all three tests combined were 100% and which was statistically significant ($p < 0.001$). The study concluded that less experienced clinicians should rely more on tube insertion depth than on auscultation to detect inadvertent endobronchial intubation. Even experienced physicians will benefit from inserting tubes to 20-21 cm in women and 22-23 cm in men, especially when high ambient noise precludes accurate auscultation such as in emergency situation or helicopter transport.⁸

Point-of-care ultrasonography

In ultrasound examination we observed trachea dilation and lung sliding sign to detect the location of endotracheal tube.

Trachea dilation

The present study observed that transtracheal ultrasound is an important technique to rule out esophageal intubation. In our study, out of 100 patients 94 patients had trachea dilation during passage of ET tube in trachea. The rest 6 patients who didn't have trachea dilation had accidental esophageal intubation which was subsequently correctly placed and checked. Tracheal dilation had 100% diagnostic accuracy.

Similar results was obtained by Lin et al who reviewed nine articles: one study using neck ultrasound, two using lung/diaphragmatic ultrasound, one with both, and five studies looking at the direct visualization of the tracheal tube tip. Transtracheal ultrasound performed on 81 critically ill patients. The sensitivity of transtracheal ultrasound for intubation were overall high ranging from 0.92 to 1.00 with excellent specificities at 1.00 was 96%. The study concluded that bedside ultrasound is a useful adjunct tool in confirming tracheal tube placement in critically ill patients in several small single centre studies, but further studies are needed to assess its accuracy in a randomized multicentre setting.⁹⁻¹⁰

Lung sliding sign

The present study observed that lung sliding sign is an important tool to confirm the location of endotracheal tube. The sensitivity of this test was 88.46% and specificity was 100%. The positive predictive value (PPV) was 100% and negative predictive value (NPV) was 64%. The diagnostic accuracy was 90.43%. The kappa coefficient (k) value was 0.723 which show moderate level of agreement and the percentage of data reliable was 35-63%. Our study shows that lung sliding sign is a reliable method to confirm the location of endotracheal tube with statistically significant

p -value of < 0.001 .

These observations were in agreement with that of Ramsingh et al. patients were endotracheally intubated. The sensitivity of lung sliding sign was 93% and specificity was 96%. PLUS examination showed an improved ability to detect both right and left bronchial intubation over auscultation. There was 20% improvement in the detection of improper ETT placement comes with the application of a noninvasive ultrasound examination. The positive predictive value (PPV) was 93% and negative predictive value (NPV) was 96%. The Chi-square comparison showed statistically significant improvement with ultrasound versus auscultation for the detection of (a) trachea vs. main stem intubation ($p = 0.0005$), (b) trachea versus main left stem intubation ($p = 0.0004$), and (c) trachea versus right main stem intubation ($P = 0.0371$).⁷

CONCLUSION

Auscultation is frequently used method to detect location of endotracheal tube. The changes of wrong judgement of location of endotracheal tube is higher in auscultation as it is highly dependent on clinical experience of anesthesiologist. Tracheal dilation and bilateral lung pleura movements can be directly observed in ultrasonography which are more sensitive and specific than standard auscultation technique. Endobronchial placement of tube can lead to serious complication e.g. atelectasis of lung which can be prevented by using point of care ultrasonography. It is important to maintain the correct location of endotracheal tube.

We concluded that point of care ultrasonography is more sensitive and specific in detecting location of endotracheal tube. Hence we recommend to use point of care ultrasonography to confirm the location of endotracheal tube.

REFERENCES

1. Grmec S. Comparison of three different methods to confirm tracheal tube placement in emergency intubation. *Intensive Care Med* 2002;28:701-4.
2. Szekely SM, Webb RK, Williamson JA, Russell WJ. The Australian Incident Monitoring study. Problems related to endotracheal tube. An analysis of 2000 incident reports. *Anaesth Intensive Care* 1993;21:611-6.
3. Adi O, Chuan TW, Rishya M.A feasibility study on bedside upper airway ultrasonography compared to waveform capnography for verifying endotracheal tube location. *Critical Ultrasound Journal* 2013;5:7.
4. Harper CM. Capnography: clinical aspects. *Journal of Royal Society of Medicine* 2005;98:184-185.
5. Cunningham DJ. The Thorax. Romanes GJ. In: *Cunningham's Manual of Practical Anatomy*. 15th ed. New York: Oxford University Press 2013;2:17-20.
6. Goksu S, Sen E. History of intubation. *Journal of Academy Emergency Medicine* 2015;14:35-36.
7. Ramsingh D, Frank E, Haughton R, Schilling J, Grimenez K, Banh E, et al. Auscultation versus point of care ultrasound to determine tracheal versus bronchial intubation: A diagnostic accuracy study. *Anesthesiology* 2016;124:1012-20.
8. Sitzwohl C, Langheinrich A, Schober A, Sessler D,

Herkner H, Gonano C, et al. Endotracheal intubation detected by insertion depth of endotracheal tube, bilateral auscultation, or observation of chest movements: randomised trial. *Br J Anaesth* 2010;341:5943

9. Lin MJ, Gurley K, Hoffmann B. Bedside ultrasound for tracheal tube verification in pediatric emergency department and ICU patients: A systematic review. *Pediatr Crit Care Med* 2016;17:469-476.
10. Khosla R, Cara K, Ahmad A. Using ultrasound to confirm endotracheal tube position in the intensive care unit. *J Anest and Inten Care Med* 2016;1:92-98.

Source of Support: Nil; **Conflict of Interest:** None

Submitted: 23-10-2018; **Accepted:** 20-12-2018; **Published:** 03-01-2019