

A Comparative Study of Microscopic and Endoscopic Type I Tympanoplasty

Sonali Jana¹, Soma Mandal²

ABSTRACT

Introduction: The telescopic, wide angle, magnified view of the endoscope overcomes most of the disadvantages of the microscope by exposing every corner of tympanic cavity. Study objectives were to compare the outcomes of microscopic and endoscopic type I tympanoplasty and to determine the advantage and disadvantage of endoscopic type I tympanoplasty as compare to microscopic type I tympanoplasty.

Material and methods: Prospective observational study was conducted in Department of ENT and Head-Neck Surgery of a tertiary care teaching Hospital. Sixty patient undergoing either MAT(microscope assisted tympanoplasty) or EAT (endoscope assisted tympanoplasty) were studied prospectively for a period of six month. Each patient subjected to pure tone audiometry preoperatively and postoperatively to document the hearing status. In the same sitting grafted tympanic membrane's status was evaluated.

Result: In this study difference between two group were not statistically significant regarding success rate and failure rate. Both the procedure were almost same. In this study endoscopic tympanoplasty group show less incidence of postoperative pain and better cosmetic result.

Conclusion: Regarding the outcome of surgery, success rate of endoscope assisted tympanoplasty is comparable to the microscope assisted tympanoplasty. Only advantage of endoscope assisted tympanoplasty is that it provides a wide angled magnified view by which all the corner of middle ear cavity can be visualised for any residual disease.

Keywords: CSOM, Endoscopy, Tympanoplasty

INTRODUCTION

Chronic suppurative otitis media (CSOM) is defined as chronic inflammation of the middle ear and mastoid cavity which presents with recurrent ear discharge or otorrhoea through a tympanic membrane perforation.¹

Surgery of CSOM provides dry ear with the improvement of hearing in the majority of patients. Wullstein² and Zollner³ in 1949, lead to a new concept of the treatment of deafness secondary to chronic infection in the middle ear and mastoid and the new method was called "tympanoplasty". Tympanoplasty is "an operation to eradicate disease in the middle ear and to reconstruct the hearing mechanism, with or without tympanic membrane(TM) grafting".⁴

Traditionally, surgeons perform microsurgery of the middle ear with the assistance of a microscope. However, a microscope offers a straight-line view, which limits the visual field in the deep recesses of the middle ear. This is overcome by use of rigid endoscope for tympanoplasty. Endoscopes therefore offer the surgeon the capability of

wide fields of view with minimal exposure, looking behind the obstructions or overhangs, with much less requirement for surgical exposure than demanded by conventional techniques.

Very few studies have been conducted till date to compare the outcomes of tympanoplasty by conventional microscopic method and endoscopic method. Gaur et al⁵ conducted a study among 30 cases in a tertiary care hospital during the period of January 2012–August 2013 to compare the results of the endoscope assisted myringoplasty with microscope assisted myringoplasty surgery. The success rate was comparable to one another with superior results by endoscope group regarding cosmetic aspect.

The aims of our study were to compare the outcomes of microscopic and endoscopic type I tympanoplasty such as percentage of graft uptake, postoperative hearing improvement and To determine the advantages and disadvantages of the endoscope as compared to the microscope in tympanoplasty surgery.

MATERIAL AND METHODS

The study was conducted in the otorhinolaryngology department of a tertiary care teaching hospital, kolkata, India over a period of two years (August 2014 to July 2016). The study design was prospective randomized one.

Inclusion criteria: - Subjects with dry, central tympanic membrane perforation due to CSOM with conductive hearing loss.

Exclusion criteria:– Subjects with marginal or attic perforations, patients with cholesteatoma, otitis externa, otomycosis, uncontrolled diabetes mellitus, ossicular fixation, ossicular discontinuity, revision cases and those with upper respiratory tract infections at the time of surgery and patients with other complication following CSOM.

The study was approved by the Institutional Review Board. A total of 60 patients between the ages of 15-60

¹RMO Cum Clinical Tutor, Department of ENT and Head – Neck Surgery, ²Assistant professor Department of ENT and Head–Neck Surgery, Calcutta National Medical College and Hospital, Kolkata, India.

Corresponding author: Soma Mandal, 15/1, Laxminarayan Chakraborty Lane Howrah – 711101, West Bengal, India.

How to cite this article: Sonali Jana, Soma Mandal. A comparative study of microscopic and endoscopic type I tympanoplasty. International Journal of Contemporary Medical Research 2018;5(10):J1-J4.

DOI: <http://dx.doi.org/10.21276/ijcmr.2018.5.10.17>

years were selected as per the inclusion and exclusion criteria. Informed, written consents were obtained from all individual participants included in the study. The patients were randomized by simple randomization with single blinding method into two groups based on the surgical procedure they received. In Group A, 30 patients underwent conventional microscope assisted tympanoplasty (MAT) and in Group B, rest 30 cases underwent endoscope assisted tympanoplasty (EAT). Patients were admitted 2 days prior to surgery, detailed history taking and clinical examination was done and recorded in a customized proforma. All of them were subjected to pure tone audiometry to document the pre-operative hearing status. It was done as per the method outlined by the American Speech and Hearing Association (ASHA). Air-Bone (A-B) gap at frequencies 500 Hz, 1 KHz and 2 KHz was noted and hearing loss was calculated by taking the average of three.

All the surgeries were done under local anesthesia using 2% Xylocaine with 1:100000 adrenaline solution by the same surgeon of the unit. Endoscopic tympanoplasty was done by permeal route and microscopic tympanoplasty was done by post-aural route. In endoscopic tympanoplasty, Zero degree, Thirty degree, 18 cm long, 4 mm wide Hopkin's rod endoscope with camera and monitor was used during surgery. In post aural technique temporalis fascia was taken from the same incision but in endoscopic technique temporalis fascia was harvested by given separate incision above the pinna. Post-auricular incision was given just behind the Post-auricular groove In both the technique an incision was made laterally in the posterior and inferior parts of the external auditory canal (about 5 to 10 mm from the tympanic membrane). A tympanomeatal flap was elevated, and the middle ear cavity was visualized. In endoscopic technique thirty degree telescope was used to visualise the every corner of middle ear cavity. Getting sure of no residual disease in tympanum temporalis fascia inlay graft was placed and tympanomeatal flap repo seated.

All patients in both groups were followed up for minimum of 6 months. Final assessment of tympanic membrane (TM) and hearing was done at 6 months postoperatively. An intact mobile TM with the closure of air-bone gap \leq 13 dB at 6 months post-operation was considered as a successful outcome. The presence of a defect in TM or air-bone gap $>$ 13 dB or both at 6 months was considered to be a failure. Subjective and objective assessment of scar was done at 6 months postoperatively.

RESULTS

Out of 60 patients, 34 were females (56%) and 26 were males (43%). Among 34 females, 16 (53%) patients underwent endoscopic and 18 (60%) patients underwent microscopic tympanoplasty. Out of 26 males 14 (46%) patients underwent endoscopic and 12 (40%) patients underwent microscopic tympanoplasty (Table 1). The observations showed that the female patients predominated over their male counterpart.

The age of the patients ranged from 15 to 60 years. The majority of patients in this study were in their second and

	Sex	
	Male	Female
MAT	12(40%)	18(60%)
EAT	14(46%)	16(53%)

MAT: Microscope-assisted tympanoplasty, EAT: Endoscope-assisted tympanoplasty.

Table 1: Sex incidence among two groups.

	Age (in years)		
	15-30	31-45	46-60
MAT	15(50%)	11(36%)	4(13%)
EAT	18(60%)	10(33%)	2(6%)

MAT: Microscope-assisted tympanoplasty, EAT: Endoscope-assisted tympanoplasty.

Table-2: Age distribution among two groups.

Size	MAT	EAT
Small	12(40%)	16(53%)
Medium	15(50%)	12(40%)
Large	3(10%)	2(7%)

MAT: Microscope-assisted tympanoplasty, EAT: Endoscope-assisted tympanoplasty.

Table-3: Size of perforation

MAT	Average 130 min	Range 90-180 min
EAT	Average 100 min	Range 80-150 min

MAT: Microscope-assisted tympanoplasty, EAT: Endoscope-assisted tympanoplasty.

Table-4: Times taken in minutes

	Graft uptake	Graft failure
MAT	27(90%)	3(10%)
EAT	26(86%)	4(13%)

MAT: Microscope-assisted tympanoplasty, EAT: Endoscope-assisted tympanoplasty.

Table-5: Graft status and complication at the end of 6 months

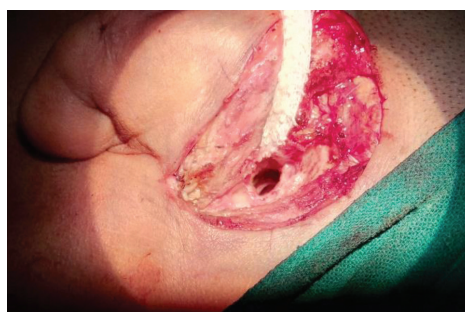

Figure-1: Post auricular incision for microscopic tympanoplasty

third decades of life (Table 2).

It was observed that among the sixty cases that were studied, small and medium size perforation was seen in 55 cases, i.e., 90% of all the cases taken for the study (Table 3).

Time taken for microscopic tympanoplasty was an average of 130 minutes (range of 90-180 minutes). On the other hand, endoscopic tympanoplasty required an average of 100 minutes (range of 80-150 minutes) (Table 4).

Avg CHL (dB)	MAT		EAT	
	Pre-operative	Post-operative	Pre-operative	Post-operative
0-10	0 (0%)	7 (23%)	0 (0%)	10 (33%)
11-20	14(46%)	20 (66%)	12 (40%)	17 (56%)
21-30	16(53%)	3 (10%)	15 (50%)	3 (10%)
31-40	0 (0%)	0 (0%)	3 (10%)	0 (0%)

MAT: Microscope-assisted tympanoplasty, EAT: Endoscope-assisted tympanoplasty.

Table-6: Audiological Evaluation

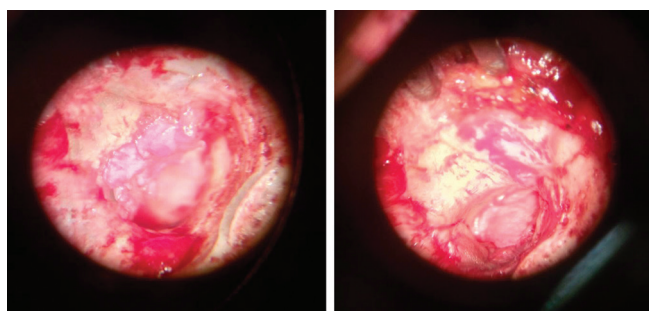


Figure-2: Microscopic view of elevated Tympanomeatal flap; **Figure-3:** Microscopic image show the graft is placed by underlay technique

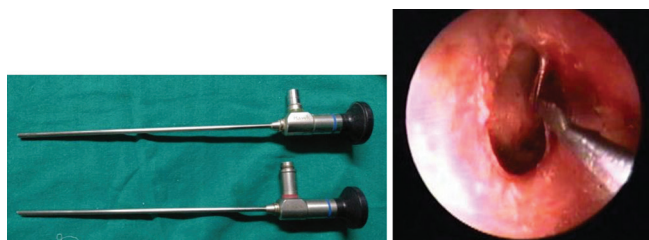


Figure-4: Zero degree and thirty degree 4 mm wide 18 cm long Hopkins rod endoscope; **Figure-5:** Endoscopic image show margin of perforation was freshened

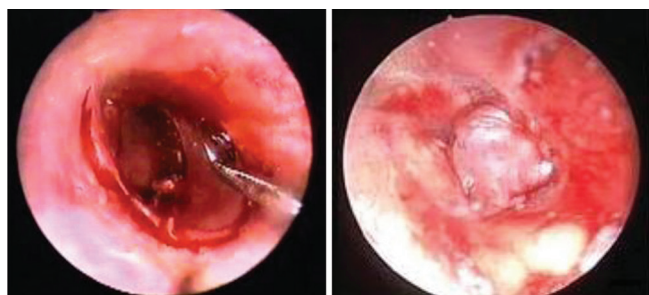


Figure-6: Endoscopic image show canal wall incision; **Figure-7:** Endoscopic image show placement of temporalis fascia graft

At 6 months follow-up, 26 (86%) patients had a successful outcome (regarding graft uptake) in the endoscope group and 27 (90%) patients had a successful outcome in microscope group. Difference between two groups were not statistically too much significant (Table 5).

In microscope assisted tympanoplasty group, it was observed that 14 cases (46%) had an average conductive hearing loss (CHL) of 11–20 dB and 16 cases (53%) had an average CHL of 21–30 dB. Almost 100% of group had an average CHL of range 11–30 dB. Postoperatively in the same group after 6 months of follow-up, it was noticed improvement with decrease in average CHL with 7 cases (23%) having an average CHL between 0 and 10 dB and 20 cases (66%)

having an average of 11–20 dB CHL. As a result, total 27 cases (89%) of postoperative group had an improvement in CHL with average between 0 and 20 dB CHL. Similarly in EAM group, 12 cases (40%) had an average CHL of 11–20 dB and 15 cases (50%) had an average CHL of 21–30 dB. Almost 90% of group had an average CHL of range 11–30 dB. Postoperatively in the same group after 6 months of follow-up, it was noticed improvement with decrease in average CHL with 10 cases (33%) having an average between 0 and 10 dB and 17 cases (56%) having an average of 11–20 dB CHL. Here also total 27 cases (89%) of postoperative group had an improvement in CHL with average between 0 and 20 dB CHL (Table 6).

At the end of 6 months, all (100%) patients in the endoscopic procedure there was no visible scar as it was done permealately but in mycrosopic approach cosmetically acceptable scar was present.

DISCUSSION

The study was undertaken with the objective of determining the merits and demerits of the endoscope compared to microscope in tympanoplasty surgery. While operating the patient with microscope, tortuous external auditory canal and bony overhang hampers the view of the deeper structures. Because of which we need to frequently manipulate head of the patient. Sometimes, in spite of manipulations, deeper structures could not be visualized. In such condition canaloplasty becomes mandatory. This is turn may increase operative time. In contrast, endoscope can be easily negotiated through curvy EAC. Thus, endoscope brings surgeon’s eye to the tip of the scope. There is no need to frequently adjust the patients head or to do canaloplasty thereby saving the operative time (reference). In this study, time taken for microscopic tympanoplasty was an average of 130 minutes. On the other hand, endoscopic tympanoplasty required an average of 100 minutes. Similar observations were made in two separate studies by Tarabichi M⁶ and Usami S, Iijima N et al.⁷ Describe 2 studies Moreover with angled endoscopes it is possible to visualize other structures like round window niche, sinus tympani, anterior epitympanum, eustachian tube area, facial recess, which are difficult to visualize with microscope.

By avoiding postaural incision in endoscope group, there is less dissection of normal tissues, less intraoperative bleeding, less incidence of postoperative pain, and better cosmetic result.

In this series, almost 100% of microscope assisted tympanoplasty group and 90% of endoscope assisted

tympanoplasty group showed an average CHL of range 11–30 dB preoperatively. At the end of 6 months of follow-up, almost 90% of both the groups had an improvement in CHL with average between 0 and 20 dB CHL. Regarding graft uptake rate, 26 (86%) patients had a successful outcome (intact graft) in the endoscope group and 27 (90%) patients had a successful outcome in microscope group at 6 months follow-up.

Our findings are quite similar to the results of Gaur et al where 26 (88%) patients in the endoscope group and 27 (90%) patients in microscope group had intact graft.

Our results are partly similar to the observations of Raj A, Maher R et al⁸ where they compared the outcomes of endoscopic transcanal myringoplasty with that of myringoplasty using microscope. They showed that graft uptake is 90% in endoscopic method and 85% in microscopic method but there was no significant difference between the gain in the air bone gap in either group.

Study conducted by Harugop AS, Mudhol RS, Godhi A⁹ on a comparative study of endoscope assisted myringoplasty and microscope assisted myringoplasty done between 2003 to 2006 concluded that surgical outcome of endoscope assisted myringoplasty was comparable to that of the conventional microscope assisted myringoplasty. But in terms of cosmetic ground the patients in endoscope group had better result. In this study it was observed that the results are at par with the work of previous worker. Objective analysis revealed that in endoscope group none (0%) of the patients had a visible scar, whereas in the microscope group, 21 (70%) patients had a cosmetically acceptable scar.

Discussing the demerits:- The biggest disadvantage is that, endoscopic ear surgery is a one handed technique. Surgeon has to hold the scope in one hand during all the time while only one hand is free to operate. At time of excessive bleeding it becomes extremely difficult to operate as only one hand is free. Moreover blood soils the tip of endoscope which obscures the surgical field. Thus tip of endoscope has to be cleaned frequently, where as in microscopic technique both hands are free to operate. Thus procedure is easily performed in microscopic technique. Similar observation was made in studies of Tarabichi M¹⁰ and Karhuketo TS, Ilomaki JH, Puhakka HJ.¹¹ So, while performing endoscopic tympanoplasty meticulous hemostasis is must for doing smooth surgeries. This problem can be solved by developing a stand for endoscope, which can fix the scope in desired position so both hands are free to operate. Endoscopes provide monocular vision which leads to loss of depth perception so one has to be extra careful, while close to vital structures and positioning of the graft. This difficulty may be overcome by experience.

CONCLUSION

In this study, the success rate of endoscope assisted type I tympanoplasty was comparable to that of microscope assisted tympanoplasty. In terms of cosmetic and post-operative recovery, endoscope produced superior results without

added expenditure. Loss of depth perception and one handed technique are some of the disadvantages of the endoscope that can be easily overcome with practice. Endoscope is ideal for ear surgery camps held in remote places. Finally it can be concluded that the type I tympanoplasty by endoscopic technique had a definite and important role in ear surgery.

REFERENCES

1. William P.L. Hellier Chronic otitis media. In: Scott-Brown's Otorhinolaryngology Head and Neck Surgery, 8th ed. Vol. II, CRC Press, Taylor and Francis Group, Boca Raton London New York 2018. p. 155-164.
2. Wullstein H. Technic and early results of tympanoplasty. *Monatsschr Ohrenheilkd Laryngorhinol* 1953;87:308-11.
3. Zollner F. Surgical technics for the improvement of sound conduction after radical operation. *Arch Ital Otol Rinol Laringol* 1953;64:455-68.
4. Committee on Conservation of Hearing, American Academy of Ophthalmology and Otolaryngology. Standard classification for surgery of chronic ear disease. *Arch Otolaryngol* 1965;81:204.
5. Gaur RS, Tejavath P, Chandel S. Comparative study of microscopic-assisted and endoscopic-assisted myringoplasty. *Indian J Otol* 2016;22:177-82.
6. Tarabichi M. Endoscopic transcanal middle ear surgery. *Indian Journal Of Otolaryngology and Head and Neck Surgery* 2010;62:6-24.
7. Usami S, Iijima N, Fujita S, Takumi Y. Endoscopic - Assisted myringoplasty. *ORL J Otorhinolaryngol Relat Spec*. 2001;63:287-90.
8. Raj A, Meher R Endoscopic transcanal myringoplasty: A study. *Indian journal of otolaryngology and head and neck surgery*. 2001;53:47-9.
9. Harugop AS, Mudhol RS, Godhi A. Comparative study of endoscope assisted myringoplasty and microscope assisted myringoplasty. *Indian Journal of Otolaryngology and Head and Neck surgery*. 2008;60:298-302.
10. Tarabichi M. Endoscopic middle ear surgery. *Ann Otol Rhinol Laryngol* 1999;108:39-46
11. Karhuketo TS, Ilomaki JH, Puhakka HJ. Tympanoscope-assisted myringoplasty. *ORL J Otorhinolaryngol Relat Spec* 2001; 63: 353-7.

Source of Support: Nil; **Conflict of Interest:** None

Submitted: 05-09-2018; **Accepted:** 08-10-2018; **Published:** 19-10-2018