

# A Randomized Control Study to Evaluate (0.25%) Bupivacaine and (0.5%) Ropivacaine for Post Operative Analgesia using Transversus Abdominis Plane Block (TAPB) in Lower Segment Caesarean Section

Chavi Sethi<sup>1</sup>, Roopesh Kumar<sup>2</sup>, Pradeep Sahi<sup>3</sup>, Amreen Fatima<sup>4</sup>

## ABSTRACT

**Introduction:** Patient undergoing caesarean section suffer significant postoperative pain. Transversus Abdominis Plane Block is an effective method of providing postoperative analgesia in patient undergoing lower segment caesarean section. We evaluated the efficacy of (0.25%) Bupivacaine and (0.5%) Ropivacaine for providing effective postoperative analgesia using TAPB in lower segment caesarean section.

**Material and Methods:** Randomized controlled double blinded study was carried out in 90 female patients belonging to ASA grade 1 or 2, aged 20 - 35 years undergoing lower segment caesarean section. Patients were randomly allocated in two groups of 45 each (n=45). After all aseptic precautions patients were administered subarachnoid block bupivacaine heavy (0.5%) , 10mg, by 25G Whitacre spinal needle. After completion of surgery , they received TAP block with

Group 1- 0.5% ropivacaine (1.5mg/kg)

Group 2-0.25% bupivacaine (1mg/kg)

Patients were monitored for Visual Analogue scale (VAS) ,heart rate, blood pressure, SpO<sub>2</sub>, nausea ,vomiting, need of supplemental analgesia with in 24 hours.

**Results:** After LSCS the Transversus Abdominis Plane Block with 0.5% ropivacaine reduced postoperative Visual Analog Scale pain scores compared to 0.25% Bupivacaine.

**Conclusion:** 0.5% Ropivacaine provide better and long duration of analgesia as compared with 0.25% Bupivacaine and also decrease first 24 hours analgesic requirement postoperatively.

**Keywords:** Transversus Abdominis Plane Block, Spinal anaesthesia, Bupivacaine, Ropivacaine.

## INTRODUCTION

Postoperative pain is the most dreaded problem which a patient fears after any surgery. A major component of this pain is derived from the abdominal wall incision, which is innervated by nerve afferents that course through transversus abdominis neuro-fascial plane. The Usual trend was to prescribe an opioids or a NSAIDS for postoperative analgesia. Each of which has its own side effects like sedation, nausea, vomiting etc.

The transversus abdominis plane (TAP) block, a newly developed block, is effective Regional Analgesic Technique and Peripheral site of action used to provide analgesia to the anterior and lateral abdominal wall with minimal systemic side effects<sup>1</sup>.

In this block, the lumbar triangle of Petit is used as a landmark for injecting local anaesthetic into the neurovascular plane of the abdominal wall, located between the internal oblique and

the transversus abdominis muscles<sup>1,2</sup>. Nerves supplying the anterior abdominal wall are derived from T6 to L1 and pass through this plane before supplying the anterior abdominal wall. In addition, anatomical dissections have demonstrated that in this plane, the T6–L1 communicate closely and branch widely with neighbouring segmental nerves.

Study aimed to compare (0.25%) bupivacaine and (0.5%) ropivacaine in relieving postoperative pain after LSCS by TAP block.

## MATERIAL AND METHODS

After institutional ethical committee approval a prospective Double blind, Randomized Controlled Trial study, 90 female patients were selected after informed and written consent and allocated into two groups using computerized random number table-

**Group 1** - 0.5% Ropivacaine 20ml (n=45)

**Group2** - 0.25% Bupivacaine 20ml (n=45)

**Inclusion criteria:** ASA I/II primi gravida, Aged 20-35 years, BMI 18- 30 kg/m<sup>2</sup>, Elective LSCS by pfannenstiel incision, Able to understand the Pain Scales utilized.

**Exclusion criteria:** Patient's refusal, Patients who had prior epidural placed for labour analgesia, Nerve injury /Known allergy to drugs, Any post caesarean complications like bleeding

After securing intravenous line, all patients were preloaded with Inj. Ringer lactate solution 10-15ml/kg. and premedicated with i.v. ranitidine (50mg) and i.v. metaclopramide (10mg). Standard monitoring baseline pulse, non invasive blood pressure, oxygen saturation probe and ECG was attached. After all aseptic precautions patients were administered subarachnoid block with bupivacaine heavy(0.5%), 10mg, at L3-L4 vertebral interspace by 25G spinal needle.

<sup>1</sup>Assistant Professor, <sup>2</sup>Professor and Head, <sup>3</sup>Professor, <sup>4</sup>Junior resident 2<sup>nd</sup> Year, Department of Anesthesiology, Maharani Laxshmi Bai Medical College, Jhansi, Uttar Pradesh, India.

**Corresponding author:** Roopesh Kumar, Professor and Head, Department of Anesthesiology, Maharani Laxshmi Bai Medical College, Jhansi, Uttar Pradesh, India.

**How to cite this article:** Chavi Sethi, Roopesh Kumar, Pradeep Sahi, Amreen Fatima. A randomized control study to evaluate (0.25%) bupivacaine and (0.5%) ropivacaine for post operative analgesia using transversus abdominis plane block (TAPB) in lower segment caesarean section. International Journal of Contemporary Medical Research 2018;5(6):F7-F10.

**DOI:** <http://dx.doi.org/10.21276/ijcmr.2018.5.6.12>

The study solution was prepared in two identical syringes, patient and anesthesiologist remained unaware of the nature of study and was not involved in further data collection. After completion of surgery TAP block was performed Bilaterally by Landmark Technique using the Double loss-of-resistance.

A 22 gauge 5-8 cm long, blunt tipped, short bevelled needle was inserted in lumbar triangle of petit, just posterior to mid- axillary line perpendicular to skin. And the transversus abdominis fascial plane is localized with a two-‘pop’ sensation (or loss of resistance). The first ‘pop’ indicates penetration of the fascia of the external oblique muscle and the second ‘pop’ indicates penetration of the internal oblique muscle and thereby entering the transversus abdominis fascial plane. 20ml of local anesthetic solution was injected on each side, after negative aspiration. Thus blocking the sensory nerves before innervating the different muscles of the anterior abdominal wall. This ‘blind’ TAP block technique is described as easy to perform and with few complication.

Patients were observed for 15 min for any adverse reaction. Then transferred to the post anesthesia care unit(PACU).

#### Patients were observed for-

**Primary Study Criteria-** Compare analgesic efficacy of 0.25% Bupivacaine and 0.5% Ropivacaine by Visual Analog Scale. <sup>1</sup>

**Secondary Study Criteria-** Hemodynamic response (PR, MAP) 24hr analgesic requirement and any other side effects. any patient with VAS Score >4 (or on demand)was given inj. PCM 15mg/kg i.v. to a max. of 3 doses in 24 hours.

Sample size was calculated using standard deviation of 30 mm as a standard deviation of VAS score in the population. Patients in each group would be needed, assuming the probability of alpha ( $\alpha$ ) error is 5% and a power of the study is 90%. 90 patients were recruited.

#### STATISTICAL ANALYSIS

Statistical software SPSS, version 16.0 unpaired t-test for parametric data, Chi-square test for non-parametric data. p value < 0.05 -statistically significant, p value < 0.01-statistically highly significant.

#### RESULTS

90 Patients were included in the study, all patients were undergoing Lower segment caesarean section. The baseline of the two groups were not significantly different (table-1). In group 1, mean duration of surgery was 30.1±3.68 minutes whereas in Group 2 it was 28.9±4.56 minutes (fig1). Demographic parameters (table 1 and duration of surgery in both the groups were comparable - p>0.05).

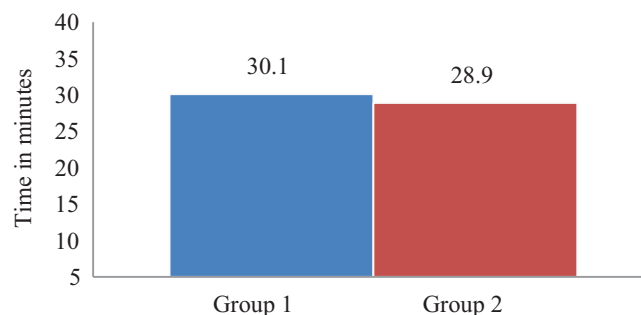
No statistically significant changes in pulse rate (fig 2) and blood pressure(fig 3) between two groups in first 6 hours (p>0.05).

Statistically significant difference in VAS Score at 4hrs (p<0.05) and 12(p<0.01) during rest after performing the block (fig 4).

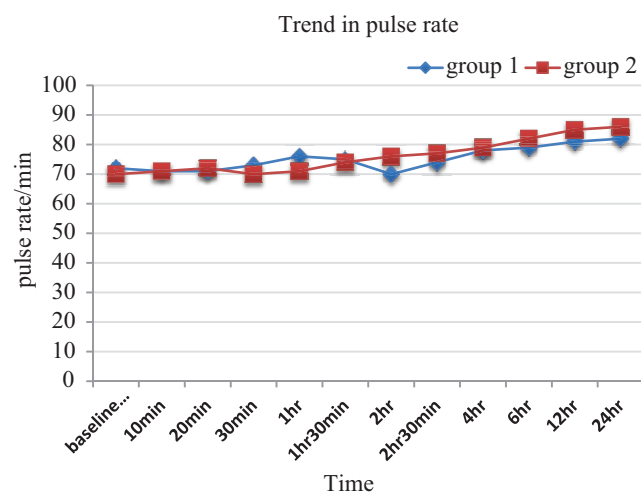
Statistically significant difference in VAS Score at 4hrs

PARAMETER	Group 1 (n=45)	Group 2 (n=45)
Age (years)	28± 4.56	26±5.86
Weight (kg)	50.26±7.32	51.93±7.76
ASA grade I/II	35/10	39/6

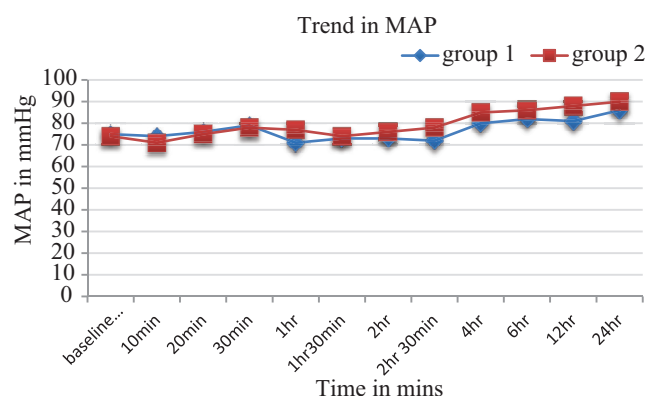
**Table-1:** Demographic parameters



**Figure-1:** Mean distribution surgery



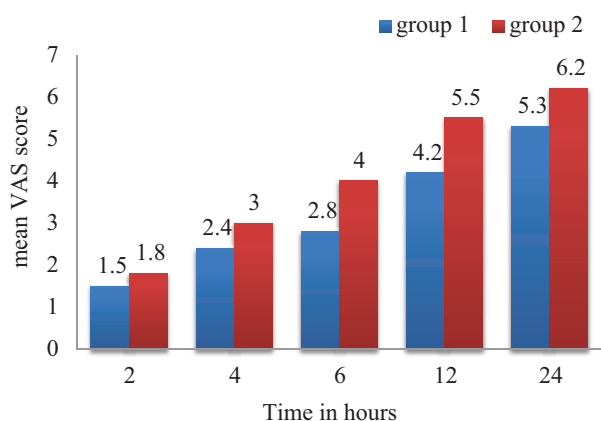
**Figure-2:** Trend in pulse rate in both groups in different intervals



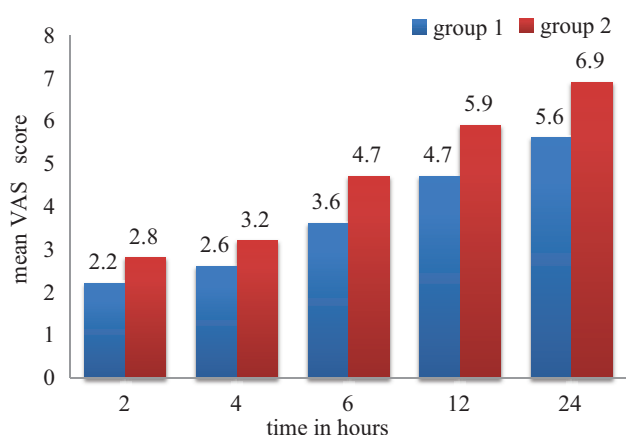
**Figure-3:** blood pressure changes in both groups in different intervals

(p<0.05) and 12 (p<0.01) after performing the block during movement (fig-5).

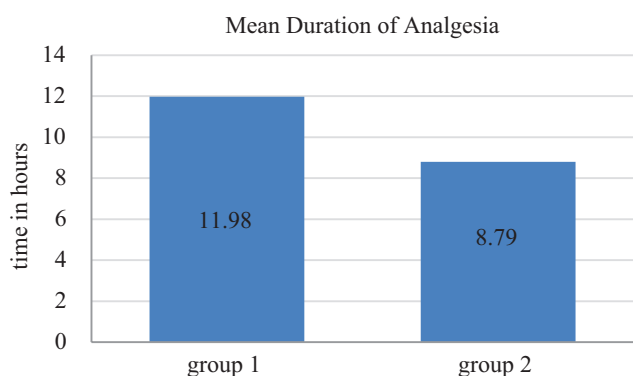
Mean duration of analgesia was 11.98±1.76 hrs in Group 1 and 8.79±1.20 hrs in Group 2. That was highly significant in Group 1 as compared to Group 2 (p<0.01). (fig 6)



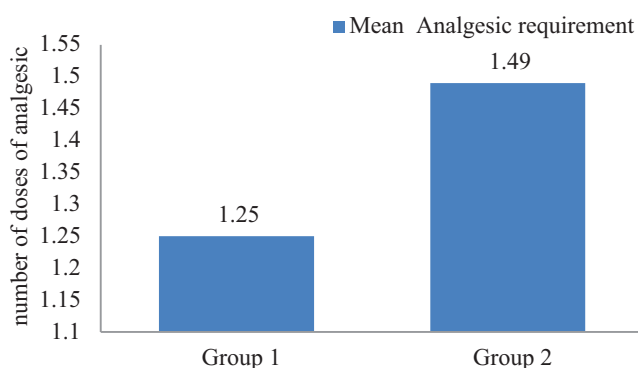
**Figure-4:** Mean Visual Analogue Scale score (VAS) at different time interval during Rest



**Figure-5:** Mean Visual Analogue Scale (VAS) at different time interval during movement (coughing).



**Figure-6:** total duration of analgesia



**Figure-7:** Post Operative Analgesic Consumption in 24 hours

None of the patients in either group had any side effects.

### DISCUSSION

Post operative pain is the most dreaded problem one suffer. In recent Years TAPB is emerging regional analgesic technique for pain and is gaining popularity as for post operative analgesia<sup>3-5</sup>. Transversus Abdominis Plane Block (TAPB) is a volume block, hence selection of drug is very important. Ropivacaine a new amino amide LA and exists as an S-enantiomer, has low systemic toxicity than Bupivacaine and equi-effective doses of the two are Ropivacaine 0.5% and Bupivacaine 0.25%. TAPB provide effective postoperative analgesia reflected by a lower VAS score both at rest and activity and decrease rescue analgesic requirement.

In this study, Paracetamol was the single analgesic given to patient, if post operative analgesia was required. Our finding is consistent with those of McDonnell et al. in abdominal surgery<sup>2</sup> and Carney et al. in open appendicectomy. Sharma et al. also found that TAPB by landmark technique improves VAS score in first 24 hours in patients undergoing major abdominal surgeries<sup>9</sup>.

Difference in rise in PR and BP after 6 hours is more in group 2 because longer duration of analgesia was maintained in group 1 by 0.5% ropivacaine. Prolonged duration of analgesic effect (12 to 24hrs) after TAP Block is not entirely clear.

This is in accordance with the study of Carney, as Transversus abdominal plane is relatively poorly vascularized area and therefore drug clearance is slow<sup>8</sup>.

In our study, duration of post-operative analgesia was 11.98 hours in group 1 and 8.79 in group 2. The difference was statistically highly significant (p<0.01).

Imp clinical implication of TAPB are opioid-sparing effect of TAPB and relatively safer alternative to neuraxial block in patients having coagulopathy.

There are few limitations of this block like effect of block dependent on the experience, technique used, and patient anatomy, absence of effectiveness for visceral pain and postoperative pain was studied for 24 hrs only.

Accidental intravascular injection of local anesthetic and infection can also be considered as potential complication of TAP Block. No side effects were noted in present study.

### CONCLUSION

0.5% Ropivacaine when compared with 0.25% bupivacaine, provides a longer duration of analgesia using TAPB, with a better safety profile and can be used as a alternative to Bupivacaine, in LSCS where parietal wall pain forms the major component<sup>7</sup>.

### REFERENCES

1. McDonnell JG, O'Donnell BD, Farrell T, Gough N, Tuite D, Power C, Laffey JG. Transversus abdominis plane block: a cadaveric and radiological evaluation. *Reg Anesth Pain Med* 2007;32:399-404.
2. McDonnell JG, O'Donnell B, Curley G, Heffernan A, Power C, Laffey JG. The analgesic efficacy of transversus abdominis planeblock after abdominal

- surgery: a prospective randomized controlled trial. *Anesth Analg* 2007;104:193–7.
3. McDonnell JG, Curley G, Carney J, Benton A, Costello J, Maharaj CH, Laffey JG. The analgesic efficacy of transversus abdominis plane block after cesarean delivery: a randomized controlled trial. *Anesth Analg* 2008;106:186–91.
  4. O'Donnell BD, McDonnell JG, McShane AJ. The transversus abdominis plane (TAP) block in open retropubic prostatectomy. *Reg Anesth Pain Med* 2006;31:91.
  5. Moiniche S, Mikkelsen S, Wetterslev J, Dahl JB. A qualitative systematic review of incisional local anaesthesia for postoperative pain relief after abdominal operations. *Br J Anaesth* 1998;81:377–83.
  6. Local Anesthetics. In: Sweetman SC, ed. *Martindale: The Complete Drug Reference*. London, UK: Pharmaceutical Press, 2007:1690–713.
  7. Shibata Y, Sato Y, Fujiwara Y, Komatsu T. Transversus abdominis plane block. *Anesth Analg* 2007;105:883
  8. Carney J, McDonnell JG, Ochana A, Bhinder R, Laffey JG. The transversus abdominis plane block provides effective postoperative analgesia in patients undergoing total abdominal hysterectomy. *Anesthesia and Analgesia* 2008; 107: 2056–60.
  9. Sharma P, Chand T, Saxena A, Bansal R, Mittal A, Shrivastava U. Evaluation of postoperative analgesic efficacy of transversus abdominis plane block after abdominal surgery: A comparative study. *J Nat Sci Biol Med*. 2013;4:177-80.

**Source of Support:** Nil; **Conflict of Interest:** None

**Submitted:** 23-05-2018; **Accepted:** 25-06-2018; **Published:** 06-07-2018