

# Dynamic Hip Screw and Proximal Femoral Nail as a Mode of Surgical Treatment in Intertrochanteric Fractures of Femur in Elderly Patients

Shivraj S. Konde<sup>1</sup>, Santosh S. Borkar<sup>2</sup>, Rohit Shinde<sup>3</sup>, Abhijit Marathe<sup>4</sup>, Prashant Kamath<sup>5</sup>

## ABSTRACT

**Introduction:** Advanced fast growing technology and high velocity transport media has increased the number of injuries in the recent years. There are number of devices but there is not a single one which can be used with confidence and full reliance. Hence we did a study of 50 cases of intertrochanteric femur fractures to find better implant between DHS and PFN.

**Material and Methods:** We conducted a prospective study of 50 cases of intertrochanteric fractures of femur presented at MIMER medical college Talegaon after due consent and ethical committee approval. 25 cases were operated with DHS and 25 cases operated with PFN under spinal with epidural or general anaesthesia in supine position on fracture table. Patients were followed up clinically and radiologically at 1 month, 3 months, 6 months and 1 year.

**Results:** There was no significant difference between two groups of patients as regards to age, sex, duration of surgery, time taken for union and harris hip score etc but there was significant difference as regards to period of hospitalization ( $p=0.014$ ) and blood transfusion ( $p=0.004$ ).

**Conclusion:** There is no significant difference between results of PFN AND DHS as far as results of surgical treatment are concerned and both are equally effective to treat intertrochanteric femur fractures however there could be advantages of PFN over DHS because of less blood loss and early rehabilitation and discharge from hospital.

**Keywords:** Intertrochanteric Femur Fractures, DHS, PFN

## INTRODUCTION

Advanced fast growing technology and high velocity transport media has increased the number of injuries in the recent years. Intertrochanteric fracture is one of them. This has changed the pattern of Intertrochanteric fracture so much that there is no one treatment which can be agreed upon.<sup>1</sup>

Also due to increased life span and due to increased osteoporosis in old age the rate of Intertrochanteric fractures has increased.<sup>2</sup>

Anatomical and biomechanical factors play an important role in healing of this fracture. This fracture combines the problems of both upper shaft and trochanter of the femur. Non operative treatment is often unsuccessful as it often results in complications like varus deformity, shortening and other hazards of immobilization such as deep vein thrombosis, hypostatic pneumonia, pressure sores, dehydration etc. It is very rarely used now days unless there is absolute contraindication on internal fixation.<sup>3,4</sup>

### Boyd and griffin classification

They classified fractures in the peritrochanteric area of the femur in to 4 types. Their classification included all fractures

from the extracapsular part of the neck to a point 5 cm distal to lesser trochanter.

Type 1: Fractures extending along intertrochanteric line from lesser to greater trochanter.

Type 2: Comminuted fractures, the main fractures being along the intertrochanteric line but with multiple fracture in the cortex.

Type 3: Fractures that are basically sub-trochanteric, with at least one fracture line passing across the proximal end of the shaft just distal to or at the lesser trochanter varying degrees of comminution are seen.

Type 4: Fractures of trochanteric region and the proximal shaft, with fracture in at least two planes.<sup>4</sup>

Intertrochanteric fractures of the femur readily unite no matter what treatment is used because most of it is cancellous bone, has a good blood supply and muscle coverage. If non union occurs it is always due to interposition of soft tissue.<sup>5</sup> Many surgeons have introduced a number of new devices but there is not a single one which can be used with confidence and full reliance. Ongoing efforts to find an acceptable implant have resulted in a wide variety of implants having some advantages and disadvantages.<sup>6</sup> Here is a study of 50 cases of Intertrochanteric fractures. The goal was to find the better implant between dynamic hip screw and proximal femoral nail while treating these fractures.

An intramedullary location of PFN provides efficient load transfer and limits the amount of sliding and therefore limits shortening and deformity that can occur. Shorter lever arm of intramedullary device decrease tensile strain on the implant and thereby decrease the risk of implant failure, because the intramedullary fixation device incorporates a sliding hip screw, the advantage of controlled fracture impaction is maintained.<sup>7</sup> Therefore we decided to carry out the study to compare the results of dhs and pfn in intertrochanteric fractures.

This study and foregoing studies, we hope will help in better

<sup>1</sup>Associate Professor, Department of Orthopaedics, <sup>2</sup>Professor, Department of Orthopaedics, <sup>3</sup>Resident, Department of Orthopaedics, <sup>4</sup>UG Student, <sup>5</sup>Professor and Head of Department, MIMER Medical College, Talegaon, India

**Corresponding author:** Dr. Santosh S. Borkar, 7 Aryan Capital, Wada road, Rajgurunagar, Taluka Khed, District Pune 410505, India

**How to cite this article:** Shivraj S. Konde, Santosh S. Borkar, Rohit Shinde, Abhijit Marathe, Prashant Kamath. Dynamic hip screw and proximal femoral nail as a mode of surgical treatment in intertrochanteric fractures of femur in elderly patients. International Journal of Contemporary Medical Research 2018;5(4):D4-D7.

**DOI:** 10.21276/ijcmr.2018.5.4.30

management, decreasing the complications and will help in evaluating new modes in the path and will lead to a general consensus.

**MATERIAL AND METHODS**

Our study was carried out at MIMER Medical College. 50 patients were admitted from Jan 2014 to Jan 2017. Prospective randomised controlled trial was carried out. We included all four types of Boyd and Griffin classification. All fractures were acute and closed and patients were above 50 years of age. We excluded pathological fractures and fractures more than 3 weeks old after injury. Ethical committee approval was taken from local ethical committee of MIMER Medical College, Talegaon. Patients consent was taken in prescribed format for inclusion in the study

The methods used for fixation of fractures of Intertrochanteric femur were proximal Femoral Nailing (PFN) and Dynamic hip screw (DHS). The results of both were compared. The duration of follow up-ranged from 6-24 months.

Proximal locking is achieved through one anti-rotation bolt or stabilization screw and one femoral neck screw or cervical screw. PFN, a third generation cephalomedullary nail, is a load sharing intramedullary device which lies within weight bearing axis of lower extremity and is always resisting a varus directed force of high magnitude. It allows axial forces to be transmitted to the opposed ends of bone fragments. More stiffness causes less deformation of construct. This leads to smaller displacement of fragment and hence more favorable healing.

The cases were operated on fracture table under spinal anaesthesia, lateral approach for DHS and trochanteric entry was taken for the PFN.

Five days antibiotics course was completed. Analgesics are given for same period and strictly recorded. Shifted to oral after that till stitch removal. Hip and knee physiotherapy started on 2<sup>nd</sup> postoperative day in sitting position.

Patients were kept non-weight bearing for approximately 6 weeks after stabilization of fracture.

At the end of 6 weeks partial weight bearing advised and full weight bearing allowed after the appearance of calcified external callus

Each patient is followed up clinically and radiologically at 1 month, 3months, 6 months and 1year. Range of movement at hip and knee on both sides were compared. Radiographs were taken to assess union and residual angulations at fracture site. Also, gait of patient analyzed and limb length measurement done.

The final outcome of the study was analyzed only after 1 year follow up.

An objective questionnaire on the basis of Harris Hip Score was calculated for functional outcome. Radiological assessment was done based on fracture union, varus valgus malalignment, complications like screw cut out, implant breakage or aseptic loosening. Depending on these criteria, results were graded

**STATISTICAL ANALYSIS**

Results were analysed using t test and XLSTAT software.

**RESULTS**

**Gender Distribution**

Figure No.1 depicts the gender distribution of the 50 patients treated. In the PFN group, 44% were males while 56% were females. In the DHS group, 56% were males while 44% were females. *P* value= 0.311

**Comparison of age (in years) in groups PFN and DHS**

Figure No. 2 depicts the mean age (in years) of the 50 patients treated. In the PFN group, mean age was 73.08 ± 10.5748. In the DHS group, mean age was 70.48 ± 11.948. *P* value= 0.419

**Comparison of periods of hospitalization of patients in groups PFN and DHS**

Figure No. 3 depicts the period of hospitalization in both

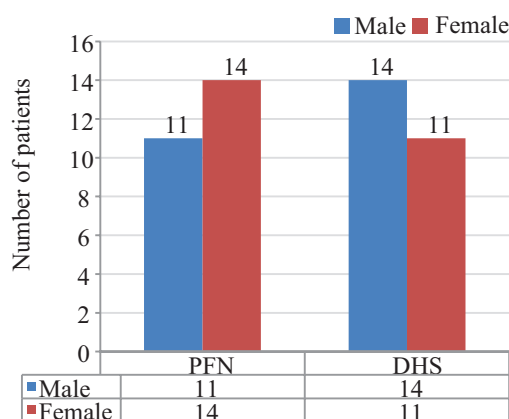


Figure-1: Gender Distribution

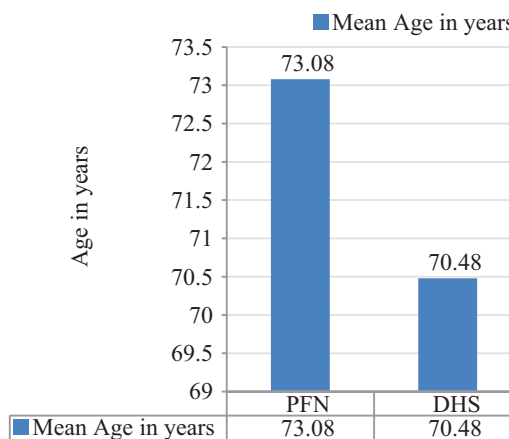


Figure-2: Mean Age in years

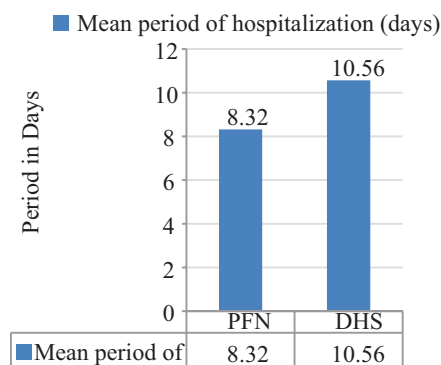


Figure-3: Mean period of hospitalization (days)

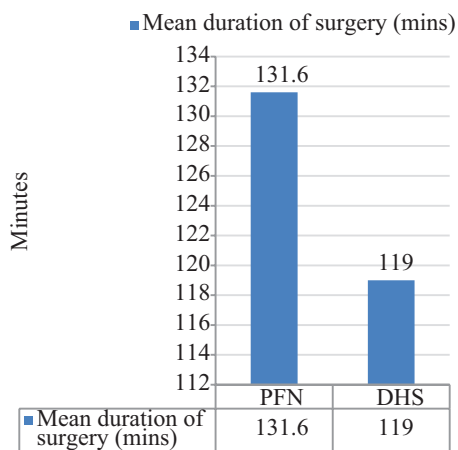


Figure-4: Mean Duration of Surgery

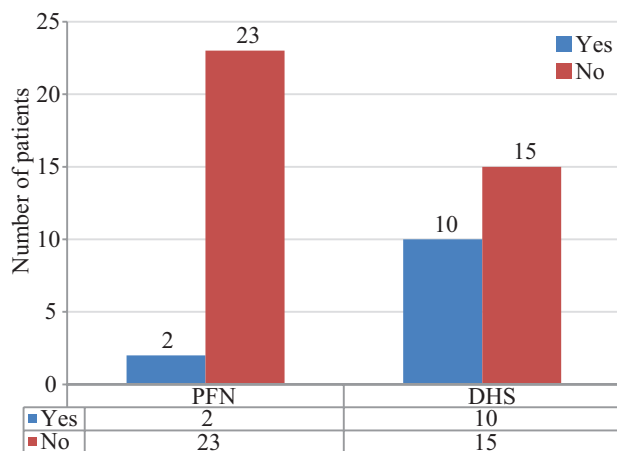


Figure-5: Proportion of Patients requiring Blood Transfusion

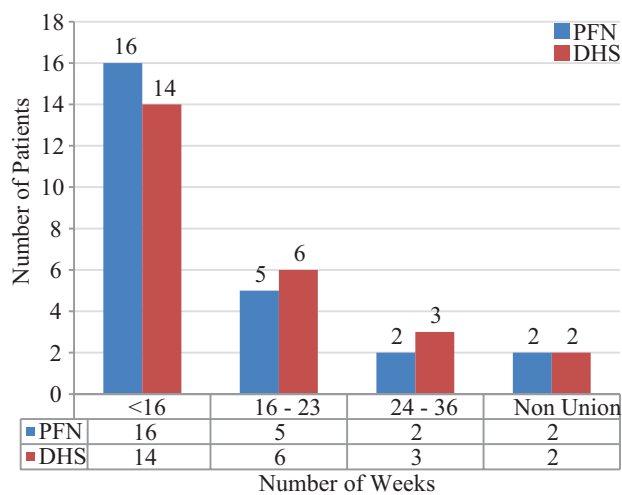


Figure-6: Time Taken for Union of Fractures

groups. In the PFN group, mean period was  $8.32 \pm 2.59$ . In the DHS group, mean period was  $10.56 \pm 3.55$ . By using 2 sample t-test,  $P$  value= 0.014 ( $< 0.05$ ). Therefore, there is a significant difference between the PFN and DHS groups with respect to period of hospitalization.

#### Comparison of Duration of Surgery (in min.) in PFN group and DHS group

Figure No. 4 depicts the duration of surgery (in min.) in both groups. In the PFN group, mean duration was  $131.6 \pm 30.4$ .

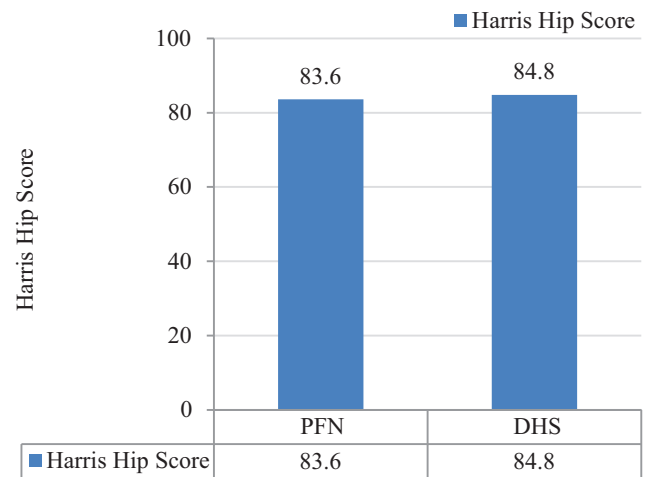


Figure-7: Harris Hip Score

In the DHS group, mean age was  $119.0 \pm 40.6$ .  $P$  value= 0.221

#### Distribution of Patients with respect to Blood Transfusion

Figure No. 5 depicts the number of patients requiring blood transfusion in both groups. In the PFN group, 2 patients (8%) required blood transfusion, while 23 (92%) did not. In the DHS group, 10 patients (40%) required blood transfusions while 15 (60%) did not.

By using 2 sample proportion t-test,  $P$  value= 0.004 ( $< 0.05$ ). Therefore, there is a significant difference between the proportions of requirement of blood transfusion in PFN and DHS groups.

#### Distribution of Patients with respect to time taken for Union of fractures in groups PFN and DHS.

Figure No. 6 depicts the time taken for union of fractures in both groups.

$P$  value= 0.935

#### Comparison of Harris Hip Score of Patients in PFN group and DHS group

Figure No. 7 depicts the Harris Hip Score in both groups. In the PFN group, H.H.S. was  $83.6 \pm 14.2$ . In the DHS group, mean age was  $84.8 \pm 11.8$ .

$P$  value= 0.738

From the above results, it can be gauged that there was no significant difference between the two groups with regard to age, sex, time for union, duration of surgery, Harris Hip Score. However, there were significant differences between the two groups with respect to blood transfusion and hospital stay, both of which were significantly less in the PFN group as compared to the DHS group.

## DISCUSSION

In this study of 50 patients, the mean in PFN and DHS group was 73.08 years and 70.48 years (overall mean 71.78 Years) respectively. In our series the sex incidence was equal. The mean period of hospitalization was 8.32 days in the PFN group, which was less than 10.56 days seen in the DHS group. This difference was not significant, but could be attributed to early mobilization and also due to the smaller post operative scar which enabled earlier suture removal.

Similar results were also seen in Sadowski series.<sup>8</sup> In our series the mean duration of surgery in PFN group was 131.6 minutes whereas it was 119 minutes in DHS group. These results do not correspond to Sadowski series which show the operative duration to be shorter in PFN group.<sup>8</sup> This might be due to the fact that proximal femoral nailing is technically a more demanding procedure with a steep learning curve. In our series out of 25 cases of DHS, 23 united primarily as defined by dispersion of fracture line. Out of 23 cases, 14 cases (56%) united in less than 16 weeks and 9 united in less than 36 weeks. We found 2 cases of non union. Out of 25 cases of proximal femoral nailing, 16 cases (64%) united in less than 16 weeks, 5 cases united in 16 - 24 weeks and 2 cases united in to 24-36 weeks. Non union was seen in 2 cases, which were due to distraction at fracture site due to faulty technique. It was seen in our series that the patients requiring blood transfusion were five times higher in the DHS group (40%) as compared to the PFN group (8%). These can be attributed to the smaller scar and less soft tissue dissection. Similar results were observed in the Sadowski series. In our series, we have observed 4 non-unions, 2 each in proximal femoral nailing and dynamic hip screw i.e. 8% each. The persistent non-union was associated with inappropriate reduction. In our study, closed reduction was not achieved in 10% which is comparable to the study done by Boldin et al i.e. 10%.<sup>7</sup> No cutout was seen in our study, while in the study of Boldin et al, 2 cases i.e. 3.63% were seen, which he described to be due to wrong selection of screws. Thus, it appears from our study that intra operative complications were more common with PFN, while postoperative complications were equal in either case.

Over the years operative techniques have evolved and currently dynamic hip screw with plate and proximal femoral nail are popular among orthopaedic surgeons.<sup>9,10</sup> DHS requires wide surgical exposure and causes significant blood loss but has stood the test of time with few known complications like varus malunion, implant cut out or nail breakage.<sup>11,12,13</sup>

### Harris Hip Score

H.H.S is an objective tool which allows the surgeon to rapidly assess the post operative function of the patient. However, it has one shortcoming. The score does not allow for individual differences based on age, health or other personal issues that may affect the total score.(e.g. asthma, PVD)

However in our series we observed similar result in both groups. A mean score of 83.6 in PFN group and 84.8 in DHS group.

### CONCLUSION

Besides advantages of minimally invasive surgical approach like less blood loss and early discharge from hospital, there is no significant difference between results of DHS with side plate compared to proximal femoral nail for management of intertrochanteric fracture femur. However our sample size was small and we did follow up for limited period and hence can not draw definite conclusion of one implant superiority over the other as both implants are equally effective in our

series.

### REFERENCES

1. Kenneth J. Koval, Robert V. Cantu; Intertrochanteric Fractures, Rockwood and Green's Fractures In Adults, 8th edition, Lippincott Williams and Wilkins, 2014. Pg 2075
2. John C Weinlein, Fracture and Dislocation of Hip, In:KAY DAUGHERTY and LINDA JONES, editors;Campbell Operative Orthopaedics, 12<sup>th</sup> edition, volume3, Elsevier Mosey, 2013, Pg 2737.
3. J.N. Wilson, Injuries Of the Hip, In: J.N. Wilson, Watson Jones fractures and joint surgeries, 7<sup>th</sup> ed, Volume 3, Elsevier Mosey, 2016, 1172.
4. Boyd H, Griffin LL. Classification and treatment of trochanteric fractures. Arch Surgery 1949;58:853-866.
5. Kannus P, Parkkari J, Sievänen H, et al. Epidemiology of hip fractures. Bone. 1996;18:57-63.
6. Nuber S, Schönweiss T, Rüter A. Stabilisation of unstable trochanteric femoral fractures. Dynamic hip screw (DHS) with trochanteric stabilisation plate vs. proximal femur nail (PFN) Unfallchirurg. 2003;106:39-47.
7. Boldin C, Seibert FJ, Fankhauser F, et al. The proximal femoral nail (PFN): a minimal invasive treatment of unstable proximal femoral fractures: a prospective study of 55 patients with a follow-up of 15 months. Acta Orthop Scand. 2003;74:53-58.
8. Saudan M, Lübbecke A, Sadowski C, et al. Pertrochanteric fractures: is there an advantage to an intramedullary nail?: a randomized, prospective study of 206 patients comparing the dynamic hip screw and proximal femoral nail. J Orthop Trauma. 2002;16:386-93.
9. Pires RE, Santana EO, Jr, Santos LE, et al. Failure of fixation of trochanteric femur fractures: clinical recommendations for avoiding Z-effect and reverse Z-effect type complications. Patient Saf Surg. 2011;22:17.
10. Pajarinen J, Lindahl J, Michelsson O, et al. Pertrochanteric femoral fractures treated with a dynamic hip screw or a proximal femoral nail: a randomised study comparing postoperative rehabilitation. J Bone Joint Surg Br. 2005;87:76-81.
11. Pan X-h, Xiao D-m, Lin B-w. Dynamic hip screws (DHS) and proximal femoral nails (PFN) in treatment of intertrochanteric fractures of femur in elderly patients. Chin J Orthop Trauma. 2004;7:785-89.
12. Papisimos S, Koutsojannis CM, Panagopoulos A, et al. A randomised comparison of AMBI, TGN and PFN for treatment of unstable trochanteric fractures. Arch Orthop Trauma Surg. 2005;125:462-68.
13. Zhao C, Liu D-y, Guo J-j. Comparison of proximal femoral nail and dynamic hip screw for treating intertrochanteric fractures. China J Orthop and Trauma. 2009;7:535-37.

**Source of Support:** Nil; **Conflict of Interest:** None

**Submitted:** 02-04-2018; **Accepted:** 01-05-2018; **Published:** 11-05-2018