

A Comparative Study of Functional Outcome of Extra Articular Distal End Radius Fracture Treated with Closed Reduction and Traditional Cast Immobilization Versus Closed Reduction with Percutaneous Pinning in Elderly Age

Shivraj S. Konde¹, Satvilkar Mohd. Zafer Noor Mohd.², Abhijit Marathe³, Santosh Borkar⁴, Prashant Kamath⁵

ABSTRACT

Introduction: Distal end radius fractures are the commonest fractures occurring in the upper extremity that account for 17% of all upper limb injuries. A review of literature shows unsatisfactory results by usual plaster cast method, with deformity in 60% and unsatisfactory results in 32% of patients. We decided to carry out a study comparing results of traditional cast versus percutaneous pinning in the elderly age group.

Material and Methods: A randomized, prospective comparative study was carried out at MIMER Medical College, Talegaon (D) from December 2014 to June 2016. After local ethical committee approval, informed consent was obtained from 60 patients, aged 50 and above with displaced but stable distal end radius extra articular fracture without joint incongruity. 30 patients were subjected to closed reduction and cast immobilization. 30 were subjected to closed reduction and percutaneous K wires. At each follow-up, X-rays were taken along with clinical examination.

Results: We got statistically significant differences in range of motion, VAS scores and loss of radial length between the two groups, showing that the closed reduction K-wire fixation group has better results. This was also seen comparing Saito chart and Lindstrom's criteria results of both groups. The only significant complication with K-wire fixation is pin tract infection, which resolved after K-wire removal, seen in 13% of patients.

Conclusion: Closed reduction and percutaneous K-wire fixation is safer, better and easier technique to maintain reduction in displaced, distal end radius fractures, with minimal complications.

Keywords: Reduction, Cast, Pinning, Wires, Radius

INTRODUCTION

Distal end radius fractures are the commonest fractures occurring in the upper extremity that account for 17% of all upper limb injuries.^{1,2} No other fracture has a greater potential to devastate hand function. A review of literature shows unsatisfactory results by usual plaster cast method, with deformity in 60% and unsatisfactory results in 32% of patients.³ Methods of closed reduction with additional fixation have been claimed to improve results. One of the methods is percutaneous Kirschner wires.^{4,5} The fracture remains a difficult problem to manage and hence, we decided to carry out a study comparing results of traditional

cast versus percutaneous pinning in the elderly age group in our institute. We also aimed to evaluate the effectiveness and complications of both the treatments in terms of pain, deformity, disability, range of motion, movements, grip strength and post operative infection.

MATERIAL AND METHODS

A randomized, prospective comparative study was carried out in the Orthopaedics Department of MIMER Medical College, Talegaon (D) from December 2014 to June 2016. After local ethical committee approval, informed consent was obtained from 60 patients, aged 50 and above with displaced but stable distal end radius extra articular fracture without joint incongruity. We excluded patients with intra articular distal end radius fractures, open fractures, dorsal comminution fractures, fractures with dorsal tilt more than 20 degrees, fractures with congenital or other forearm anomalies, history of previous wrist or forearm fractures. 30 patients were subjected to closed reduction and cast immobilization. 30 were subjected to closed reduction and percutaneous K wires.

For closed reduction with traditional cast immobilization, patients were taken in the operation theatre and under regional or general anaesthesia under C-arm guidance, reduction was obtained by using Agee's manoeuvre, soft roll was wrapped and below elbow cast was given from metacarpophalangeal joints to the proximal part of the forearm, sparing the thumb. For closed reduction with percutaneous pinning, after

¹Associate Professor, Department of Orthopaedics, ²Resident, Department of Orthopaedics, ³UG Student, ⁴Professor, Department of Orthopaedics, ⁵Professor and Head of Department, MIMER Medical College, Talegaon, India

Corresponding author: Dr. Santosh S. Borkar, 7 Aryan Capital, Wada Road, Rajgurunagar, Taluka Khed, District Pune 410505, Maharashtra, India

How to cite this article: Shivraj S. Konde, Satvilkar Mohd. Zafer Noor Mohd., Abhijit Marathe, Santosh Borkar, Prashant Kamath. A comparative study of functional outcome of extra articular distal end radius fracture treated with closed reduction and traditional cast immobilization versus closed reduction with percutaneous pinning in elderly age. International Journal of Contemporary Medical Research 2018;5(4):D1-D3.

DOI: 10.21276/ijcmr.2018.5.4.29

reduction and painting and draping, two crossed K wires were passed aiming to cross fracture lines in both planes under C arm guidance. Both K wires were then bent and cut, after which dressing was done.

Hand elevation was given for 24 hours during post-operative period along with intravenous antibiotics and analgesics. Thereafter, oral antibiotics and analgesics were given along with oral calcium supplements. However, those patients in closed reduction and cast immobilization group were not given antibiotics at all.

Patients were discharged thereafter and followed up at the end of first, second, fourth, sixth and twelfth weeks. At each follow-up, AP and lateral X-rays were taken along with clinical examination and findings were noted. Visual Analog Scale was measured for both the groups. Deformity and tenderness were measured in Saito charts for both the groups. The outcome of each fracture was quantified by Lindstrom's system for Lindstrom's Criteria for Anatomical End Result (LCAER) and Lindstrom's Criteria for Functional End Result (LCFER).

STATISTICAL ANALYSIS-

We analyzed the results using unpaired student's t-test, using XLSTAT software.

RESULTS

1. Mean Age (in years)

In the cast group, mean age (in years) was 63.43. In the K-wire group, mean age (in years) was 62.16. $P = 0.6097$

2. Gender Frequency

Table No. 1 depicts the gender frequency among the patients in the cast group and K-wire group.

3. Range of Motion

Table No. 2 depicts the range of motion seen in the cast group and K-wire group.

4. Complications

Table No. 3 shows the complications encountered in the cast group and the K-wire group.

5. Visual Analog Scale (VAS)

VAS was measured for both groups.

VAS for cast group was 5.6

VAS for K-wire group was 4.7

$P = 0.007$

6. Saito Score

Figure No. 1 depicts the Saito score in the cast group and K-wire group. Scores fall within two different categories

1. Excellent
2. Good/Fair

7. Lindstrom's Criteria for Anatomical End Result (LCAER)

Figure No. 2 depicts the results of patients in both groups, based on the four grades of the Lindstrom's Criteria for Anatomical End Result (LCAER)

8. Lindstrom's Criteria for Functional End Result (LCFER)

	Cast group	K-wire group	Total	Percentage
Male	12	07	19	31.66%
Female	18	23	41	68.33%

Table-1: Gender frequency

Motion	Cast group (in degrees)	K-wire group (in degrees)	P value
Dorsiflexion	63.33	69.66	$P \leq 0.0001$
Palmar flexion	55.83	64.83	$P \leq 0.0001$
Pronation	63	64.83	$P = 0.1$
Supination	66.5	69.33	$P = 0.007$

Table-2: Range of motion

Complication	Cast group	K-wire group
Finger Stiffness	04 (13%)	02 (07%)
Sudeck's Dystrophy	04 (13%)	03 (10%)
Osteoarthritis	06 (20%)	03 (10%)
Pin Tract Infection	0 (0%)	04 (13%)

Table-3: complications

	Cast group	Percentage	K-wire group	Percentage
Excellent	07	23%	21	70%
Good	23	77%	09	30%

Table-4: Lindstrom's Criteria

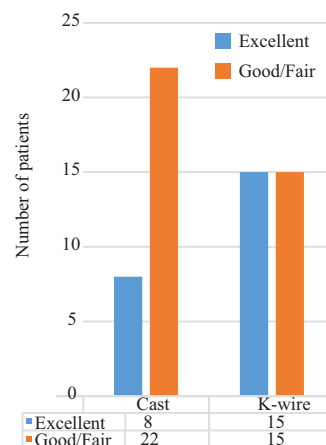


Figure-1: Saito Chart

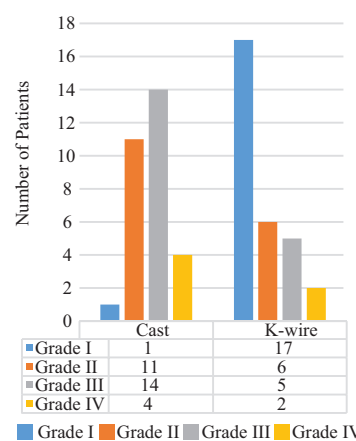


Figure-2: Lindstrom's Criteria for Anatomical End Result (LCAER)

Table No. 4 shows the results of patients in both groups, with respect to the Lindstrom's Criteria for Functional End Result (LCFER).

9. Loss of Radial Length

Mean loss of radial length in patients treated with closed reduction and cast = 6.83 mm

Mean loss of radial length in patients treated with closed reduction and K-wire = 3.8 mm

P < 0.0003

DISCUSSION

Distal end radius fractures have a higher incidence with aging, which is associated with all of the risk factors for osteoporosis.⁵ "Kreder" et al, in a two-year prospective study in 113 patients suggested that external fixation and percutaneous pinning fixation had better results compared to traditional cast immobilization.⁶ However, "Stoffelen" in a randomized clinical trial showed that there is no difference in results of patients who were treated with casting and patients who had percutaneous pinning procedures.⁷ The advantages of K-wire pinning fixation of distal end radius fractures is that it is a quicker and less technically demanding procedure compared to the more complex forms of fixation.⁸ Additionally, there is less soft tissue disruption as compared to open reduction and it can be used to supplement cast immobilization.

Disadvantages include - the complications of pin tract infection, less accurate fracture reduction and less stable fixation compared to plating techniques.⁹ Studies by "Kreder" et al, "Fuji" et al, "Kurup" et al, "Mardanikivi" et al claim that distal end radius fractures, even when displaced, have better functional outcome with closed reduction and K-wire pinning compared to closed reduction and cast.^{10,11,12,13} "Rosenthal" et al study found intrafocal pinning technique to be better compared to closed reduction and cast.¹⁴ External fixation for Colles' fracture can result in stiffness of wrist and fingers in few cases.¹⁵

In our study, we got statistically significant differences in range of motion, VAS scores and loss of radial length between the two groups, showing that the closed reduction K-wire fixation group has better results. This was also seen comparing Saito chart and Lindstrom's criteria results of both groups. The only significant complication with K-wire fixation is pin tract infection, which resolved after K-wire removal, seen in 13% of patients.

CONCLUSION

Closed reduction and percutaneous K-wire fixation is safer, better and easier technique to maintain reduction in displaced, distal end radius fractures, with minimal complications as compared to closed reduction and cast immobilization technique.

REFERENCES

1. Rockwood CA Jr., David Green P. Fractures in adults. 5th edition 2001; 2: 815-863.
2. Jupiter JB Fractures of the distal end of radius JBJS

1991; 3A: 461-467.

3. Cooney WP. Management of Colles' Fracture (editorial). Journal of Hand Surgery 1989;14B: 137-139.
4. Gary J Ciancney. Percutaneous Kirshner wire fixation of Colles' fracture JBJS 1984; 66A: 1008-1014.
5. Hardarsingh's et al. Closed reduction and percutaneous Kirschner wire fixation in Colles' fracture. Indian Journal of Orthopaedics 1986; 20: 2.
6. Campbell's Operative Orthopaedics 8th edition, 1991;2: 1046-1050.
7. Kreder H, Agel J, McKee M et al. A randomized controlled trial of distal radius fractures with metaphyseal displacement but without joint incongruity: Closed reduction and casting versus closed reduction spanning external fixation and optional percutaneous K-wires. Journal of Orthopaedic Trauma. 2006; 20: 115-121.
8. Stoffelen DVC, Broos PL. Closed reduction versus Kapandji pinning for extra-articular distal radius fractures. Journal of Hand Surgery (Br.). 1999; 24B: 89-91.
9. Naidu SH et al. Percutaneous pinning of distal radius fractures. Journal of Hand Surgery 1997; 22A: 252-257.
10. Arora R, Gabi M, Gschwantner M et al. A comparative study of clinical and radiologic outcomes of unstable Colles' type distal radius fractures. Non-operative treatment versus volar locking plating. Journal of Orthopaedic Trauma. 2009; 23:237-242.
11. Kreder HJ, Hanel DP, Agel J et al. Indirect reduction and percutaneous fixation versus open reduction and internal fixation of displaced intra-articular fractures of the distal radius. Journal of Bone and Joint Surgery (Br.) 2005; 87B: 829-836.
12. Fuji K, Henmi T, Kanematsu Y et al. Fractures of the distal end radius in elderly patients: A comparative study of anatomical and functional study. Journal of Orthopaedic Surgery. 2002; 10: 9-15.
13. Kurup HV, Mandalia VM, Shaju KA et al. Late collapse of distal radius fractures after K-wire removal. Journal of Orthopaedic Trauma. 2008; 9: 69-72.
14. Mardanikivi M, Asadi K, Hashemi Motlagh K, Shakiba M. Distal radius fracture, a comparison between closed reduction and long arm cast versus closed reduction and percutaneous pinning and short arm cast. Shiraz E – Medical Journal 2011;12: P 155-161.
15. Rosenthal AH, Chung KC. Intrafocal pinning of distal radius fractures: A simplified approach. Ann Plastic Surg 2002; 48: 593-599.
16. Jenkins NH. External fixation for Colles' fracture. Journal of Hand Surgery. 1989; 14B: 149-154.

Source of Support: Nil; **Conflict of Interest:** None

Submitted: 02-04-2018; **Accepted:** 01-05-2018; **Published:** 11-05-2018