Morphology of Caecum in Human Fetuses at Different Gestational Ages

Amrita Nidhi[1], Bharat Verma[2], D.N Sinha[3], A.K Singh[4]

ABSTRACT

Introduction: Limited information is available on developmental morphology of human fetal caecum. Embryologically, the caecal swelling appears as a small conical dilation of the caudal limb of primitive intestinal loop and it is the last part of the gut to return in the abdominal cavity. During rotation of gut it is located in the right upper quadrant below the right lobe of the liver. From here it descends into the right iliac fossa. The present study aims to locate the position and shape of caecum at different gestational ages of fetuses.

Material and methods: Thirty eight human fetuses (n=38) of 11-40 wks gestational ages were procured from Dr. Sushila Tiwari Memorial Hospital, Haldwani. Fetuses were dissected, illeocaecal region was displayed. The position and shape of caecum were recorded in situ.Out of 38 fetuses caecum was conical in 19 fetuses.Quadrangular in 10 fetuses and in 9 fetuses caecum is right saccular. Position of caecum was right subhepatic in18 fetuses, right lumber in 15 fetuses and right iliac fossa in 5 foetuses.

Results: The location of caecum in relation to abdominal regions presented higher incidence of subhepatic position in less than 30 weeks fetuses and right iliac fossa position in more than 30 weeks fetuses. With increasing gestational age position of caecum changes from right subhepatic position to right iliac fossa. Fetuses belonging to less gestational ages, caecum was conical in shape, however as the gestational age is increasing, caecum was noticed as quadrangular and right saccular in shape.

Conclusion: The observations are in favor of developmental process on the localization of caecum.

Keywords: Caecum, Vermiform appendix, Right saccular, Subhepatic position.

INTRODUCTION

The ileocaecal region,the discrete anatomical structure where the ileum enters the caecocolon,has been an area of interest for many anatomists and surgeons. Vermiform appendix, is the continuation of caecum, is considered as the organ with the highest topographic variation in the abdomen and is characterized by variability of its location and morphology. Therefore, it is important to know the normal developmental anatomy of caecum for better understanding of its various positions and other morphological features.

Caecum undergoes a very early and rapid developmental process. During the sixth to tenth week of embryonic life, the gut tube grows at a faster rate than the abdominal cavity; therefore, a portion of the midgut loop normally projects into the umbilical cord as primary intestinal loop. At about the tenth week the abdominal cavity grows at an accelerated rate and the mid-gut returns by normally definite sequence through the umbilical orifice to the abdominal cavity.[1,2] The proximal portion of the jejunum is the first part to return the abdominal cavity. As it recedes into the abdomen it rotates in a counter-clockwise direction thus it comes to lie on the left side. The later returning loops gradually settle more and more to the right. The caecal bud, which appears at about the sixth week as a small conical dilation of the caudal limb of the primary intestinal loop, is the last part of the gut to reenter the abdominal cavity. During this process the distal end of the caecal bud forms a narrow diverticulum, the appendix. On completion of this return the caecum first lies free near the umbilicus and ventral to the small intestine and mesenteric artery. However, the colon now begins to straighten and carries the caecum with it upward and to the right, the colon itself lying across the pedicle of the intestinal mass and mesenteric artery, the caecum lodging beneath the liver.[3,4]

By the eleventh week, the caecum and the first portion of the colon momentarily lies in the right upper quadrant directly below the right lobe of the liver. Subsequently, by apparent retraction of the liver and by linear growth of the colon, the caecum reaches its final position in the right iliac region. This descent of the caecum from sub hepatic to iliac region has been described in many textbooks of anatomy and embryology.[5]

Thus, it finally descends into the right iliac fossa, placing the ascending colon and hepatic flexure on the right side of the abdominal cavity. After this rotation is completed, the ascending mesocolon and the descending mesocolon both fuse to the posterior wall of the abdomen.

There are various studies done on different positions and dimensions of vermiform appendix all over the world. But limited information is available on the morphological aspects

[1]Senior Resident, Department of Anatomy, AIIMS Bhopal, [2]Senior Resident, Department of Anaesthiology, M.L.B Medical College Jhansi, [3]Professor, Department of Anatomy, Government Medical College, Haldwani, Uttarakhand, [4]Professor, Department of Anatomy, Government Medical College, Haldwani, Uttarakhand, India

Corresponding author: Dr.Amrita Nidhi, c/o- Dr. Jyoti Verma, Verma Nursing Home, 99- Khattriyana, Manik Chowk, Jhansi, U.P., Pin code-284002, India

How to cite this article: Amrita Nidhi, Bharat Verma, D.N Sinha, A.K Singh. Morphology of caecum in human fetuses at different gestational ages. International Journal of Contemporary Medical Research 2018;5(4):D1-D5.

DOI: 10.21276/ijcmr.2018.5.4.16

of anatomy of human fetal caecum. In the literature various parameters of human fetal caecum and appendix at different gestational ages were observed by Malas et al[6,7] on Turkish population and Mohammad et al[8] in Andhra Pradesh region of Indian Population.

Therefore, the present study was conducted with the aim to determine the location, growth and development of caecum during fetal period.

MATERIAL AND METHODS

Study was carried out in the Department of Anatomy, Government Medical College, Haldwani. The material for the study consisted of 38 aborted human fetuses and whose gestational ages were between 11 and 40 weeks. Fetuses were obtained from the labour room and operation theatre of Department of Obstetrics and Gyanecology, Dr Susheela Tiwari Memorial Hospital associated with Government Medical College Haldwani, over a period of two years, with relevant obstetric records available in the department. Human fetuses of age groups11- 40 weeks that exhibited neither external pathology nor anomaly were selected for present study. These fetuses were utilized after taking consent from their parents. After procurement of fetuses with due regard on ethical ground, fetuses were embalmed and preserved in 10% formalin. Gestational age was determined by the obstetric history and the ultrasonographic reports available in the department. However crown rump length and foot length were also used for those fetuses, in which proper history and ultrosonographic reports were not available. Determination of sex was done by observing the external genitalia.

Fetuses were divided into three groups, depending on their gestational age. First group containing 8 fetuses whose gestational age were between 11-20 weeks. Second group containing 9 fetuses, whose gestational age were between 21-30 weeks. Third group containing 21 fetuses, having gestational ages between 31-40 weeks.

Groups	Gestational Age (weeks)	No. of males	No. of females	Total
I	11-20	4	4	8
II	21-30	6	3	9
III	31-40	11	10	21

Fetuses were dissected by putting a midline incision from xiphisternum to symphisis pubis in anterior abdominal wall and a horizontal incision along the side of umbilicus. Ileocaecal region was displayed and the various morphological parameters and measurements were recorded in situ. The location of the vermiform appendix and caecum was established. (Photograph I and II). Shape of caecum was noted. (Photograph III, IVand V).

STATISTICAL ANALYSIS

Statistical data analysis was done by using SPSS software version 22, statistical package for windows and the significance was calculated by determining the p-value.

RESULTS

Taenia coli were absent on caecum and large intestine in

Photograph-I: Gross photograph of ileocaecal region, showing subhepatic position of caecum and appendix in a MALE FETUS of 40 WEEKS gestational age

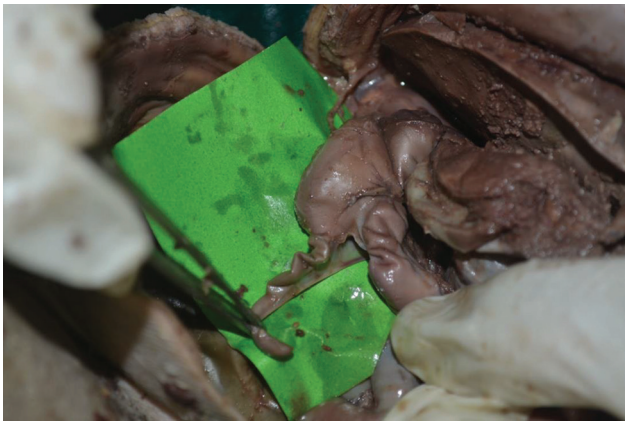

Photograph-II: Gross photograph of ileocaecal region, showing subhepatic position of caecum and extent of mesoappendix in a MALE FETUS of 38 WEEKS gestational age

Photograph-III: Gross photograph of ileocaecal region, showing conical shape of caecum, in a MALE FETUS of 23 WEEKS gestational age

fetuses of all age groups. Out of 38 fetuses, position of caecum was right subhepatic in18 fetuses, right lumber in 15 fetuses and in right iliac fossa in 5 foetuses. In our study of 38 fetuses, the incidence of subhepatic position is highest among all, followed by the right lumbar position. While the right iliac position that is found most commonly in adults, was found in least frequency in fetuses of our study (Table-1, Figure IA, Figure IB).

The shape of caecum was conical in 19 fetuses, quadrangular in 10 fetuses and in 9 fetuses caecum is right saccular. In our study of 38 fetuses, the incidence of conical is highest among all, followed by quadrangular shape of caecum. While the right saccular shape of caecum that is found most commonly in adults, was found in least frequency in fetuses of our study (Table-2, Figure IIA, Figure IIB).

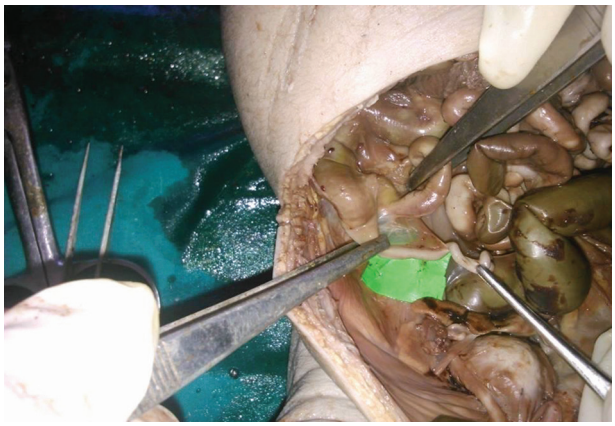

Photograph-IV: Gross photograph of ileocaecal region,showing right lumbar position and quadrangular shape of caecum in a FEMALE FETUS of 40 WEEKS gestational age

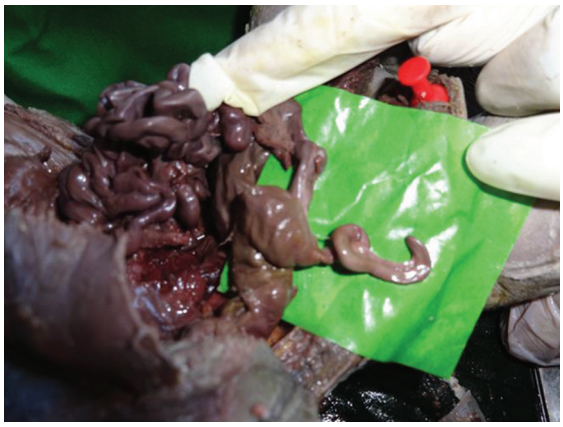

Photograph-V: Gross photograph of ileocaecal region, showing right saccular shape of caecum in a FEMALE FETUS of 40 WEEKS gestational age

DISCUSSION

Higher incidence of sub hepatic position in younger fetuses and right lumbar and right iliac fossa location in older fetuses in the present study suggests that there is migration of caecum and appendix from the initial sub hepatic to right

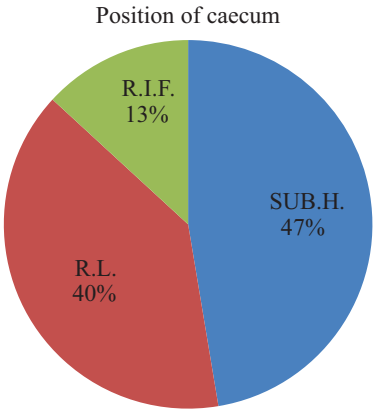

Figure-1A: Distribution of position of caecum among all the fetuses of present study

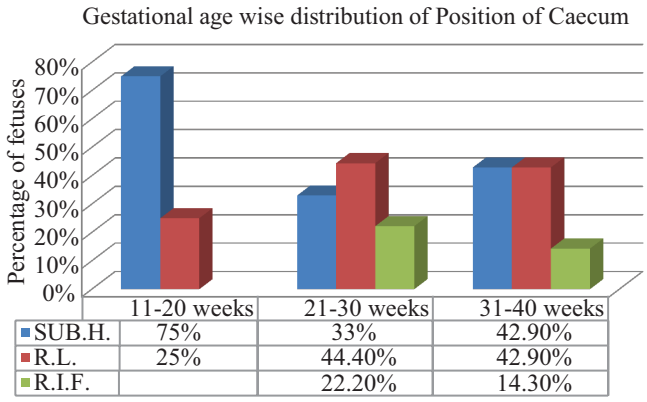

Figure-1B: Distribution of Position of caecum according to gestational age

		Position of caecum			Total	P - value*
		Subhepatic Position	Right Lumbar region	Right iliac fossa		
Fetus groups	11-20 weeks	6	2	0	8	
	21-30 weeks	3	4	2	9	0.415
	31-40 weeks	9	9	3	21	
Total		18	15	5	38	
*Chi-Square Test						

Table-1: Distribution of Position of caecum according to gestational age

		Shape of caecum			Total	p- value*
		Conical	Quadrangular	Right saccular		
Fetus groups	11-20weeks	7	1	0	8	
	21-30weeks	5	2	2	9	0.124
	31-40weeks	7	7	7	21	
Total		19	10	9	38	
*Chi-Square Test						

Table-2: Distribution of Shape of caecum according to gestational age

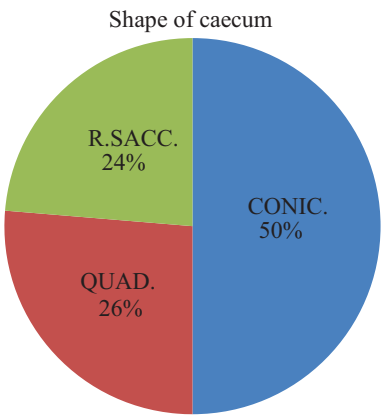

Figure-2A: Distribution of Shape of caecum among all the fetuses of present study

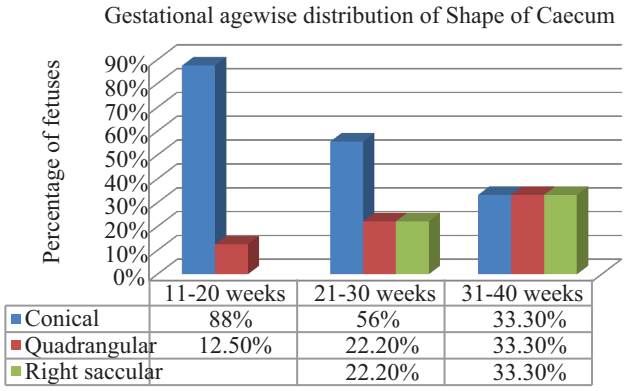

Figure-2B: Distribution of Shape of caecum according to gestational age

lumbar region in fetuses belonging to less gestational ages and to right iliac fossa in fetuses of higher gestational ages. So, the present study suggests that with increasing gestational age location of appendix changes from right subhepatic position to right iliac fossa.

The incidences of pelvic and right inguinal location of caecum and appendix that were reported in adults were not observed in the present study.

Developmental anatomy of caecum suggests that caecum is subject to positional variation during fetal period. Stage of development and rotation of gut influence the position of caecum and vermiform appendix development has a close relationship with caecal development during the fetal period. The ultimate position of appendix depends on growth of caecum and the extent of elongation of proximal part of large intestine. The results in the present study on position of caecum in fetal life are similar to the observations of Mohammad et al[8], which states that there is migration caecum and vermiform appendix from the initial sub hepatic to right lumbar region and right iliac fossa during fetal life.

Higher incidence of conical shape of caeum in younger fetuses and quadrangular and right saccular shape in older fetuses in the present study suggests that there is decreasing trend of frequency of conical caecum and increasing trend of frequency of quadrangular shape of caecum as we proceed from foetuses of 11-40 weeks.The right saccular shape of caecum was not found in fetuses of 11-20 weeks. There is increasing trend of frequency of right saccular shape of caecum as we proceed from foetuses of 21-40 weeks of gestational ages. The results in the present study on shape of caecum in fetal life are similar to the observations of Jeorge et al.[9] Maisel H[10], Treves F[11] Wengensteen et al[12] described caecum as remaining conical in shape throught the foetal life.,Parsons et al[13], Testus et al[14] reported the adult type shape of caecum during the later stages of fetal life.There are reasons in the literature to justify the different shapes of caecum that include the presence of content and the caecum internal pressure, the effect of gravity in relation to the two-footed position adopted by human beings.[15,16,17]

CONCLUSION

Subhepatic caecum and appendix, when associated with appendicitis, it can lead to misdiagnosis and severe complications during operations. Failure to identify these misplacements may lead to grave errors in procedure. Awareness of nature and characteristics of this location of appendix should be known to surgeons and radiologists. Caecum is mostly conical in shape in fetal life and right saccular shape of adult caecum arises from unequal development of its wall during postnatal life.

REFERENCES

1. Boyd HJD, Mossman HW. In Boyd HJD, Mossman HW et al. editors. Human Embryology. 3rd ed. University of California; 1976.p.355-59.
2. Sadler TW. Digestive system. In: Christilda F, Ashok S, Shakuntala RP, PrithaSB, Gangane SD, Shashi W et al. editors. Langman's medical embryology. 11th ed. New Delhi: Wolters Kluwer; 2009.p. 223-29.
3. Robinson, Arthur, 1923: Cunningham's Text-book of Anatomy. 5th Ed. Edinburgh: William Wood and Co. 1206.
4. Standring S, ed. Gray's Anatomy.40th Ed., New York, Churchill Livingstone. 2010; p.1144.
5. Moore K.L., Persaud T.V.N. The digestive system. In: Moore KL, Persaud TVN. editors. The Developing Human clinically oriented embryology. 8th ed. New Delhi: Elsevier; 2008.p.218.
6. Malas, M.A., Gokcimen, A., and Sulak O., Growing caecum and Vermiform Appendix during fetal period. Fetal diagnosis and therapy 2001;16:173-177.
7. Malas, M.A., Sulak O., Gokcimen, A. et al. Development of the vermiform Appendix during the fetal period Surgery radiologic anatomy. 2004, vol.26, no3 p., 202-207.
8. Mohammad, R., Velichety, S., Thyagaraju, K., Azharuddin, M.D., and Jyothirmayi, K. Morphological Features and Morphometric Parameters of Human Fetal vermiform Appendix at Different Gestational Ages. Int J Anat Res. 2013;1:18-25.
9. Jorge, A, Ferreira, JR. and Pacheco, YG, Braz. J: Development of vermiform appendix in children from different age groups; Morphol. Sci.2009;26: 68-76.
10. Maisel, H. The position of the human vermiform appendix in fetal and adult age groups. Anat. Record., 1960;136:385-9.

11. Treves F. Lectures on the anatomy of intestinal canal and peritoneum in man. Br Med J. 1885; 1: 527–530.
12. Wangensteen. O.H. and Dennis. C. Experimental proof of the obstructive origin of appendicitis in man. Ann. surg. 1939;110:629.
13. Parsons, JM., Miscall, BG. and Mcsherry, CK. Appendicitis in the new born infant. Surgery. 1970;67:841-846.
14. Testut, L. and Jacob, O. Cavidad abominal y Su Contenido. In TESTUT, L., JACOB, O. (Ed.). Tratado de anatomia topográfica: com aplicaciones médicoquirúrgicas. Spain: Salvat, 1952. p. 257-269. (tomo 2).
15. Smith, GM. A statistical review of the variations in the anatomic positions of the cecum and the processus vemiformis int the infant. Anatomy Record. 1911;5: 549-556.
16. Wakeley CPG The position of the vermiform appendix as ascertained by an analysis of 10,000 cases. J Anat 1933;67: 277-283.
17. Garis, Cf, Topography and development of the cecum appendix annals of Surgery 1941; 113:540-548.

Source of Support: Nil; **Conflict of Interest:** None

Submitted: 10-03-2018; **Accepted:** 11-04-2018; **Published:** 05-05-2018