

# Comparison of Two Different Irrigating Solutions I.E. 3% Hydrogen Peroxide and 0.12 % Chlorhexidine in Pericoronitis of Partially Erupted Mandibular Third Molars, without Antibiotics

Parveen Akhter Lone<sup>1</sup>, Roshika Jamwal<sup>2</sup>, Ambica Suden<sup>3</sup>, Bashir Ahmed Lone<sup>4</sup>

## ABSTRACT

**Introduction:** Pericoronitis is the inflammation of the soft tissue associated with the crown of a partially erupted tooth. The treatment of acute phase includes debridement of plaque, food debris and irrigation of the pericoronal space with sterile saline, chlorhexidine or hydrogen peroxide. Surgical intervention is made once the acute phase has subsided. The aim of this study was to compare the effectiveness of 3% Hydrogen Peroxide and 0.12 % Chlorhexidine in acute phase of pericoronitis associated with partially erupted mandibular third molars without the use of antibiotics.

**Material and methods:** Patients were divided into two groups, Group A and group B depending upon the irrigating solution used, to provide relief from pain and discomfort in the acute phase. Group A was irrigated using 3% H<sub>2</sub>O<sub>2</sub> diluted in the ratio of 1:1 with normal saline followed by copious irrigation with normal saline and in Group B 0.12 % chlorhexidine was used as the irrigant of choice. The clinical parameters measured to examine the efficacy of the irrigating solutions were pain, maximum mouth opening, associated bleeding on probing, pocket depth and any associated space infection. The subjects included for the study were healthy, willing, non smoking individuals who were above the age of 18 years, and reported with pain associated with partially erupted mandibular third molar.

**Results:** Early decrease in pain, improved mouth opening, improved gingival index, decreased halitosis, decreased pocket depths due to regressed swelling of pericoronal flap were reported in patients of group A, while those in group B required more time and adjunct measures for improvement.

**Conclusion:** As per the observation of this study, the patients treated with 3% H<sub>2</sub>O<sub>2</sub> showed early resolution of clinical symptoms and so it is recommended that 3% H<sub>2</sub>O<sub>2</sub> should be used for early recovery in acute pericoronitis associated with partially erupted mandibular Third molars without antibiotics.

**Keywords:** Impacted, hydrogen peroxide, chlorhexidine, pericoronitis, periodontal pocket

## INTRODUCTION

Pericoronitis refers to inflammation of the soft tissue in relation to the crown of an incompletely erupted tooth, including gingival and dental follicle.<sup>1,2</sup> It is most commonly seen in relation to the third molar, particularly of the mandibular arch but it can occur around the base of any tooth that has not completely erupted. Amongst acute oral health problems of young adults, pericoronitis is found to be ranked as first or second.<sup>3,4</sup> Maintenance of hygiene of the periodontal flap is very difficult by routine methods of oral hygiene; hence irrigation plays an important role in flushing of the area. The decision to extract or retain the tooth is made on the eruption status of the tooth.<sup>5</sup> The treatment planning for surgical intervention is made

only after the acute phase has subsided.

The initial therapy prescribed for the management of acute pericoronitis in the absence of any systemic condition is irrigation.<sup>5</sup> The Royal College of Surgeons of England has given National Clinical guidelines for management of pericoronitis where in they state that the irrigation of the pericoronal space with warm water should be done to gently flush the area so that food debris and exudates can be removed.<sup>1</sup> The irrigating solutions should be sterile, which may include Normal Saline, Chlorhexidine, hydrogen peroxide<sup>6</sup> or local anaesthetic solutions.<sup>7</sup>

The use of caustic agents like chromic acid, phenol liquefactum, trichloro acetic acid or Howe's ammoniacal solution has been advocated in the past, to control pain by placing a small amount on a cotton pellet under the operculum. However this practice of using toxic chemicals is no longer prevalent.<sup>8</sup>

Chlorhexidine gluconate is a broad spectrum antimicrobial drug. It is safe and has an inherent advantage over antibiotics by not producing resistant microorganisms.<sup>9</sup> It has been reported that 0.12% chlorhexidine can be used in any patients presenting with redness, swollen gingiva including Bleeding on Probing, however chlorhexidine has a high potential for extrinsic staining of teeth.<sup>9</sup>

Pocket irrigation with 3% H<sub>2</sub>O<sub>2</sub> has proved to be effective in killing anaerobic pathogens and treat periodontal disease. Subgingival irrigation with H<sub>2</sub>O<sub>2</sub>, followed by Normal saline, has produced significant reduction in gingival bleeding index and plays a potential role in inflammation control.<sup>6</sup>

Considering the role of anaerobic bacteria in periodontal diseases and recognizing the clinical application of the broad spectrum antimicrobial chlorhexidine gluconate<sup>9</sup> and destructive effects of free oxygen radicals of H<sub>2</sub>O<sub>2</sub>.<sup>6</sup> We decided to investigate and conduct this study to compare and establish the role of the 3% hydrogen peroxide and 0.12 % chlorhexidine in irrigation of per coronal space of partially third erupted molars.

## MATERIAL AND METHODS

This is a randomised controlled study and was undertaken in

<sup>1</sup>Professor and Head, <sup>2</sup>House Surgeon, <sup>3</sup>House Surgeon, Department of OMFS, IGGDC, <sup>4</sup>Curator, Department of Geology, University of Jammu, Jammu

**Corresponding author:** Dr Parveen Akhter Lone, HOD, Department of Oral and Maxillofacial Surgery, Indira Gandhi Government Dental College, Jammu, JandK 180005.

**How to cite this article:** Parveen Akhter Lone, Roshika Jamwal, Ambica Suden, Bashir Ahmed Lone. Comparison of two different irrigating solutions I.E. 3% hydrogen peroxide and 0.12 % chlorhexidine in pericoronitis of partially erupted mandibular third molars, without antibiotics. International Journal of Contemporary Medical Research 2016;3(11):3353-3356.

the department of Oral and maxillofacial surgery. The study compares the efficacy of two different irrigating solutions in subsiding the acute phase of pericoronitis associated with partially erupted third molars without antibiotics in its acute phase. The solutions used were 3% H<sub>2</sub>O<sub>2</sub> followed by NS and 0.12 % chlorhexidine.

The study group consisted of 100 patients with pain, trismus, decreased mouth opening, swelling associated with partially erupted mandibular third molars. After taking informed consent, clinical and radiographic examination of the patient was done and a treatment plan was formulated. Patients were divided into two groups depending upon the indicated treatment plan.

In group A, 50 patients were irrigated with 3% H<sub>2</sub>O<sub>2</sub> diluted in the ratio of 1:1 with Normal saline followed by copious washing with NS. In group B, 50 patients were irrigated with 0.12% chlorhexidine solution.

The various clinical parameters used to assess improvement with irrigation were Pain using the Visual Analog Scale<sup>10</sup>, Maximum Mouth Opening using the three finger opening method<sup>11</sup>, Bleeding on probing using the Loe and Sillness gingival index 1963<sup>12</sup>, and Pocket Depth using the William’s probe<sup>6</sup>, were checked and recorded. Various local symptoms like bad breath and altered taste were also asked for. On subsequent visits on the 3<sup>rd</sup>, 5<sup>th</sup> and 7<sup>th</sup> days, irrigation was done respectively in both groups and the patients were examined for the above mentioned parameters and the findings were recorded.

**Inclusion Criteria**

1. Age: above 18 years of age
2. Healthy, Non Smoking Individuals
3. Partially erupted mandibular molars not associated with any Inflammation or Pus.
4. Patients who are willing for follow up.

**Exclusion Criteria**

1. Medically compromised patients
2. Occlusal trauma from opposing maxillary Molars.
3. Patients on Antibiotics, Oral contraceptives
4. Patients allergic to Chlorhexidine or Hydrogen peroxide.

**STATISTICAL ANALYSIS**

SPSS version 21 was used for the statistical analysis. Descriptive statistics like mean and percentages were used for the data analysis.

**RESULTS**

Of the 100 patients treated 67 were females while 33 were males as depicted in Figure 1. The range of age of patients taken under evaluation was 18- 40 years and the mean age was 29 years. Number of patients treated with hydrogen peroxide followed by saline and chlorhexidine were 50 each.

Out of the 50 patients who were relieved of pains by H<sub>2</sub>O<sub>2</sub> followed by saline (GROUP A) were 5 on the first visit i.e. day 1, 33 on the second visit i.e. day 3 and 12 on the third visit i.e. day 5. None of patients reported back for the fourth visit i.e. day 7.

In The patients who were irrigated by chlorhexidine (GROUP B) there was no relief of pain in any patient on the first visit i.e. day 1, 5 patients reported on the second visit i.e. day 3 with relief in pain, 17 on the third visit i.e. day 5 and 12 on the fourth visit i.e. day 7. The remaining 16 patients kept coming for

follow up on subsequent days. The patients treated with H<sub>2</sub>O<sub>2</sub> followed by saline showed a drastic decrease in pain after the first visit and number kept decreasing on the subsequent visits, while those treated with chlorhexidine showed a decrease in pain gradually as exhibited in Figure 2. The number of patients relieved kept increasing with subsequent visits.

The bleeding on probing 8 patients showed instant decrease with H<sub>2</sub>O<sub>2</sub> followed by saline, on the second visit i.e. 7, and only 1 on the third visit, while those treated with chlorhexidine followed a gradual pattern of decrease in bleeding on probing, i.e. out of 10, 3 exhibited improvement on second visit, 5 on third visit and 2 on fourth visit, on the Loe and Sillness Gingival Index, as represented in Figure 3.

Pocket depth showed quick improvement with H<sub>2</sub>O<sub>2</sub> followed by saline, due to early regression of inflammation of pericoronal flap as the debris was dislodged by the effervescent action of H<sub>2</sub>O<sub>2</sub>. In patients where the pocket depth was 4 earlier, on day 1, was seen as low as 2 on days 3 and 5, and further reduced to 1.5 on day 7 on the Williams probe. Those treated with Chlorhexidine also showed equally results but the duration was longer. A score of 4 on day 1 gradually decreased to 3 on day 3, 2.5 on day 5 and 2 on day 7, as is seen in Figure 4.

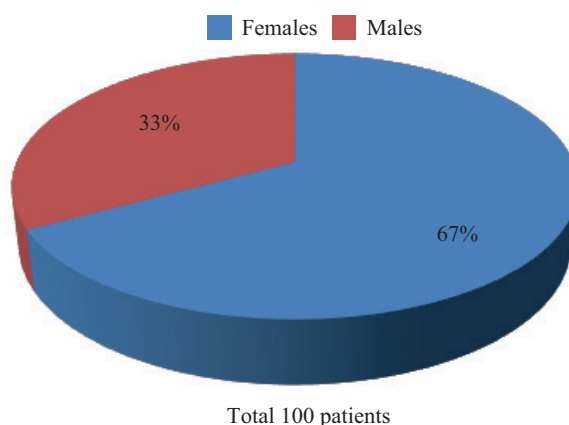


Figure-1: showing gender distribution

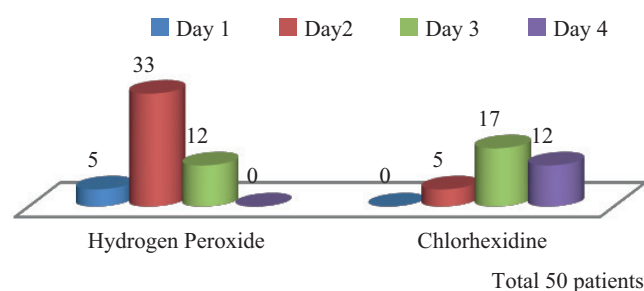


Figure-2: displaying improvement in pain after h2o2 irrigation

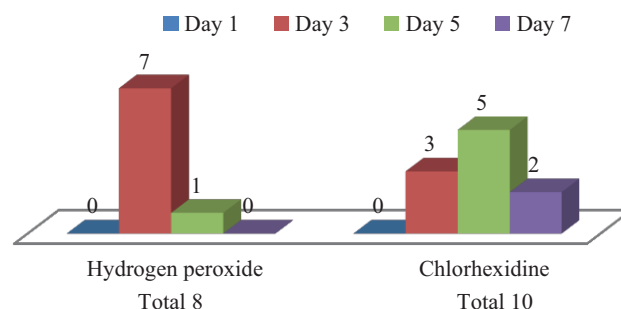
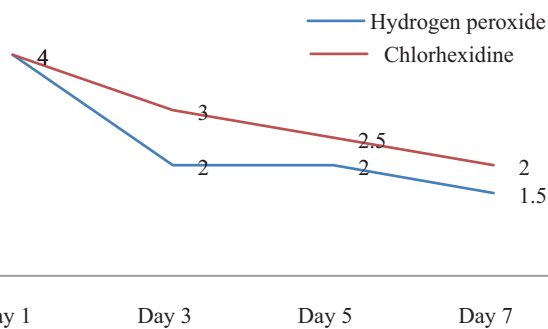


Figure-3: showing results of bleeding on probing



**Figure-4:** marked difference in pocket depth

The mouth opening showed improvement in patients where it was restricted. In patients treated with H<sub>2</sub>O<sub>2</sub> followed by saline, it increased gradually from two fingers opening in 10 patients on day 1 to three fingers opening in 7 patients on day 3 and 3 on day 5. While those treated with chlorhexidine did not show much improvement. Two fingers opening in 7 patients on day 1 remained two in 5 patients on day 3 and improved to two and a half in the remaining 2, on day 5. The patients revealed similar improvement in local symptoms like bad breath and altered taste with H<sub>2</sub>O<sub>2</sub> followed by saline and chlorhexidine.

## DISCUSSION

Acute Pericoronitis in partially erupted third molars is sudden in onset, may be short lived but has significant symptoms. It is usually seen in patients having moderate to poor oral hygiene.<sup>5</sup> The most common site is an impacted or a partially erupted mandibular third molar. It is characterised by red swollen lesion, which is tender and shows radiating pain to the ear, throat, floor of the mouth, TMJ and posterior submandibular region. Swelling of the cheek in angle region of the mandible may be seen along with Trismus, pain, bleeding on probing, increased pocket depth.<sup>1,8</sup> In the present study same symptoms were reported by majority of the patients

It is proven that pericoronitis predominantly colonizes anaerobic microbial flora.<sup>13,14</sup> The predominant bacterial species in pericoronitis of erupting mandibular third molars are Streptococcus, Antinomies and Propionibacterium species. There is also evidence of presence of  $\beta$ - lactamase producing bacteria like Prevotella, Bacteroides, Fusobacterium, Capnocytophaga and Staphylococcus species.<sup>15,16</sup>

Pericoronitis is seen mostly in females as shown in Figure 1 in accordance with the other studies in literature. Bataineh et al<sup>17</sup> and Yamik and Bozkaya<sup>18</sup> reported that pericoronitis was much more frequently seen in females than males.

Since extraction is contraindicated in acute infections hence irrigation becomes the treatment of choice in the initial phase.

Hydrogen peroxide has been used in dentistry in combination with salts or alone for over 70 years. For most subjects, beneficial effects have been seen with H<sub>2</sub>O<sub>2</sub> levels above 1%<sup>19</sup> Due to effervescent action and release of hydroxyl free radicals H<sub>2</sub>O<sub>2</sub>, has shown significant results in decreasing pain, improving bleeding on probing as seen in other studies.<sup>6</sup> Hydrogen peroxide has been shown to possess a wide spectrum of antimicrobial activity in that it is active against bacteria, yeasts, fungi, viruses and spores.<sup>20-22</sup> 3% H<sub>2</sub>O<sub>2</sub> is used in the treatment of periodontal disease and it has been shown effective in killing anaerobic pathogens. It has also shown better efficacy in probing depth

reduction as against some studies.<sup>6</sup> In the present study also shows improvement in pain, mouth opening, swelling, bleeding in probing, pocket depth as shown in pie Figure 2-4

Chlorhexidine gluconate (chlorhexidine) is a broad-spectrum antimicrobial drug. It acts as an antiseptic, and an effective bactericidal agent and has an inherent advantage over antibiotics by not producing resistant microorganisms. As a result chlorhexidine can be used safely, repeatedly and over long periods of time.<sup>9</sup> It flushes out the debris and relieves pain, improves bad breath and altered taste as seen in other studies<sup>9</sup> in accordance with present study

Considering the role of anaerobic bacteria in periodontal diseases and the ecosystem in periodontal pockets that allows microbial growth, and recognizing the clinical application of the broad spectrum antimicrobial chlorhexidine gluconate<sup>9</sup> and destructive effects of free oxygen radicals of H<sub>2</sub>O<sub>2</sub>, the present study was conducted to investigate the effect of irrigation with 3 % H<sub>2</sub>O<sub>2</sub> and 0.12 % chlorhexidine in acute pericoronitis.

## CONCLUSION

As per the observations of this study all patients treated using 3% H<sub>2</sub>O<sub>2</sub> diluted in the ratio of 1:1 with normal saline followed by copious irrigation with normal saline, exhibited early resolution of symptoms in comparison to 0.12 % Chlorhexidine, in acute phase of pericoronitis associated with partially erupted mandibular third molars without the use of antibiotics. The present study therefore indicate That 3% diluted hydrogen peroxide plays a potential role in pericoronitis associated with partially erupted mandibular third molars, to alleviate patient's symptoms.

## ACKNOWLEDGMENT

The Authors would like to thank and acknowledge Ayera Bashir and Zain ul Arifeen for helping in tabulating the results and also the patients for their cooperation.

## Disclosure

The Authors declare that they have no conflicts of interest and/ Or any financial interests in preparing the manuscript

## REFERENCES

1. Carranza. Clinical periodontology. 10<sup>th</sup> ed. Newman MG, TakeiHH, Klokkevold PR, Carranza FA, editor. St. Louis, Missouri: Saunders Elsevier; 2006.
2. Fragiskos D. Oral Surgery. Berlin : Springer; 2007.
3. Guralnick W, third molar surgery. Br dent J. 1984;156:389-94.
4. Ludwick WE, Pogas JA, Gendron EG, Weldon AL. Dental emergencies occurring among Navy- Marine personnel serving in Vietnam. Mil Med. 1974;139:121-23.
5. Dhonge RP, ZadeRM, Gopinath V, Amirisetty R. An insight into pericoronitis. Int JDent Med Res. 2015;1:172-175.
6. Sahebjam Atabaki, M. Moradi Haghgoo, J, Khoshhal, M. Arabi, R. Khodadoostan, A. Gholami, L. Clinical effect of periodontal pocket irrigation with H<sub>2</sub>O<sub>2</sub>, DHJ. 2011;3:53-59.
7. National Clinical Guidelines. The Royal College of Surgeons of England 1997.
8. Moloney J, Stassen L. pericoronitis: treatment and a clinical dilemma. J Irish Dent Assoc. 2009;55:190-192.
9. Gary J. kaplowitz, Marilyn cortell. Chlorhexidine : a multi-functional anti microbial drug.

10. VAS, Pain Management: Theory and Practice, edited by R K Portenory and R M Tanners copyright 1996 by oxford university press.
11. Zawani KH, et al. An index for the measurement Of Normal maximum mouth opening. *J Can Dent Assoc.* 2003;69:737-41.
12. Loe, H. The Gingival Index, the Plaque Index and the Retention Index Systems. *Journal of periodontology.* 1967;38:610-6.
13. Hurlen B, Oslen I. A Scanning electron microscope study on the microflora of chronic pericoronitis of lower third molars. *Oral Surg Oral Med Oral Pathol.* 1984;58:522-32.
14. Mombelli A, buser D, lang NP, Berthold H. suspected periodntopathogens in erupting third molar sites in periodontally healthy individuals. *J Clin periodontal.* 1990;17:48-54.
15. Gutierrez Perez JL. Third Molar infections. *Med Oral Patol Oral Cir Bucal.* 2004;9:120-25.
16. Sixou JL, Magaud C, Jolivet-Gougeon A, Cormier M, Bonnaure –Mallet M. Evaluation of the mandibular third molar pericoronitis flora and its susceptibility to different antibiotics prescribed in France. *J Clin Microbiol.* 2003;41:5794-97.
17. Bataineh AB, Albashaireh ZS, Hazza'a AM: The surgical removal of mandibular third molars: study in decision making. *Quintessence Int.* 2002;33:613-617.
18. Yamalik K, Bozkaya S: The predictivity of mandibular third molar position as a risk indicator for pericoronitis. *Clin Oral Investig.* 2008;12:9-14.
19. Marshall MV, Cancro LP, Fischman SL. Hydrogen peroxide: a review of its use in dentistry. *J Periodontol.* 1995;66:786–9.
20. Brudzynski K. Effect of hydrogen peroxide on antibacterial activities of Canadian honeys. *Can J Microbiol.* 2006; 52:1228–37.
21. Glockmann E, Wiesner J, Oehring H, Glockmann I. Antibacterial efficiency and toxicity of hydrogen peroxide and other antiseptics. *Dutsch Stomatol.* 1990;40:462–3.
22. Tschernjawsckaja MA, Belowa AS. Antibacterial mechanism of action of hydrogen peroxide preparations. *Z Gesamte Hyg.* 1990;36:86–8.

**Source of Support:** Nil; **Conflict of Interest:** None

**Submitted:** 24-10-2016; **Published online:** 07-12-2016