

Transverse Cerebellar Diameter – An Ultrasonographic Parameter For Estimation of Fetal Gestational Age

R Nagesh¹, Seetha Pramila VV², Anil Kumar Shukla³

ABSTRACT

Introduction: Several parameters are in use for the assessment of fetal gestational age by ultrasonography. Fetal transverse cerebellar diameter can be used as another parameter for the gestational age estimation. Cerebellum being part of hind brain is situated in posterior cranial fossa and is less vulnerable for deformation. Aim of the study was to measure and correlate transverse cerebellar diameter with fetal gestational age and to evaluate cerebellar growth pattern by ultrasonographic cerebellar grading.

Material and Methods: This is a prospective cross sectional study consisting of 100 normal singleton gestations in the period of 15 to 40 weeks. Average gestational age of all the fetuses was calculated by using bi parietal diameter, head circumference, abdominal circumference and femoral length. Fetal transverse cerebellar diameter was measured. cerebellar grading was done by ultrasonography.

Results: We observed a linear correlation between transverse cerebellar diameter and gestational age (correlation coefficient $r=0.992$, $p<0.001$). The study showed 18%, 49% and 33% of the cerebellum were of grade I, grade II and grade III respectively. Ultrasonography showed progressive changes in cerebellum from grade I to grade III with advancing gestational age.

Conclusions: Transverse cerebellar diameter can be used as a reliable parameter in the estimation of fetal gestational age. Its grading can be used in evaluation of development of fetus.

Keywords: Transverse Cerebellar Diameter, Gestational Age, Cerebellar Grading, Ultrasonography.

growth changes can be evaluated on USG. The maximum diameter of this organ being transverse can be measured by USG accurately at all the stages of development. It is less vulnerable for deformation from extrinsic compression as it is located in thick bony fossa. It is not influenced by alterations in the fetal growth such as macrosomia and intra uterine growth retardation.² Hence it can be used as a reliable parameter for estimation of fetal gestational age compared to other routine parameters. It is observed that fetal TCD in normal gestations correlates well with fetal growth indices. USG being non invasive, cost effective, easily available, can be used for imaging fetal cerebellum. TCD can be a better marker for gestational age estimation.

Our aim of this study was to correlate the TCD with fetal gestational age and to assess the cerebellar growth pattern by ultrasonographic grading.

MATERIAL AND METHODS

This prospective cross sectional study consisting of 100 normal singleton pregnant women was carried out in our Hospital during the period from March to December 2015. The pregnant women who were referred to our department for routine antenatal ultrasound examinations were selected for the study. Among them normal singleton gestations in the period of 15 to 40 weeks of gestation were included for the study. The study was approved by the ethical committee of our institution and consent was taken from all the patients before USG examination. All the gestations were evaluated by USG to confirm gestational age and compared with their Last Menstruation Period (LMP). Patients with incorrect LMP and USG dating scan difference of more than a week in first trimester were excluded from the study. Women with systemic disorders or obstetric disorders, anomalous fetuses and multiple gestations were also excluded from the study.

All the selected pregnant women were scanned transabdominally in supine posture with 3.5 MHz convex probe using Siemen's sonoline G50 ultrasound system. All the TCD were recorded in millimeters. The fetal cerebellum was identified in the transverse view of posterior cranial fossa by using thalami, cavum septum pellucidum and 3rd ventricle as landmarks, followed by rotation of the transducer below the tha-

INTRODUCTION

Cerebellum is the part of the hind brain situated in the posterior cranial fossa dorsal to the pons and medulla separated by the fourth ventricle. It is well protected in the posterior cranial fossa by the dense petrous ridges and the thick occipital bone. It is separated from the cerebral hemispheres by a fold of duramatter, the tentorium cerebelli. The cerebellum consists of a mid line part called vermis and two lateral hemispheres. It develops around 5th week of embryonic life from the dorso lateral part of the alar lamina of the metencephalon.¹

Assessment of fetal gestational age is an essential part of obstetric ultrasonography (USG). It helps in the evaluation of fetal growth and management. For the estimation of fetal gestational age the commonly used parameters are- Mean Sac Diameter (MSD), Crown Rump Length (CRL), Bi Parietal Diameter (BPD), Head Circumference (HC), Abdominal Circumference (AC) and Femoral Length (FL). Transverse cerebellar diameter (TCD) can be used as another parameter for the estimation of fetal gestational age.

Fetal cerebellum starts developing at 5th week of antenatal life, continues to develop through out gestational period. The

¹Associate Professor, ²Professor, Rajarajeswari Medical College and Hospital, Bangalore, ³Professor, ACS Medical College, Chennai, India

Corresponding author: Dr R Nagesh, No. 533, 8th Main, Vijaynagar, Bangalore-560040, Karnataka, India

How to cite this article: R Nagesh, Seetha Pramila VV, Anil Kumar Shukla. Transverse cerebellar diameter – an ultrasonographic parameter for estimation of fetal gestational age. International Journal of Contemporary Medical Research 2016;3(4):1029-1031.

lamic plane to view the butterfly like structure the cerebellum.³ The TCD was obtained by placing the calipers at the outer to outer margin measuring the widest diameter of the cerebellum [Figure-1].² A single best and widest transverse diameter of the cerebellum was recorded.

All the cerebellum were examined by USG to assess the growth pattern, they were grouped into three categories as per the following USG criteria.⁴

Grade-I: The cerebellar hemispheres are round, appear as two cystic globules on either side of the midline, lack echogenicity and the central vermis is not developed, resembling a pair of ‘eye glasses’.

Grade-II: The two cerebellar hemispheres appear oval and hypoechoic with echogenic outer margins and the vermis is seen as a central rectangular tissue connecting the two hemispheres resembling ‘dumb bell’ shape.

Grade-III: The cerebellum changes to a more triangular, homogeneously echogenic and solid structure appearing like ‘fan’ shaped structure occupying posterior cranial fossa.

RESULTS

Among the 100 pregnant women who were in the age group of 18 to 35 yrs, 23% were less than 20 yrs, 69% in the age group of 21 to 30 yrs and 8% above 30 yrs. 48 % were primiparous and 52 % were multiparous. Out of these gestations 72% fetuses were in cephalic, 12% in breech, and 16% in unstable presentations.

TCD measurements

Among the total 100 fetuses from 15 to 40 weeks of gestation age, TCD measurements frequency ranged from 1 to 10 for each gestational age. The minimum TCD was 14 mm at 15 weeks of Gestational age and maximum TCD was 56 mm at 39 weeks. Mean median and standard deviation were calculated for all the gestational age and TCD. The mean gestational age was 27.64 +/- 7.3 weeks. The mean TCD was 33.09 +/- 12.5 mm. We observed a linear correlation between TCD and gestational age from 15 to 40 weeks. Correlation coefficient $r = 0.992$ and $p < 0.001$ which were statistically significant indicating high degree of correlation between TCD and gestational age. The TCD in mm was almost corresponded to gestational age in weeks from 15 to 20 weeks, and later on TCD in mm exceeded gestational age in weeks. A scatter diagram was plotted using all the TCD and gestational age data as shown in [Figure-2].

Cerebellar Grading

Among the 100 cases in this study USG cerebellar grading showed, 18 %, 49 % and 33% of grade I, II and III respectively. There was a progressive change from Grade I to Grade III with advancing gestational age. Results have been shown in [Table-2].

Of the 18 cerebellum of grade I, the median gestational age was 18 weeks and the median TCD was 18 mm. The minimum gestational age was 15 weeks, maximum gestational age was 26 weeks and the minimum TCD was 14 mm, maximum TCD was 27 mm in this group.

Of the 49 cerebellum of grade II, the median gestational age was 24 weeks and the median TCD was 27 mm. The minimum gestational age was 16 weeks, maximum gestational

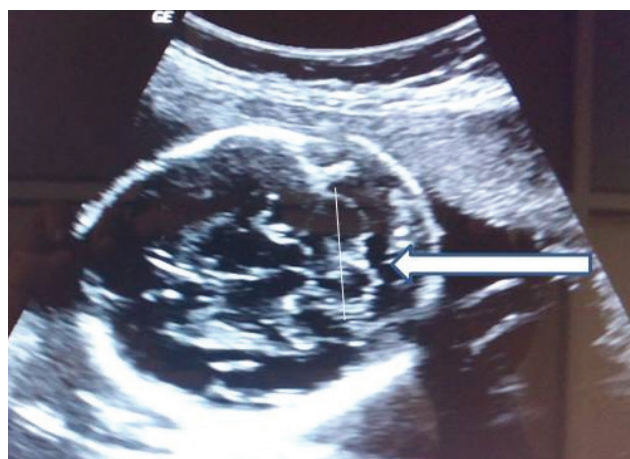

Figure-1: Ultrasonographic image showing TCD measurement (Arrow)

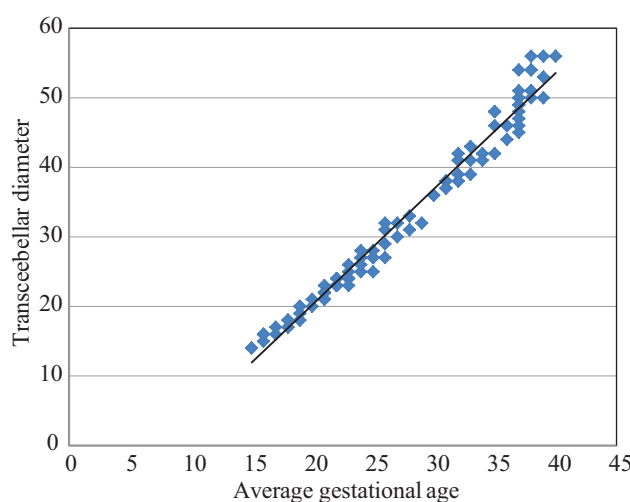


Figure-2: Scatter plot- transcerebellar diameter in mm versus gestational age in weeks.

		TCD	GA
TCD	Pearson Correlation	1	.992**
	Sig. (2-tailed)		.000
	N	100	100
GA	Pearson Correlation	.992**	1
	Sig. (2-tailed)	.000	
	N	100	100

**Correlation is significant at the 0.01 level (2-tailed). Pearson's correlation coefficient, $r = 0.992$, $p < 0.001$.

Table-1: Statistical analysis

age was 34 weeks and the minimum TCD was 16 mm, maximum TCD was 43 mm.

Of the 33 cerebellum of grade III, the median gestational age was 37 weeks and the median TCD was 48 mm. The minimum gestational age was 31 weeks, maximum gestational age was 40 weeks and the minimum TCD was 37 mm, maximum TCD was 56 mm.

DISCUSSION

Accurate gestational age estimation is the corner stone in any obstetric management. Fetal development monitoring is now possible with the introduction of USG. Several biometric parameters are in use for the assessment of fetal gestational

Cerebellum grades	Number of patients	Percentage	Median gestational age in weeks	Median TCD in mms
Grade I	18	18%	18	18
Grade II	49	49%	24	27
Grade III	33	33%	36	48

Table-2: Results of ultrasonographic cerebellar grading.

age and growth during the antenatal period. USG biometric parameters are helpful in determination of gestational age where correct LMP is not known. Higher peri natal mortality has been reported in patients whose expected date of delivery is not known. Wrong assessment of gestational age can result in prematurity or post maturity. All these will lead to increased peri natal and infant morbidity and mortality.

It is said that USG fetal biometry is reliable in first two trimesters and its reliability diminishes as the gestation advances.⁵ No single parameter is reliable in third trimester as shown by many studies. Usually average gestational age is calculated using one or more parameters is the currently practiced method in routine obstetric USG. In patients with incorrect and unknown LMP dates, USG helps in the assessment of correct fetal gestational age and fetal disorders. Hence USG plays a major role in modern obstetric practice. In addition to the currently used biometric parameters, TCD can be used as a established and reliable USG parameter. TCD measurement is very simple and accurate. It is superior to other biometric parameters as it is not affected in many disorders like abnormal skull shapes, fetal growth retardation, and multiple pregnancies and large for date fetuses.¹ Hence it can be used as a reliable parameter in all routine antenatal USG.

In this study USG visualization of cerebellum was around 13 to 14 weeks of gestation. We observed the progressive USG changes of cerebellum from grade I to grade III as described in earlier literatures. Cerebellum can be easily imaged in the transverse sections of posterior cranial fossa without any difficulty and TCD measurement can be taken. We noticed in our study the TCD in millimeters is almost equal to gestational age in weeks up to 20 weeks, thereafter TCD in millimeters exceeds gestational age in weeks and reached up to 56 mm. In our study we observed a linear relationship between TCD and gestational age indicating the reliability in the estimation of gestational age and monitoring fetal growth. Our findings are consistent with observations made in previous studies. The progressive USG changes of the cerebellar development is attributed to purkinje cell differentiation and decrease in cerebellar water content with advancing gestational age.⁶

CONCLUSION

We observed a linear relationship between TCD and fetal gestational age between 15 to 40 weeks of normal gestations ($r=0.992$, $p<0.001$). The TCD increased with advancing gestational age and the USG cerebellar growth pattern changed progressively. The relation between TCD and gestational age was well correlated. Hence TCD can be used as a reliable and accurate biometric parameter for estimation of gestational age. It is a very useful parameter in assigning gestational age in patients where correct LMP is not known. Cerebellar grading helps in the evaluation of the development of the fetus.

REFERENCES

1. Anirban Das Gupta, Arindome Banerjee, N.Rammurthy, P. Revati, Josna Jose, P. Karak, Anil Kumar. Gestational age estimation using transcerebellar diameter with grading of fetal cerebellar growth. *National J of Clinical Anatomy* 2012;1:115-120.
2. Mustafa Z. Mahamoud, Omer A. Mahamoud, Alsafi A. Abdulla. Fetal transverse Cerebellar Diameter Measurement for prediction of Gestational Age in Pregnant Sudanese Ladies: *International J of Life Science and Medical Resaerch* 2013;31:89-93.
3. Prabhat Goel, Mukesh Singla, Rashmi Ghal, Shilpi Jain, Virendra Budhiraja, C.S. Ramesh Babu. Transverse cerebellar diameter- a marker for estimation of gestational age. *J Anat. Soc. India* 2010;59:158-161.
4. Kazumasa Hashimoto, Takashi Shimizu, Koichiro Shimoya, Toru Kanzaki, James F Clapp, Yuji Murata. Fetal Cerebellum: US appearance with advancing gestational age. *Radiology* 2001;221:70-74.
5. Dr Faiza Naseem, Dr Sabir Ali, Dr Umbreen Basit, Dr Naheed Fatima. Assesment of gestational age; comparison between transcerebellar diameter versus femur length on ultrasound in third trimester of pregnancy. *Professional Med J* 2014;2:412-417.
6. Malik R, Pandya VK, Shrivastava P. Gestational age estimation using transcerebellar diameter with grading of fetal cerebellum and evaluation of TCD/AC ratio as a gestational age independent parameter. *Indian J Radiol Imaging* 2003;13:95-97.

Source of Support: Nil; **Conflict of Interest:** None

Submitted: 18-02-2016; **Published online:** 13-03-2016