

# The Retreatment of a Mandibular Canine with Bifurcated Root

Preet Kanwal Kaur Atwal<sup>1</sup>, Kapil Dua<sup>2</sup>, Ravleen<sup>3</sup>

## ABSTRACT

**Introduction:** Treatment of any endodontic case requires meticulous diagnosis and treatment plan especially keeping in mind the possible anatomic variations that can be encountered.

**Case report:** This paper reports a case of a failed root canal treatment due to inability to identify a bifurcated root of mandibular canine.

**Conclusion:** Identifying the bifurcated root of mandibular canine by careful examination of preoperative radiograph before starting the retreatment, resulted in successful outcome.

**Keywords:** Mandibular canine, Bifurcated root, Anatomic variation and Retreatment.

## INTRODUCTION

Endodontic treatment success like any other medical treatment, relies on removing the foci of infection. This is primarily achieved by a good biomechanical preparation. To achieve this goal, the dentist should acquire knowledge of morphologies of different teeth. Such a background knowledge will prevent any errors in debridement like missed canal. Inadequately treated and missed canal impact the outcome of root canal. The classic studies like the Washington study associate 3% cases of endodontic failures to missed canals.<sup>1</sup> However more recent studies report a higher incidence. Hoen and Pink evaluated 1100 failing endodontic cases and found a 42% incidence of missed canals associated with failure cases.<sup>2</sup> The difference in incidence is because of the different methodologies of investigations. Hoen and pink clinically evaluated these cases under magnification of at least 3.25 power.<sup>2</sup>

## CASE REPORT

A 53 year old female reported to the Department of Conservative Dentistry and Endodontics with the chief complaint of pain in the left lower front tooth. The patient was referred from Department of Periodontology. Patient gave history of root canal treatment from a private clinic three months back after which she continued to have discomfort in her lower front tooth and got treatment in Periodontology department for pockets in relation to the same tooth.

Clinical examination revealed a restored 33. The tooth was tender on percussion. Radiograph revealed widening of periodontal ligament space. Also after meticulous examination of the root outline on the periapical radiograph, a second root was suspected.

Under rubber dam isolation the retreatment was initiated on 33. The guttapercha obturating material was removed and the canal explored with number 8 and 10 K files to locate the second canal. The first few attempts were not successful, after which it was decided to enlarge the canal with a thin tapering bur to the mid root level. After enlarging the coronal half of the root canal, the canal was again explored. A second

root canal was located lingual to the first canal. The root of 33 was thus dividing at the junction of middle and apical one third. The working length radiograph confirmed bifurcation of canal at this level. Biomechanical preparation was done with a combined hand and rotary Protaper instruments. Copious irrigation with 1% sodium hypochlorite was done during treatment.

In the first visit the canals were dried and access cavity was closed with temporary restorative material Cavit (3M ESPE AG, Seefeld, Germany) and patient was recalled after two days. In the second visit metapex intracanal medicament was placed in the root canals and patient recalled after three weeks. Obturation was completed with F2 protaper Gutta Percha points and AH plus sealer. The access cavity was closed with glass ionomer cement (Fuji IX; GC Corp, Japan). The tooth was asymptomatic after first visit and continued to remain so after treatment.

## DISCUSSION

Procuring knowledge of various root canal variations that can be encountered and meticulous diagnosis can prevent many root canal treatment failures. An important reason for failure to identify canal variations is inability to meticulously study the preoperative radiograph.<sup>3</sup> Examine the preoperative radiograph for any abrupt change in radiolucency of root canal and the outline form of the root. Carefully observe the direction your patency file takes when you explore a root canal. Unusually positioned orifices and off centered working length files also warrant looking for more canals.<sup>4</sup> Mandibular canines are the teeth which in 98.3% cases have a single root. In 92.2% cases the root has a single root canal, 4.9% cases have two canals and one foramen and 1.2% have two canals and two foramen. A study on 830 extracted human mandibular canines found only 1.7% teeth with two roots and two separate canals.<sup>5</sup> Cases have been reported in literature with two rooted canine.<sup>6-8</sup> A case has been reported of mandibular canine with two roots but three canals in literature.<sup>9</sup>

In the present case the patient repeatedly visited dentist for three month, to relieve pain in her root canal treated tooth. The correct diagnosis and treatment alleviated her pain. Thus

<sup>1</sup>Associate Professor, <sup>2</sup>Professor and Head, Department of Conservative Dentistry and Endodontics, <sup>3</sup>Associate Professor, Department of Periodontology, Christian Dental College and Hospital, Ludhiana, Punjab, India

**Corresponding author:** Dr Preet Kanwal Kaur Atwal, Associate Professor, Department of Conservative Dentistry and Endodontics, Christian Dental College and Hospital, Ludhiana, Punjab, India

**How to cite this article:** Preet Kanwal Kaur Atwal, Kapil Dua, Ravleen. The retreatment of a mandibular canine with bifurcated root. International Journal of Contemporary Medical Research 2016;3(4):1105-1106.

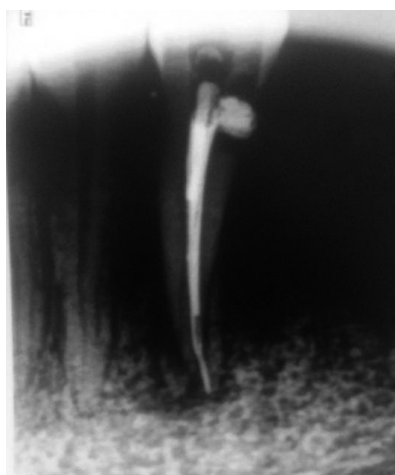

Figure-1: Preoperative radiograph 33

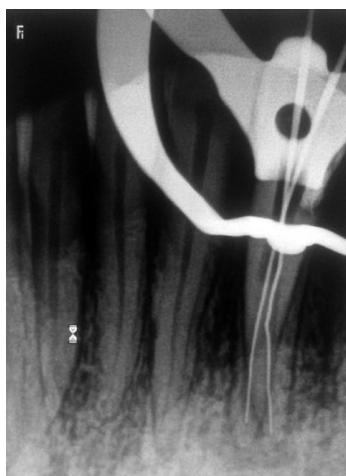


Figure-2: Working length radiograph

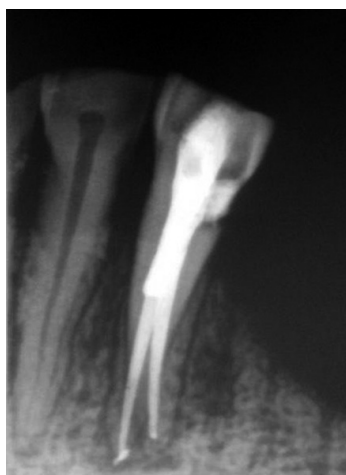

Figure-3: Post Obturation Radiograph 33

it is important to treat every tooth uniquely or else it will lead to failure of endodontic therapy.

## CONCLUSION

Morphological variations in pulpal anatomy must always be considered before beginning treatment. Knowledge about handling such cases should be acquired for a successful treatment outcome. Also careful clinical and radiographical examination is essential for a successful endodontic treatment.<sup>10</sup>

## REFERENCES

1. Ingle JL, Beveridge EE, Glick DH, Weichman JA. Modern endodontic therapy. In: Ingle JL, Bakland LK, eds. Endodontics, 4th Edn. Baltimore, MA: Williams and Wilkins, 1994:27-53.
2. Hoen MM, Pink FE. Contemporary endodontic retreatments: an analysis based on clinical treatment findings. *J Endod* 2002;28:834-836.
3. Bhardwaj A, Bhardwaj A. Mandibular canine with two roots and two canals- A case report. *International Journal of Dental Clinics* 2011;3:77-8.
4. Krasner P and Rankow HJ. Anatomy of the pulp chamber Floor. *J Endod* 2004;30:5-16.
5. Pecora JD, Sousa Neto M, Saquy PC. Internal anatomy direction and number of roots and size of human mandibular canines. *Braz Dent J* 1993;4:53-7.
6. Ouellet R. Mandibular permanent cuspid with with two roots. *J of Canadian Dent Association* 1995;61:159-61.
7. Victorino FR, Bernardes RA, Baldi JV, Moraes IG, Bernardinelli N, Garcia RB, et al. Bilateral mandibular canines with two roots and two canals: case report. *Braz Dent J* 2009;20:84-6.
8. D'Arcangelo C, Varvara G, De Fazio P. Root canal treatment in mandibular canines with two roots: a report of two cases. *Int Endod J* 2001;34:331-4.
9. Heling I, Gottlieb Dadon I, Chandler N. Mandibular canine with two roots and three canals. *Dental Traumatology* 1995;11:301-2.
10. Cantatore G, Berutti E, Castellucci A. *Endodontic Topics* 2009;15:3-31.

**Source of Support:** Nil; **Conflict of Interest:** None

**Submitted:** 16-02-2016; **Published online:** 20-03-2016