

Dentigerous Cyst with Unerupted Teeth in Bilateral Maxilla with Oro Antral Fistula with DM Type I: A Case Report and Review of Literature

S.K. Kashyap¹, Ashwini Kumar², Chandra Bhan³, Siva Selvaraj³

ABSTRACT

Introduction: Dentigerous cyst is an odontogenic cysts that is developmental in origin and lined by epithelium. It arises from the crown part of unerupted, partially erupted or impacted tooth. Mandibular involvement is more common than maxilla. In mandible, third molar is commonly involved; while in maxilla, canine involvement is common. Its association with ectopic teeth in the maxillary sinus is rarely seen.

Case report: In the present paper, we report a case of dentigerous cysts with facial cellulitis as well as Diabetes Mellitus type-1 associated with unerupted tooth in the bilateral maxillary sinus. Also, pathogenesis of ectopic tooth, role of advanced imaging, differential diagnosis, and management are discussed.

Conclusion: Ectopic teeth in the maxillary sinus bilaterally in association with a dentigerous cyst is a rare finding. It is well diagnosed by x-ray and CT scan. The best surgical approach is surgical enucleation combined with extraction of unerupted teeth by Caldwell luc's operation.

Keywords: Dentigerous cyst, ectopic tooth, maxillary sinus, facial cellulitis.

INTRODUCTION

The term "dentigerous cyst" was given by Paget in 1853. This is the most common type of developmental odontogenic cysts and mostly associated with the crowns of permanent teeth, rarely, with the crowns of deciduous tooth¹, complex odontoma², and supernumerary teeth.³ 5-6% of all dentigerous cysts are associated with supernumerary teeth and about 90% of them are associated with a maxillary mesiodens.³ The most reasonable explanation to its pathogenesis appears to be that the accumulation of fluid between the unerupted tooth and the surrounding reduced enamel epithelium leads to formation of the cyst. About 70% of dentigerous cysts occur in the mandible involving third molar while 30% of them present in the maxilla, most commonly involving canine teeth.⁴ Male to female ratio is 2:1. The dentigerous cyst is usually single and rarely multiple or bilateral cysts have been reported in basal cell nevus syndrome, mucopolysaccharidosis (Type 4), Cleidocranial Dysplasia or in a non-syndromic patient.

The dentigerous cyst associated with ectopic teeth in the maxillary sinus is a rare entity, and very few cases have been reported in the literature.⁵ We report a case of dentigerous cysts with unerupted teeth in the bilateral maxilla with oro antral fistula as well as Type-1 Diabetes Mellitus.

CASE REPORT

A 23-year-old male reported with the chief complain of fa-

cial swelling on left side (Figure 1) for 10 days, as well as pus discharging painful oro antral fistula for 3days. Past history revealed that he was having recurrent facial swelling for last 3 years, for that he took treatment. He was having type 1 Diabetes Mellitus. On physical examination, he was having tender facial swelling, soft to firm in consistency. On oral cavity examination, pus discharging fistula was present in upper gingivo-buccal sulcus. On aspiration of the swelling, it yielded turbid yellow colour fluid. The patient's blood sugar was 312gm/dl. Orthopantomogram showed a thinned lined cystic lesion which contained two teeth on Left side while on Right side a small cystic lesion with tooth was present. (Figure 2) CT scan of patient confirmed the findings of OPG. It showed the expansile cystic lesion pushing the floor and lateral wall of nose, eroding floor of maxillary sinus bilaterally; involving maxillary sinus lumen and reaching upto floor of orbit on Left side.(Figure 3) The patients was kept on conservative treatment. Insulin was started to control the blood sugar for 3 days then he was taken for surgical enucleation combined with extraction of teeth by the Caldwell-Luc procedure.(Figure 4)

DISCUSSION

Dentigerous cysts is usually painless and silent until they have enlarged sufficiently to produce expansion of the jaw. It affects commonly white men of third to fourth decade.

The diagnosis of a dentigerous cyst can be made on clinical and radiological examination as well as FNAC. The majorities of small size cysts usually discovered accidentally on routine radiological examination(OPG or Xray). Radiologically dentigerous cyst simulates other jaw cysts as most of them present as well- circumscribed, radiolucent lesions. Computerized Tomography (CT) with a dental CT software program is highly useful for the imaging and management of teeth in the maxillary sinus. Routine CT imaging is debatable and reserved for large lesions to know extension to maxilla, nasal cavity, orbital, or/and pterygomaxillary space.⁶ In our case, orthopantomogram showed a thinned lined cystic le-

¹Associate Professor, ²Senior Resident, ³Junior Resident, Department of ENT, M.L.B.Medical College, Jhansi, U.P., India

Corresponding author: Dr. S. K. Kashyap, Associate Professor, PR-7, Consultant Residence, M.L.B.Medical College, Jhansi, U.P., India

How to cite this article: S.K. Kashyap, Ashwini Kumar, Chandra Bhan, Siva Selvaraj. Dentigerous cyst with unerupted teeth in bilateral maxilla with oro antral fistula with DM type I: a case report and review of literature. International Journal of Contemporary Medical Research 2016;3(4):958-960.

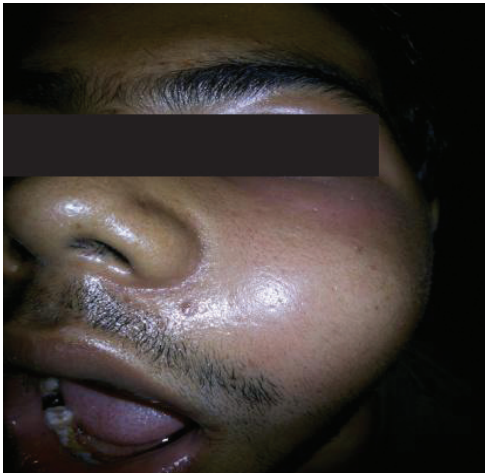

Figure-1: Pt's left side facial swelling

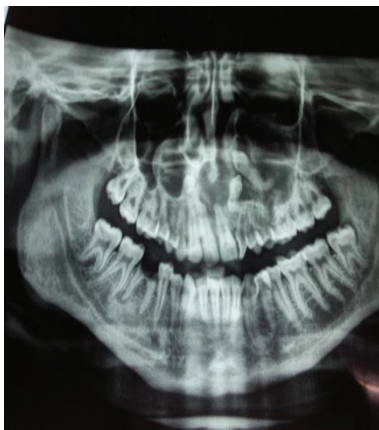

Figure-2: Panoramic radiograph shows bilateral well-defined radiolucencies, Left side cyst wall with fluid along with two unerupted teeth inside the cyst & Right side fluid containing cyst along with unerupted tooth.

sion which contained two teeth on Left side while on Right side a small cystic lesion along with tooth was present. CT scan of patient showed expansile cystic lesion pushing the floor and lateral wall of nose, eroding floor of maxillary sinus bilaterally; involving maxillary sinus lumen and reaching upto floor of orbit on Left side.

Preferred treatment for dentigerous cysts is surgery, in the form of enucleation or marsupialisation. The prognosis is excellent after the enucleation of the cyst and extraction of the unerupted tooth. The recurrence is rarely observed after a complete removal.⁷ It is believed that, the decision whether to enucleate or marsupialise the cyst, depends on various patient factors. Enucleation will alter the normal tooth development while marsupialisation reduces the cyst cavity and preserves the involved tooth in the cyst. Marsupialisation assisted natural eruption of the impacted tooth in the dentigerous cyst is found in 72.4% of subjects. Based on that, it is concluded that marsupialisation promotes the natural eruption of a cyst-associated tooth and thus preferred in the paediatric population. In adult, the impacted teeth normally have only few chances to erupt; therefore enucleation is advised.⁸ Marsupialisation of the large maxillary sinus cyst will consequently create an oroantral fistula, so in these cases surgical enucleation combined with the Caldwell-Luc approach fol-

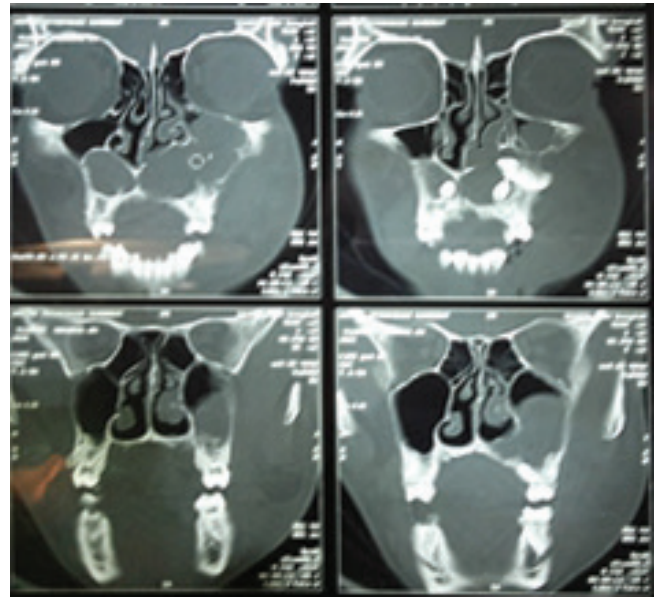


Figure-3: Coronal CT image shows fluid contain cyst present in left maxillary sinus & floor of nose along with anterior wall of maxillary sinus erosion. On right side teeth containing cyst present floor of maxillary sinus.

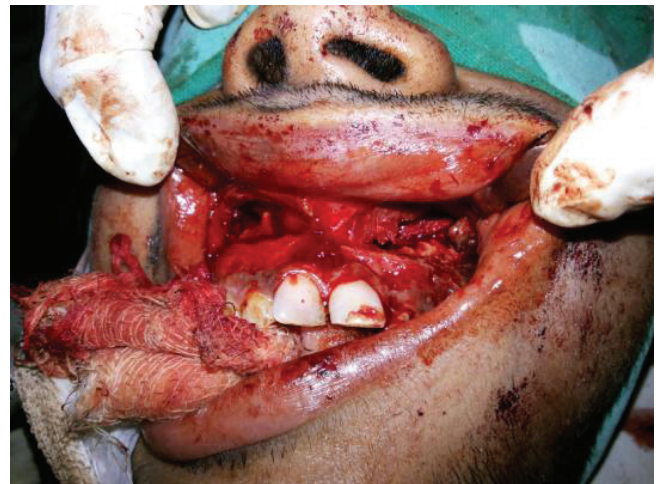

Figure-4: Bilateral Caldwell Luc operation performed

lowed by primary closure is recommended.⁹ Since its introduction, the Caldwell-Luc procedure has become a standard approach for the management of conditions where the wide anterior opening provided by this procedure might prove to be beneficial, such as antral diseases as well as an operative route to reach such sites as the pterygomaxillary space, orbit, ethmoid labyrinth and medial skull base. However the advancements in the field of antibiotic therapy and endoscopic sinus surgery have limited the indications for this operation.

It has also been reported not necessary to perform Inferior Meatal Antrostomy (IMA) for Caldwell-Luc procedure for odontogenic pathology, moreover it closes within 3 months after the operation in 82% of 367 cases.¹⁰

In our case we performed a surgical enucleation with extraction of teeth by the Caldwell-Luc procedure as it provided maximal exposure for the removal of the tooth with large dentigerous cyst that was located laterally and on floor of maxillary sinus and nose. Post operative period was une-

ventful. On follow-up the operative site healed well and the patient is asymptomatic.

CONCLUSION

In conclusion, occurrence of an ectopic tooth in the maxillary sinus in association with a dentigerous cyst is a rare phenomenon. Its presence may be asymptomatic initially with clinical manifestations later because of involvement of adjacent structures. Conventional radiographs are sufficient for the diagnosis, but CT Scan PNS provides additional information about the size and extension of the cyst along with position of the teeth.

Surgical enucleation combined with extraction of unerupted teeth by Caldwell luc's operation is the mainstay to remove the dentigerous cyst.

REFERENCES

1. Kusukawa J, Irie K, Morimatsu M, Koyanagi S, Kameyama T. Dentigerous cyst associated with a deciduous tooth: A case report. *Oral Surg Oral Med Oral Pathol.* 1992;73:415–8.
2. Sales M, Cavalcanti M. Complex odontoma associated with dentigerous cyst in maxillary sinus: Case report and computed tomography features. *Dentomaxillofac Radiol.* 2009;38:48–52
3. Lustmann J, Bodner L. Dentigerous cysts associated with a supernumerary teeth. *Int J Oral Maxillofac Surg.* 1988;17:100–2.
4. Jones AV, Craig GT, Franklin CD. Range and demographics of odontogenic cysts diagnosed in a UK population over a 30-year period. *J Oral Pathol Med.* 2006;35:500–7.
5. Buyukkurt MC, Omezli MM, Miloglu O. Dentigerous cyst associated with an ectopic tooth in the maxillary sinus: A report of 3 cases and review of the literature. *Oral Surg Oral Med Oral Pathol Oral Radiol Endod.* 2010;109:67–71.
6. Kerr JT, Steger J and Sorensen D. Midline maxillary odontogenic keratocyst. *Ann Otol Rhinol Laryngol* 2004; 113:688-690.
7. Hasbini AS, Hadi U and Ghafari J. Endoscopic removal of an ectopic third molar obstructing the osteomeatal complex. *Ear Nose Throat J* 2001;80:667-670.
8. Hyomoto M, Kawakami M, Inoue M and Kirita T. Clinical conditions for eruption of maxillary canines and mandibular premolars associated with dentigerous cysts. *Am J Orthod Dentofacial Orthop* 2003;124:515-520.
9. Kaya O and Bocutoglu O. A misdiagnosed giant dentigerous cyst involving the maxillary antrum and affecting the orbit. *Aust Dent J* 1994;39:165-167.
10. Al-Belasy FA. Inferior meatal antrostomy: is it necessary after radical sinus surgery through the Caldwell-Luc approach? *J Oral Maxillofac Surg* 2004;62:559-562.

Source of Support: Nil; **Conflict of Interest:** None

Submitted: 11-02-2016; **Published online:** 07-03-2016