

Comparative Evaluation of Ilioinguinal/ Iliohypogastric Nerve Block with Spinal Anaesthesia for Unilateral Open Inguinal Hernia Repair

Swati Chhatrapati¹, Anjana Sahu², Smita Patil³

ABSTRACT

Introduction: Inguinal hernia repair is usually performed under spinal anaesthesia. However, local anaesthesia technique provides stable hemodynamics with early ambulation and less postoperative pain. We compared efficacy, feasibility and safety of ilioinguinal/iliohypogastric nerve block for inguinal hernia repair with spinal anaesthesia.

Material and methods: Sixty adult male patients scheduled for elective inguinal hernia repair were randomized into two groups to receive either ilioinguinal/iliohypogastric nerve block or spinal anaesthesia. The total time to perform anaesthetic procedures, time of onset, hemodynamic variations, supplemental sedation, intraoperative fluid requirement, duration of postoperative analgesia and ambulation were compared in both groups. Continuous data are presented as mean±S.D. Unpaired *t*-test and paired *t*-test were applied for intergroup and intragroup comparisons respectively. *P* <0.05 was taken as significant.

Results: Duration to perform ilioinguinal/iliohypogastric nerve block was significantly longer (7.95±0.461 minutes) than that of spinal block (3.73±0.679 minutes). Systolic and mean blood pressure showed statistically significant reduction in first 40 minutes with higher intraoperative fluid requirement in Group II patients (1280±190.1 ml vs 348.33±77.106 ml). Group I patients required higher dose of midazolam (3.00±0.347 vs 2.23±0.254 mg) (*p*<0.05). Supplemental anaesthetic infiltration was required in 36.7% patients in Group I and 45.45% of them required propofol for sedation (55.56±5.11 mg). The duration of postoperative analgesia was longer in Group I (5.163±0.4542 vs 3.871±0.4801 hours) (*p*<0.05). Duration of ambulation was significantly shorter in Group I (3.95±2.56 vs 9.58±0.87 hours) (*p*<0.05).

Conclusion: Ilioinguinal/iliohypogastric nerve block can be a safe alternative to spinal anaesthesia for elective unilateral inguinal hernia repair.

Keywords: Ilioinguinal/iliohypogastric nerve block, spinal anaesthesia, inguinal hernia repair

INTRODUCTION

Open Inguinal hernia repair is one of the commonest procedures performed worldwide. Still, there is no consensus regarding the optimum anaesthesia technique for this surgery. General, spinal, epidural and local anaesthesia techniques have all been used, each having its own advantages and disadvantages.¹ General anaesthesia carries risks of possible airway complications, postoperative deterioration of cognitive function, sore throat, nausea, vomiting and prolonged period of immobilization with associated risk of deep vein thrombosis and longer hospital stay.¹ Spinal anaesthesia, although effective, is not without risk in patients with decompensated heart disease, recent head injury, convulsions and coagulopathies. Also spinal and epidural anaesthesia have

been associated with hemodynamic instability, vomiting, urinary retention, post dural puncture headache, and backache.² Local inguinal field block which includes the blockade of ilioinguinal and iliohypogastric nerves may be an ideal technique as it blocks the surgical stress, provides better hemodynamic stability, extended analgesia, early ambulation and is associated with low risk of complications.³ Harvey Cushing and William Halsted first described the inguinal field block in 1900.⁴ Since then, its efficacy and advantages have been compared by many surgeons and anaesthesiologists in a number of studies. Refinements and modifications in the technique still continue. In 1963, Joseph L Ponka described in great detail a seven step procedure of performing it in 837 patients successfully.⁵ In children, Dalen's technique is a preferred method of analgesia for surgical repair of inguinal hernia. He used a single puncture technique in contrast to the previously used multiple puncture technique.⁶ In our institute, inguinal hernia repair is usually performed under spinal anaesthesia. The aim of this study was to evaluate success, efficacy, feasibility and safety of inguinal field block with single puncture technique and also to compare intraoperative and postoperative complications of inguinal field block with spinal anaesthesia.

MATERIAL AND METHODS

A randomized, prospective, comparative trial "To evaluate the efficacy, feasibility and safety of ilioinguinal and iliohypogastric nerve block by single puncture technique with wound infiltration in comparison to spinal anaesthesia" was conducted in the anaesthesia department of a tertiary medical center after obtaining Institutional Ethics Committee approval and patient's written and informed consent. The exclusion criteria were negative consent, complicated hernias, epilepsy, morbid obesity, anticipated difficult intubation and contraindication of spinal anaesthesia. Sixty male subjects, aged 18 to 65 years, weighing between 40 and 80 kg, belonging to American Society of Anaesthesiologist (ASA) grade I and II, scheduled to undergo elective uncomplicated unilateral inguinal hernia repair were randomly assigned

¹Professor, ²Assistant Professor, Department of Anaesthesiology, Topiwala National Medical College and B.Y.L. Nair Ch. Hospital, Mumbai Central, ³Ex-resident, Anesthesiology, LTMMC/LGMGH, Sion, Mumbai, Maharashtra, India

Corresponding author: Dr. Swati Chhatrapati, 402, Kaniya 10th Road, Khar (w), Mumbai-400052, Maharashtra, India

How to cite this article: Swati Chhatrapati, Anjana Sahu, Smita Patil. Comparative evaluation of ilioinguinal/ iliohypogastric nerve block with spinal anaesthesia for unilateral open inguinal hernia repair. International Journal of Contemporary Medical Research 2016;3(4):1177-1181.

to one of the two study groups each containing 30 patients. Group I was administered ilioinguinal and iliohypogastric nerve block by single puncture technique with wound infiltration and Group II was administered spinal anaesthesia. All patients were familiarized with the Visual Analogue Score (VAS) preoperatively.

On the day of surgery after confirming starvation and consent, intravenous access was secured. In the operating room, patient's heart rate, arterial blood pressure, oxygen saturation and electrocardiogram were monitored. Ringer lactate was started at 2 ml/kg/hr in Group I. Injection midazolam 0.03mg kg⁻¹ was given intravenously (IV) 10 minutes prior to performing inguinal block, in Group I.

Technique of ilioinguinal and iliohypogastric nerve block by single puncture technique with wound infiltration was adapted from modification of the Dalens' technique used in children, described by P Carre' et al.⁶ The skin was prepared with chlorhexidine gluconate and isopropyl alcohol using strict aseptic technique. We used 22 gauge Quincke spinal needle for administering ilioinguinal and iliohypogastric nerve block. Dose of local anaesthetic was calculated according to patient's body weight, i.e bupivacaine 1.5 mgKg⁻¹ and lignocaine with adrenaline 6 mgKg⁻¹. Local anaesthetic solution was prepared by combining 2% lignocaine hydrochloride with adrenaline 1:2,00,000 and 0.5% bupivacaine hydrochloride in a 50:50 mixture, along with normal saline as a diluent, so as to achieve a total volume of 40-60 ml in a concentration of 0.25% bupivacaine and 1% lignocaine. A skin wheal was raised 2cm medial and 2cm superior to the anterior superior iliac spine (Figure-1). Spinal needle was inserted through the skin puncture site perpendicular to the skin. Increased resistance was appreciated as needle encountered the external oblique aponeurosis and first loss of resistance was felt as the needle passes through the muscle to lie between it and the internal oblique. After the initial loss of resistance and negative aspiration for blood, 7-8 ml of local anaesthetic was injected. The needle was then further moved down to appreciate second loss of resistance as it crosses the internal oblique and lie between it and transversus abdominis muscle. Another 7-8 ml of local anaesthetic was injected. Needle was then withdrawn till the skin and redirected at an angle of 45 degrees towards the midpoint of inguinal ligament to pierce the external oblique and the internal oblique muscles. After each loss of resistance, 7-8 ml of local anaesthetic was injected. The remaining 5-6 ml of local anaesthetic was preserved for further supplementation during sac dissection if required.

Patients in Group II received ringer lactate 10 ml/kg as preloading. Spinal anaesthesia was administered in sitting position, with 25 gauge Quincke spinal needle in L3-L4 intervertebral space, under all aseptic precautions and local infiltration, with 3.0 ml of 0.5% bupivacaine (heavy) after ensuring free, clear and adequate flow of cerebrospinal fluid. After giving spinal anesthesia, patient was made to lie supine.

Intraoperatively Group 1 patients received local anaesthetic infiltration and injection midazolam and/or propofol supplementation in graded doses if required especially at the time of sac dissection. However, total dose of midazolam was not

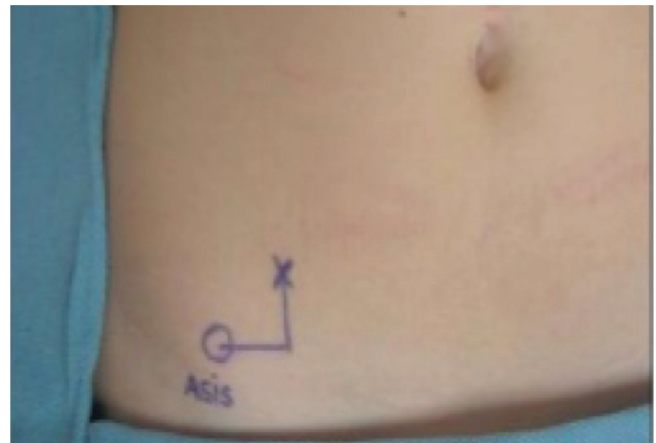


Figure-1: Landmark of ilioinguinal/iliohypogastric nerve block showing puncture site

exceeded above 0.1mgkg⁻¹. Patients in Group II were given Injection midazolam 0.03mg kg⁻¹ IV, for sedation if required during the surgery. All patients received supplemental oxygen (2-3 L/min) via nasal prongs. Hypotension defined as systolic blood pressure (SBP) < 90mmHG or >20% reduction in preoperative SBP was managed with fluids and vasopressor aliquots. Injection atropine was administered in cases of bradycardia defined as pulse rate (PR) < 50/min. Standard general anaesthesia (GA) was administered in cases of failure of block or spinal anaesthesia.

The following parameters were studied intraoperatively:

Total time taken for performing the procedure of anaesthesia, either local inguinal field block or spinal anaesthesia (in minutes) i.e. the time taken from the aspiration of drugs till the completion of the procedure, time of onset of action of block or spinal anaesthesia in minutes, intraoperative monitoring – PR, SBP, diastolic blood pressure (DBP), mean arterial pressure (MAP) and oxygen saturation (SPO₂) every 10 minutes till the end of surgery, intraoperative requirement of intravenous fluid and vasopressors, supplementation required in the form of local anaesthetic infiltration, IV midazolam and Propofol, intraoperative complications like hypotension, bradycardia, nausea and vomiting and the duration of surgery. Postoperatively, patient was shifted to post anaesthesia care unit and was monitored for pulse, blood pressure, oxygen saturation, VAS score, any postoperative complications like nausea, vomiting, urinary retention, postdural puncture headache and duration of ambulation. Rescue analgesia was given in the form of IV tramadol 1mgkg⁻¹ when VAS score was ≥ 4. Total duration of analgesia was defined as the time interval from the end of surgery till the VAS score was ≥ 4. Duration of ambulation was the time interval from the end of surgery till the patient could start walking without support.

STATISTICAL ANALYSIS

Continuous variables were presented as mean±standard deviation. Unpaired t-test and paired t-test were applied for intergroup and intragroup comparison of parameters respectively. P value<0.05 was considered as statistically significant.

RESULTS

Demographic data and duration of surgery were comparable in both the groups (Table 1 and 2). Total time taken for

performing the procedure of ilioinguinal and iliohypogastric nerve block was significantly longer than that of spinal block (7.95 ± 0.461 Group I vs 3.73 ± 0.679 minutes Group II $p < 0.05$) but onset of action was comparable in both the groups (6.567 ± 0.4037 in Group I vs 6.224 ± 1.0487 min in Group II $p = 0.101$). Systolic and mean blood pressure showed statistically significant reduction in first 40 minutes ($p < 0.05$) and intraoperative fluid requirement was statistically higher in Group II (1280 ± 190.1 ml vs 348.33 ± 77.106 ml) ($p < 0.05$). None of the patients in either group developed bradycardia and required vasopressors. However, Group I patients required statistically higher dose of midazolam (3.00 ± 0.347 vs 2.23 ± 0.254 mg) ($p = 0.000$). Supplemental local anaesthetic infiltration was required during handling of sac in 36.7% and out of those 36.7%, 45.45% of patients required additional sedative dose of propofol (55.56 ± 5.11 mg) in Group I. The duration of postoperative analgesia was longer in Group I (5.163 ± 0.4542 vs 3.871 ± 0.4801 hours) ($p < 0.05$). 10 % patients had failure of inguinal field block where as spinal anaesthesia failed in 3.3% patients. Duration of ambulation was significantly shorter in Group I as compared to Group II (3.95 ± 2.56 vs 9.58 ± 0.87 hours) ($p < 0.05$) (Table 2).

DISCUSSION

Inguinal hernia repair which is the commonest surgery has been performed under general, spinal, epidural and local anaesthesia techniques with varying success. According to recent guidelines of European Hernia Society, in the case of an open repair, local anaesthetic should be considered for all adult patients with a primary reducible unilateral inguinal hernia.⁷ This is a grade A recommendation. In spite of this, there is great level of inertia in adopting this technique among anaesthesiologists. Inguinal field block is one of the oldest techniques, in practice since decades.⁸ Initially, local

anaesthesia was given by the surgeon at the site of operation but that did not provide complete anaesthesia. Ilioinguinal and iliohypogastric nerve block provide somatic block over the lower abdomen and visceral pain is often relieved by giving supplemental local anaesthetic at the time of sac dissection. In this study we evaluated the efficacy, feasibility, safety, advantages and complications of ilioinguinal and iliohypogastric nerve block by single puncture technique combined with wound infiltration through same puncture, as compared to spinal anaesthesia.

We chose the modification of Dalens' technique used in children, as described by P Carre et al.⁶ The advantage of using single puncture technique is less discomfort to the patient by avoiding multiple pricks as described in classical technique. Multiple puncture techniques of inguinal field block were associated with transient femoral nerve palsy causing weakness of knee extensors^{2,9}, cord haematoma⁹, thrombosis of the dorsal vein of penis¹⁰, wound haematoma and wound infection.¹¹⁻¹³ In our study we did not observe any of such complications with single puncture technique as our injection site was close to anterior superior iliac spine and far from operative field, femoral nerve and pubic tubercle. N Sasaoka et al in their study concluded that there is little clinical benefit of additional genitofemoral nerve block in terms of intra and postoperative analgesia.¹⁴ Shandling et al found increased incidence of haematoma formation within the cord in patients who received genitofemoral nerve block.¹⁵ Hence, we decided not to perform separate genitofemoral nerve block.

Quincke spinal needle (22 gauge, 90mm) allows the wound infiltration throughout the incision line through the same puncture. Its short bevel provides correct identification of tissue planes with better appreciation of loss of resistance, allows effective spread of local anaesthetic solution to both the nerves and causes less trauma to blood vessels, muscle

Parameter	Group I (30) mean \pm SD	Group II (30) mean \pm SD	p-value
Average age (years)	42.33 \pm 13.353	41.83 \pm 12.371	0.881
Average Weight (Kilograms)	55.83 \pm 5.584	58.23 \pm 5.151	0.089
Average height (centimeters)	157.9 \pm 5.068	158.9 \pm 4.413	0.418

Table-1: Demographic Data

	Group I	Group II	p-value
ASA Grade (%)			
I	21(70%)	20(66.7%)	0.781
II	9(30%)	10(33.3%)	0.690
Mean duration for procedure (Min)	7.95 \pm 0.461	3.73 \pm 0.679	0.000
Onset of action (Min)	6.567 \pm 0.4037	6.224 \pm 1.0487	0.101
Intravenous fluid requirement (ml)	348.33 \pm 77.106	1280 \pm 190.1	0.000
Mean dose of midazolam (mg)	3.00 \pm 0.347	2.23 \pm 0.254	0.000
Mean dose of propofol (mg)	55.55	-	-
Duration of surgery (min)	84.00 \pm 10.120	85.17 \pm 7.822	0.619
Block failure (%)	3 (10%)	1 (3.3%)	
Intraoperative Hypotension (%)	0	5 (16.67%)	0.014
Urinary retention	0	05(16.67%)	0.014
Nausea and Vomiting	0	01(3.3%)	0.309
PDPH	0	01(3.3%)	0.309
Duration of ambulation (hour)	3.95 \pm 2.557	9.58 \pm 0.872	0.000
Duration of analgesia (hour)	5.163 \pm 0.4542	3.871 \pm 0.4801	0.00

Table-2: Intraoperative and postoperative comparison of various parameters

and bowel.⁶

Adequate premedication allows the patient to remain calm and quiet during local anaesthetic infiltration. In our study, premedication was sufficient in the form of short acting benzodiazepine (midazolam) in the dose of 0.02-0.03mgkg⁻¹ which was given to all patients in Group I.

The mean time taken for performing ilioinguinal and iliohypogastric nerve block was higher than spinal anaesthesia and was statistically significant (7.95±0.461vs 3.73±0.679 minutes). It was probably due to time spent in identification of correct planes for injecting local anaesthetic solution and wound infiltration.

The onset time of surgical anaesthesia was almost similar in both the groups. (6.567±0.4037 in Group I vs 6.224±1.0487 min. p>0.05). We did not experience any significant changes in heart rate and none of the patients in either group, especially Group II where spinal anaesthesia was given, developed bradycardia. The Group II had a statistically significant decrease in SBP in the first 40 minutes of spinal anaesthesia as compared to preoperative values and there was significant difference in systolic blood pressure between both the groups in first 40 minutes. This effect is due to the sympathetic blockade caused by spinal anaesthesia, leading to vasodilatation, peripheral venous pooling of blood and decreased cardiac output. Five patients in Group II had hypotension, which responded to head low position and fluid therapy. Fall in DBP was not significant as spinal level was maintained till T8 dermatome and the compensatory vasoconstriction of upper part of body maintained the total peripheral resistance. In Group II, the mean arterial pressure showed a significant fall for first 30 minutes after spinal anaesthesia, but values were well above the range at which compensatory autoregulation sets in. (Figure 2). Aysun Yilmazlar et al found a significant decrease in mean arterial pressure in spinal anaesthesia group (pre 70.3±10.3mmHg and post 52.3±9.3 mmHg) and no such fall in ilioinguinal and iliohypogastric nerve block group.¹⁶ Our findings are also in confirmation with the study conducted by Nehme et al who found that the incidence of hypotension was highest in cases of spinal anaesthesia (19%),¹⁷ while it was negligible in cases of inguinal block. Similar results were also reported by Tingwald and Cooperman.¹⁸

The mean intraoperative intravenous fluid requirement was considerably higher in Group II (1280±190.1 ml vs 348.33±77.106ml). The higher fluid requirement in spinal anaesthesia group is because of sympathetic blockade, which expands the intravascular compartment necessitating rapid intravascular infusion to maintain the good intravascular volume and blood pressure. Therefore ilioinguinal and iliohypogastric nerve block can be a technique of choice in patients with low ejection fraction.

However ilioinguinal and iliohypogastric nerve block does not ameliorate visceral pain, which occurs at the time of sac handling which can be taken care of by additional local anaesthetic infiltration and/or sedative agents. In our study, 36.7% (11) patients in Group I required additional dose of local anaesthetic infiltration at the time of sac handling out of which 45.45% (5) patients required Propofol sedation (55.56±5.11mg). Also, the sedative dose of midazolam was provided in all the patients of Group I as part of premedi-

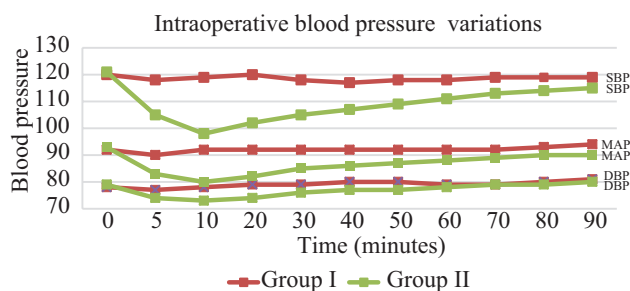


Figure-2: Intraoperative blood pressure variations

ation while 50% of patients required midazolam to relieve anxiety during the surgery in Group II. A variety of drugs like diazepam, pethidine and Propofol have been used for conscious sedation, by various authors during inguinal field block. Pethidine and diazepam have sedative effects, which can persist postoperatively for 6-8 hours, thus delaying recovery and ambulation. Propofol has now become the drug of choice for conscious sedation because it has rapid onset of action, titrable drug levels and a short half life that leads to rapid clear headed recovery without nausea and vomiting and patients can meet discharge criteria sooner. We have used midazolam which provides effective sedation and amnesia with short duration of action.^{13,16} Since midazolam gives good amnesia, we found that inguinal nerve block was fairly acceptable even in patients who had experienced mild discomfort intraoperatively. None of the patients in Group I was excessively drowsy, requiring prolonged stay in PACU or delaying ambulation as the sedative dose was well within the therapeutic range. The intraoperative and postoperative oxygen saturation (SPO₂) were comparable and maintained around 99% in both the groups. None of our patients developed nausea and vomiting intraoperatively.

There was one spinal anaesthesia failure (3.3%) in Group II who was given general anaesthesia. In Group I three patients (10%) had to be given general anaesthesia because of inadequate block. Eleven patients experienced discomfort during dissection of hernia sac and the pain subsided after 4-5 ml of local anaesthetic infiltration at the neck of sac. In similar studies done by Sultana A et al¹⁹ and Ruben N Van Veen et al¹³ using standard inguinal field block, intraoperative discomfort of moderate grade during the dissection of hernia sac was reported in 34% and 35% patients respectively. Failure rate for local inguinal field block was 3.33% as reported by C J Sparks et al⁹ and for local infiltration anaesthesia, it was 3.17% as reported by Aysun Yilmazlar et al¹⁶ as compared to 10% in our study. The failure rate can be minimized with further experience and skill in this technique.

The postoperative VAS score was significantly higher in Group II as compared to Group I. Duration of Postoperative analgesia was significantly longer (5.163±0.4542 vs 3.871±0.4801 hours) in Group I as compared to Group II. Similar findings were also observed by Sultana A et al¹⁹ and Tverskoy et al.²⁰

Postoperative complications - 3.33% of patients had nausea, and vomiting which responded to IV ondansetron, 16.67% of patients developed urinary retention and 3.33% of patients had PDPH in Group II. None of patients in Group I had any of these complications. Similar results were also observed by Young et al¹¹ (urinary retention 14%) and Sultana A et al¹⁹

(urinary retention 7% and PDPH 8%). None of our patients developed wound haematoma or local infection.

Duration of ambulation was longer in Group II as compared to Group I (9.58 ± 0.87 vs 3.95 ± 2.56 hours) ($p < 0.05$). Song D et al found that the time-to-home readiness in ilioinguinal iliohypogastric block was shortest (133 ± 68 min) as compared to SA (280 ± 83 min).²¹ Ding Y and White PF also found that the ambulation time in block group was (86 ± 18 min) and fit to discharge time was (112 ± 49 min).²² Goutorbe P et al found that the mean time until discharge was 6.85 h in block group and concluded that it should be a preferred method in countries with a low Gross National Product (GNP) like in Africa.²³

Although USG guided technique for nerve block is preferred over blind technique,²⁴ Trainor D et al in their study comparing both the techniques for the treatment of chronic postherniorrhaphy groin pain did not find statistically significant difference in postoperative VAS pain scores between both groups.²⁵

CONCLUSION

The ilioinguinal and iliohypogastric nerve block is associated with better hemodynamic stability, less postoperative complications, longer duration of analgesia and early ambulation as compared to spinal anaesthesia and hence can be an alternative anaesthetic technique for patients with complex medical conditions which make them unsuitable for SA and GA. Short hospital stay and cost effectiveness with extended duration of postoperative analgesia makes it more acceptable.

REFERENCES

- Amado WJ. Anesthesia for hernia surgery. *Surg Clin North Am.* 1993;73:427-38.
- Vincent J, Collins. Spinal anaesthesia- principles and spinal analgesics-Physiological effects. *Principles of Anaesthesiology: general and regional anaesthesia*-third edition. Lea and Febiger, Philadelphia 1993;1445-1516.
- Callesen T1, Bech K, Kehlet H. The feasibility, safety and cost of infiltration anaesthesia for hernia repair. *Hvidovre Hospital Hernia Group. Anaesthesia.* 1998;53:31-5.
- Flanagan L Jr, Bascom JU. Repair of the groin hernia. Outpatient approach with local anesthesia. *Surg Clin North Am.* 1984;64:257-67.
- Ponka JL. Seven steps to local anesthesia for inguino-femoral hernia repair. *Surg Gynecol Obstet.* 1963;117:115-20.
- Carré P, Mollet J, Le Poutel S, Costey G, Ecoffey C. Ann Fr Anesth Reanim. Ilio-inguinal Ilio-hypogastric nerve block with a single puncture: an alternative for anesthesia in emergency inguinal surgery. 2001;20:643-6.
- M. P. Simons et al. European Hernia Society guidelines on the treatment of inguinal hernia in adult patients *Hernia.* 2009;13:343-403.
- Farquharson EL. Early ambulation; with special reference to herniorrhaphy as an outpatient procedure. *Lancet.* 1955;269:517-9.
- Sparks CJ, Rudkins GE, Agiomea K, Fa'arondos JR. Inguinal field block for adult inguinal hernia repair using a short bevel needle. Description and clinical experience in Solomon island and an Australian teaching hospital. *Anaesthesia and Intensive care.* 1996;23:143-48.
- Nicholls JC. Necessity into choice: an appraisal of inguinal herniorrhaphy under local anaesthesia. *Annals of Royal College of Surgeons of England* 1977;59:124-7.
- Young DV. Comparison of local, spinal, and general anesthesia for inguinal herniorrhaphy. *Am J Surg.* 1987;153:560-3.
- Callesan T, Bech K, Kehlet H. The feasibility, safety and cost of infiltration anaesthesia for hernia repair. *Anaesthesia* 1998; 53:31-35.
- van Veen RN, Mahabier C, Dawson I, Hop WC, Kok NF, Lange JF, Jeekel J. Spinal or local anesthesia in lichtenstein hernia repair: a randomized controlled trial. *Ann Surg.* 2008;247:428-33.
- Sasaoka N1, Kawaguchi M, Yoshitani K, Kato H, Suzuki A, Furuya H. Evaluation of genitofemoral nerve block, in addition to ilioinguinal and iliohypogastric nerve block, during inguinal hernia repair in children. *Br J Anaesth.* 2005;94:243-6.
- Shandling B, Steward DJ. Regional analgesia for postoperative pain in pediatric outpatient surgery. *J Pediatr Surg.* 1980;15:477-80.
- Yilmazlar A1, Bilgel H, Donmez C, Guney A, Yilmazlar T, Tokat O. Comparison of ilioinguinal-iliohypogastric nerve block versus spinal anesthesia for inguinal herniorrhaphy. *South Med J.* 2006;99:48-51.
- Nehme AE. Groin hernias in elderly patients. Management and prognosis. *Am J Surg.* 1983;146:257-60.
- Tingwald GR, Cooperman M. Inguinal and femoral hernia repair in geriatric patients. *Surg Gynecol Obstet.* 1982;154:704-6.
- Sultana A1, Jagdish S, Pai D, Rajendiran KM. Inguinal herniorrhaphy under local anaesthesia and spinal anaesthesia--a comparative study. *J Indian Med Assoc.* 1999;97:169-70,175.
- Tverskoy M, Cozacov C, Ayache M, Bradley EL Jr, Kissin I. Postoperative pain after inguinal herniorrhaphy with different types of anesthesia. *Anesth Analg.* 1990;70:29-35.
- Song D, Greulich NB, White PF, Watcha MF, Tongier WK. Recovery profiles and costs of anesthesia for outpatient unilateral inguinal herniorrhaphy. *Anesth Analg.* 2000;91:876-81.
- Ding Y, White PF. Post-herniorrhaphy pain in outpatients after pre-incision ilioinguinal-hypogastric nerve block during monitored anaesthesia care. *Can J Anaesth.* 1995;42:12-5.
- Goutorbe P, Lacroix G, Pauleau G, Daranda E, Goin G, Bordes J, Meaudre E, Balandraud P. Treatment of inguinal hernia in a difficult environment: feasibility and efficacy of ilioinguinal and iliohypogastric blocks. *Med Sante Trop.* 2013;23:202-5.
- Yang L, Xu Y, Wang Z, Zhang W. Application of Ultrasound-Guided Ilioinguinal/Iliohypogastric Nerve Block in Pediatric Same-Day Surgery. *Indian J Surg.* 2015;77:512-6.
- Trainor D, Moeschler S, Pingree M, Hoelzer B, Wang Z, Mauck W, Qu W. Landmark-based versus ultrasound-guided ilioinguinal/iliohypogastric nerve blocks in the treatment of chronic postherniorrhaphy groin pain: a retrospective study. *J Pain Res.* 2015;8:767-70.

Source of Support: Nil; **Conflict of Interest:** None

Submitted: 01-03-2016; **Published online:** 01-04-2016