

CASE REPORT

Interdisciplinary Treatment of Severe Bimaxillary Dentoalveolar Protrusion in Adult With Generalized Periodontitis - A Case Report

Kshama D. Gaitonde¹, Amit Kumar Mendiratta², Karishma Parkar³, Nandini Kamat⁴

ABSTRACT

Introduction: Adult periodontitis is most prevalent form of periodontitis resulting in attachment loss that produces esthetic and functional problems for the patient. Periodontal disease must be controlled before any orthodontics begin, because orthodontic tooth movement superimposed on poorly controlled periodontal health can lead to rapid and irreversible breakdown of the periodontal support apparatus. However, careful diagnosis and judicious management of these potentially volatile patients can alleviate the risk.

Case Report: This paper describes an interdisciplinary approach in treatment of severe bimaxillary dentoalveolar protrusion in an adult female with generalized periodontitis.

Conclusion: Integrating orthodontics and periodontics for management of patient with underlying periodontal defects enhanced the periodontal health as well as esthetics and function.

Keywords: Interdisciplinary, ortho-perio, bimaxillary protrusion with periodontitis

How to cite this article: Kshama D. Gaitonde, Amit Kumar Mendiratta, Karishma Parkar, Nandini Kamat. Interdisciplinary treatment of severe bimaxillary dentoalveolar protrusion in adult with generalized periodontitis - a case report. *International Journal of Contemporary Medical Research* 2015;2(5):1270-1273.

¹Lecturer, Department of Orthodontics and Dentofacial Orthopedics, ⁴Professor & Head, Department of Orthodontics and Dentofacial Orthopedics, Goa Dental College and Hospital, Bambolim, ³Private Practitioner, Margao, Goa, ²Senior Lecturer, Department of Orthodontics and Dentofacial Orthopedics, Faculty of Dental Science, Dharmsinh Desai University, Gujarat, India

Corresponding author: Dr Kshama D. Gaitonde, MDS, Lecturer, Department of Orthodontics and Dentofacial Orthopedics, Goa Dental College and Hospital, Bambolim, Goa, India

Source of Support: Nil

Conflict of Interest: None

INTRODUCTION

Interdisciplinary treatment of the adult population can produce significant benefits in psychosocial well-being, jaw function, dental/oral health and improved outcomes in treatment of dental disease.^{1,2}

Adult periodontitis is the most common form of periodontitis marked by loss of connective tissue attachment and usually gingival inflammation. The attachment loss can result in pathological migration or labial inclination of the incisors, producing esthetic and functional problems for the patient. Therefore, adult therapy requires establishment of goals and efficient mechanotherapy to produce the best combination of dental occlusion, dental and facial esthetics, functional improvement and stability of the result to maximize benefit to the patient.³⁻⁵

This case report illustrates the interdisciplinary treatment that has enhanced periodontal health and smile esthetics of an adult patient with bimaxillary dental protrusion, diagnosed with generalized periodontitis.

CASE REPORT

A 26 year old female patient reported with a chief complaint of forwardly placed upper front teeth and gradual increase in spaces between her front teeth. The patient had no systemic illness and no signs and symptoms of TMD.

Extraoral examination (Fig.1A) in the frontal plane revealed a symmetric face with coincident midlines, potentially incompetent lips and increased interlabial gap of 9 mm. Vertical assessment of face showed a reduced lower face height. Smile analysis revealed a non-consonant smile with 8mm of upper incisor show. Clinically, profile view showed a convex profile with acute nasolabial angle, protrusive lips, normal chin form and average mandibular plane angle.

Intra oral soft tissue examination showed inflamed gingival tissue with moderate gingival recession in 11,12 region. Periodontal probing showed periodontal pockets in 11,12,21,22,16,26,31,32,41,42,36 and 46 region, as well as bleeding on probing. The pocket depth varied from 4-6mm in the maxillary incisors and first molars. Patient had Grade II mobility of 11,12,21,22,31,32,41,42 and grade I mobility of 15,16,26,36,46.

Dental examination (Fig.1B) revealed class I canine and molar relation bilaterally, 5mm overjet and 2mm overbite with 8mm of spacing in the upper arch and 4mm spacing in the lower arch.

Cephalometric evaluation (Fig.4A) revealed normal size maxilla and mandible, class I skeletal pattern and horizontal growth direction with severely proclined and protruded upper and lower incisors. Panoramic radiograph (Fig.4B) showed generalised bone loss in maxillary and mandibular

Parameters	Pre-treatment	Post-treatment
SN length (mm)	70 mm	70 mm
SN- FH	7°	7°
SNA	85°	86.5°
SNB	84°	84°
NB to Pg (mm)	3 mm	3 mm
ANB	1°	2.5°
Wits (mm)	+2 mm	0 mm
Angle of convexity	6°	6°
FMA	18°	18°
SN – Go Gn	25°	25°
Jarabak's ratio	69.4%	69%
Mx OP to TVL	91°	95°
I to NA (mm)	11.5 mm	2.5 mm
I to NA (deg)	39°	19°
I to SN	128°	106°
I to TVL (mm)	+2 mm	-5.5 mm
I to Mx OP (degree)	47°	58°
I to NB (mm)	12 mm	4.5 mm
I to NB (deg)	4°	28°
IMPA	110°	98°
I to TVL (mm)	-2 mm	-9 mm
I to Mn OP (degree)	51°	64°
Overjet	5 mm	3 mm
Overbite	2 mm	3 mm

Table-1: Cephalometric measurements.

anterior teeth and first molars.

Treatment Objectives:

The orthodontic objectives for this patient were (1) to improve function and esthetics and to bring periodontal disease under control, (2) to continuously reassess oral hygiene maintenance and patient motivation (3) to correct protrusive lips and achieve soft tissue balance, (4) to correct the incisor proclination and spacing of maxillary and mandibular region, (5) to achieve ideal overjet and overbite and to maintain class relation bilaterally and.

Treatment Alternatives

Two options for achieving the treatment objectives were considered. The first was to close anterior spacing only to allow lingual retraction. This option could moderately correct the proclination of incisors, and the treatment time would be relatively short, but achieving adequate soft tissue balance would be difficult. The second option was to extract both maxillary and mandibular first premolars. This option would permit lingual retraction of the anterior teeth to correct bialveolar dental protrusion. It was decided to observe the patient's motivation and oral hygiene maintenance before deciding on extraction plan. The treatment options were presented to the patient and discussed. The extraction plan was decided to achieve the final desired soft tissue balance and esthetics.

Treatment Plan

A Pre-orthodontic phase included meticulous cleaning and

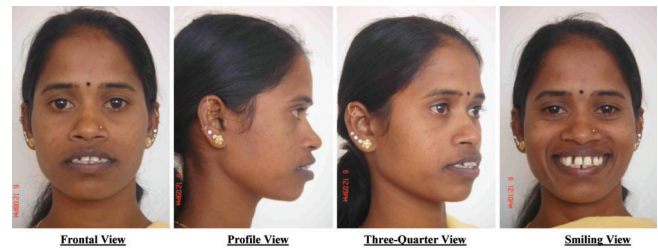

Figure-1A: Pre-treatment extra-oral photographs

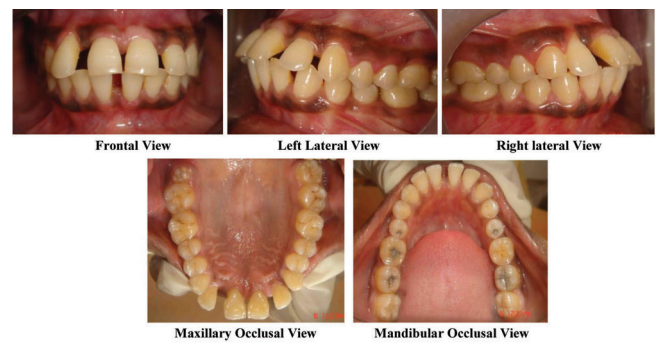


Figure-1B: Pre treatment Intra-oral photographs

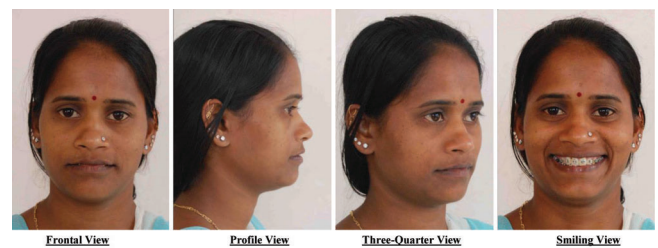

Figure-2A: Pre Debanding Extra-oral Photographs

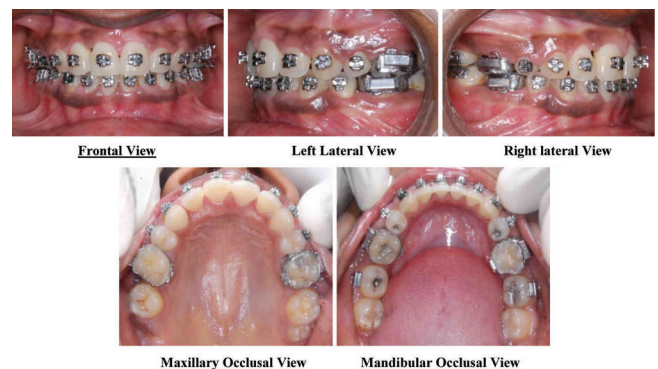


Figure-2B: Pre Debanding Intra-oral Photographs

root surface preparation and debridement with open flap procedures. Initially closure of all the existing spaces was planned to moderately correct proclination of upper and lower incisors.

As patient was well motivated to maintain a good oral hygiene and periodontal disease was under control, extractions of upper and lower first premolars were carried out to retract anterior teeth and achieve ideal soft tissue balance.

Treatment Progress

A Pre-orthodontic phase of open-flap curettage and root planning was carried out. After periodontal reevaluation to ensure that patient was maintaining good oral hygiene and

no active disease was prevailing, a tip-edge appliance with 0.22" slot was bonded. After reassessing the periodontal health status and closure of anterior spaces, first premolars in all quadrants were extracted to correct bimaxillary dental protrusion. The wire sequences used are as follows:

1. U/L 0.016 SS for bite opening during stage I
2. U/L 0.020 SS for closure of spaces during stage II
3. U/L 0.021X0.025 SS during stage III

The overall active orthodontic treatment duration was 24 months. Removable circumferential retainers were used during retention phase.

Treatment Results

Most of the treatment objectives were achieved (Table1). There was marked improvement in facial esthetics with consonant smile and lip competency (Fig.2A,3A). Bialveolar dental protrusion was corrected and all extraction spaces were closed at the end of treatment. A Class I molar and canine relationship was maintained and normal overjet and overbite relationship was achieved (Fig. 2B,3B). During orthodontic treatment periodontal health was improved and angular bony defects in first molars were corrected partially. (Fig. 5)

DISCUSSION

Periodontal considerations are increasingly important in adult orthodontic patient. The periodontal evaluation must include not only response to periodontal probing but also the level and condition of periodontal apparatus.^{2,3}

Periodontally compromised adult patients seeking orthodontic treatment have to be motivated throughout the treatment phase to maintain good oral hygiene. Clinical studies have shown that orthodontic tooth movement in such patients can be completed without loss of attachment, provided there is good periodontal therapy both initially and during tooth movement.^{4,5} The effectiveness of orthodontic treatment for patients with periodontal disease is enhanced by eliminating inflammatory factors with periodontal therapy along with a strict oral hygiene program, including brushing, chemical aids like chlorhexidine mouth rinses and periodical scaling every 3 months.

'Facilitative orthodontics'⁶ along with periodontics can establish physiologic alveolar crestal topography. Hirschfeld⁷ pointed out that position of teeth in relation to alveolar bone affects the shape and location of periodontium. Teeth can be used as a 'handle' to push or pull healthy periodontium to a new desired position within the phenotypic potential.

With these interdisciplinary procedures and proper guidelines followed, it was possible to complete orthodontic treatment in periodontally compromised patient without further attachment loss and create an environment conducive to good oral hygiene. It was gratifying to see the change in patient's self perception and increased levels of confidence at the completion of treatment.

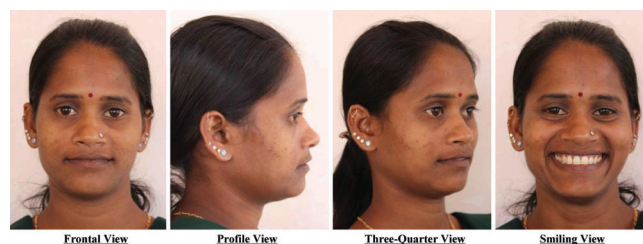

Figure-3A: One Year Post treatment extra-oral photographs

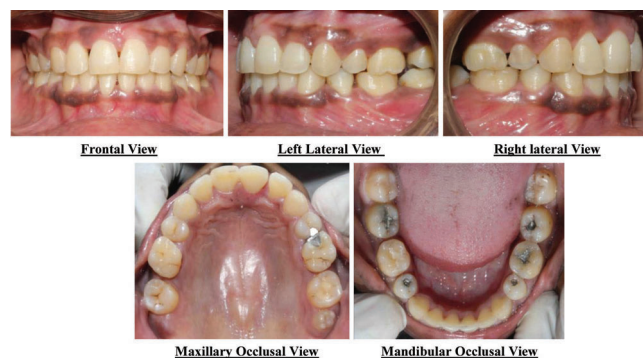


Figure-3B: One Year Post treatment Intra-oral photographs

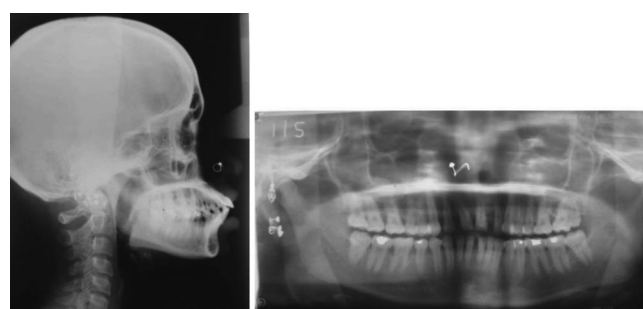


Figure-4: Pre Treatment Radiographs

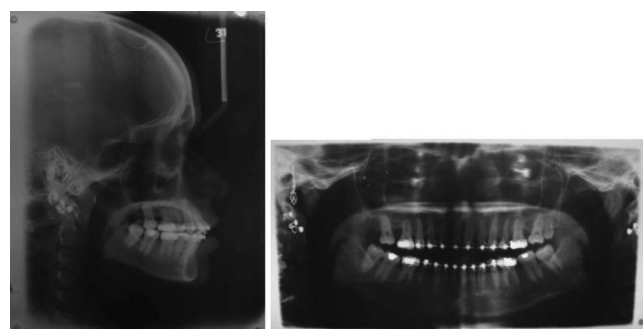
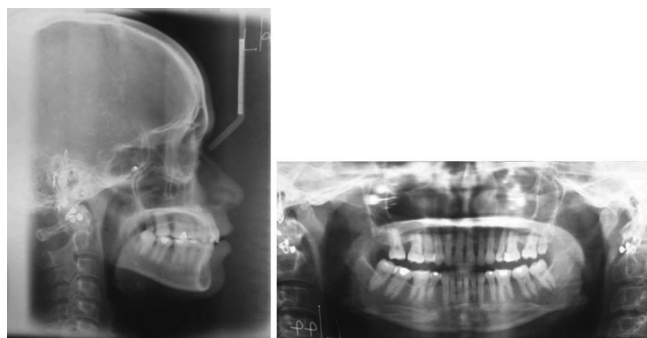


Figure-5: Pre Debanding Radiographs

CONCLUSION

Integrating orthodontics and periodontics for management of patient with underlying periodontal defects enhanced the periodontal health as well as esthetics and function. The most important considerations to treating these type of patients is proper diagnosis, use of lighter orthodontic forces and greater moments along with additional professional and personal plaque control measures to preserve the health of the periodontium.



A. Lateral cephalogram

B. Orthopantomograph

Figure-6: One Year Post Treatment Radiographs

REFERENCES

1. Vanarsdall RL. Adult orthodontics: Diagnosis and treatment. In: Graber TM, Swain BF (4 ed). Orthodontics: Current Principles and Techniques. St Louis: Mosby, 1985.
2. Melsen B, Agerbak N, Eriksen J, Terp S. New attachment through periodontal treatment and orthodontic intrusion. Am J Orthod Dentofacial Orthop 1988;94:104-16.15.
3. Proffit WR, Fields HW, Sarver DM. Special considerations in treatment for adults. Contemporary Orthodontics, 4th edition, Elsevier: Mosby, 2009.
4. Årtun J, Urbye KS. The effect of orthodontic treatment on periodontal bone support in patients with advanced loss of marginal periodontium. Am J Orthod Dentofacial Orthop 1988; 93:143-8
5. Boyd RL, Leggott PJ, Quinn RS, et al. Periodontal implications of orthodontic treatment in adults with reduced or normal periodontal tissues versus those of adolescents. Am J Orthod Dentofacial Orthop 1989;96:191-199
6. Mirham WL, Murphy NC. The orthodontist role in 21st century periodontic-prosthodontic therapy. Semin Orthod 2008;14:272-289
7. Hirshfeld I: A study of skulls in American museum of natural history in relation to periodontal disease. J Dent Rest 5:2-41, 1923.
8. Towfighi PP, Brunsvold MA, Storey AT, Arnold RM, Willman DE, McMahan CA. Pathologic migration of anterior teeth in patients with moderate to severe periodontitis. J Periodontol 1997;68:967-72.
9. Martinez-Canut P, Carrasquer A, Magan R, Lorca A. A study on factors associated with pathologic tooth migration. J Clin Periodontol 1997;24:492-7.
10. Kokich V, Nappen D, Shapiro P: Gingival contour and clinical crown length: their effects on esthetic appearance of maxillary anterior teeth. Am J Orthod Dentofac Orthop. 1984;86-89
11. Kokich V: Esthetics:- the Orthodontic-periodontic-restorative correction. Semin Orthod 1996;2:21.
12. Mathews DP, Kokich VG. Managing treatment for the orthodontic patient with periodontal problems. Semin Orthod 1997;3:21-38.
13. Feng X, Oba T, Oba Y, Moriyama K. An Interdisciplinary Approach for Improved Functional and Esthetic Results in a periodontally compromised adult patient. Angle Orthod 2005;75:1061-1070
14. Passanezi E, Janson M, Janson G, Sant'Anna AP, de Freitas MR, Henriques JF. Interdisciplinary treatment of localized juvenile periodontitis: a new perspective to an old problem. Am J Orthod Dentofacial Orthop. 2007;131:268-276