

## CASE REPORT

# Prosthetic Rehabilitation of A Cranial Defect: A Case Report

Godwin Clovis Da Costa,<sup>1</sup> Meena Aras,<sup>2</sup> Vidya Chitre,<sup>3</sup> Kennedy Mascarenhas<sup>4</sup>

## ABSTRACT

**Introduction:** Cranioplasty is the surgical intervention to correct a surgical defect. Cranial alloplastic implant materials used include metal, acrylic resin, polyethylene, and silicone. As an ever increasing number of expensive biomaterials for bone replacement have become available PMMA remains a cheap and readily available option that is potentially under used.

**Case report:** This case report describes the rehabilitation of a 25 year old male with a cranial defect using heat cure polymethacrylate resin. The acrylic implant was fabricated by the department of prosthodontics and placement was carried out by the department of neurosurgery.

**Conclusion:** Heat cure PMMA remains a cost-effective alloplastic material to repair cranial defects that fulfills the goals of cranial reconstruction.

**Key words:** Cranioplasty; Acrylic; PMMA; Cranial defect

**How to cite this article:** Godwin Clovis Da Costa, Meena Aras, Vidya Chitre, Kennedy Mascarenhas. Prosthetic rehabilitation of a cranial defect : A case report. Int J Cont Med Res. 2015;2(1):128-131

<sup>1</sup>Postgraduate student, <sup>2</sup>Professor and Head, <sup>3</sup>Associate Professor, <sup>4</sup>Lecturer, Department of Prosthodontics, Government Dental College and Hospital, Bambolim, Goa, India

**Corresponding author:** Dr. Godwin Clovis Da Costa, Postgraduate student, Department of Prosthodontics, Government Dental College and Hospital, Bambolim, Goa, India

**Source of Support:** Nil

**Conflict of Interest:** None

## INTRODUCTION

Cranioplasty is the surgical intervention to repair cranial defects. Many different types of materials

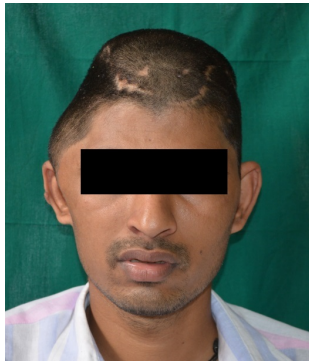were used throughout the history of cranioplasty, however judicious use of these materials is the key to success. This case report illustrates the neuro prosthetic rehabilitation of a 25 year old male patient with cranial defects involving the frontal, temporal and parietal bones. It provides an evidence based approach to implant material selection and fabrication, leading to aesthetic and functional success.

## CASE REPORT

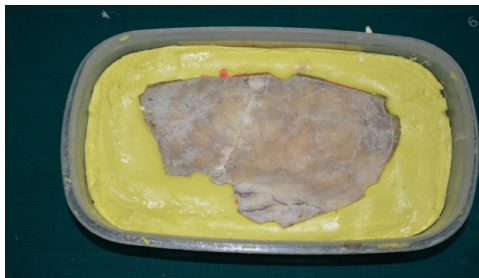
A 25 year old male patient reported to the department of prosthodontics with a history of trauma from a road traffic accident six months prior, following which he underwent a craniectomy procedure. The craniectomy led to a defect in the form of a depression measuring 7.5 x 6 inches (Fig1).

The patient had no other relevant medical history as on the day he reported, he was well oriented in time and space. It was decided to rehabilitate the patient using heat cure PMMA cranial prosthesis. Since the patient reported with the bone fragment it was decided to replicate the outer contour using irreversible hydrocolloid (Zelgan dust free Alginate Dentsply) (fig 2). Modelling Wax (Modelling Wax No 2 Hindustan Dental Products) was poured into the impression and a pattern 3-4 mm thick was fabricated. It was important to fabricate the plate marginally larger than the defect so that the prosthesis would not dip into the defect and lead to an unacceptable contour (fig 3). The wax pattern was then invested, dewaxed and acrylised at 168<sup>o</sup>F for 12 hours. The PMMA implant was retrieved finished and polished. Perforations were made using a 2mm round bur. The prosthesis was tried on the patient for accuracy of fit and contour. Gutta percha radiographic markers were embedded into the prosthesis (fig 4). It was then sterilised in 2% glutaraldehyde for 48 hours. The PMMA

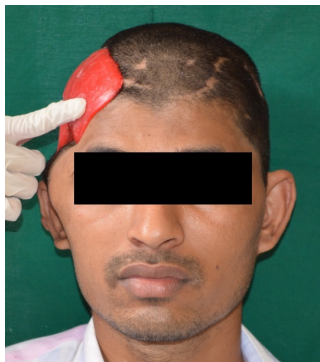implants were then placed by the department of neurosurgery under general anaesthesia after raising the flap of the scalp. The implants were stabilised with the help of non-absorbable suture material (Fig5). Follow up was done at 72 hours, 1 week, 3 months and yearly basis.



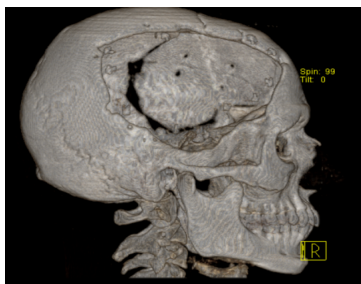**Fig-1:** Preoperative frontal view



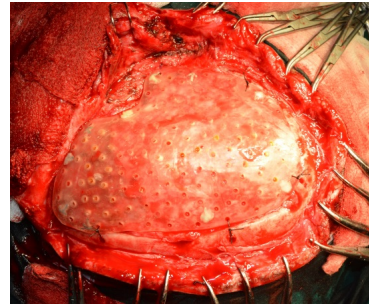
**Fig-2:** Duplication of the external contour in alginate



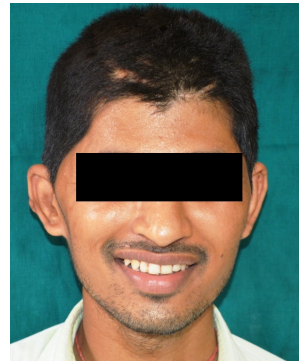**Fig-3:** Trial of wax pattern



**Fig-4:** Post-operative CT scan with radiographic markers



**Fig-5:** Surgical placement of the acrylic implant



**Fig-6:** Post-operative frontal view

**DISCUSSION**

Cranioplasty is the surgical intervention to cosmetically and functionally restore cranial defects. The aim of cranioplasty is not only a cosmetic issue; also, the repair of cranial defects gives relief to psychological drawbacks and increases the social performances<sup>1</sup>. Cranioplasty in this case was done to rehabilitate a cranial defect following trauma, which accounts for 64% of all cases.<sup>2</sup> Other indications for cranioplasty include tumour removal or decompressive craniectomies. Growing skull fractures and congenital anomalies are common causes in children younger than 3 years.<sup>3</sup> Hydrocephalus, infection, and brain swelling are known contraindications for cranioplasty, there was no sign of residual infection in our case or any other systemic involvement. Preoperative routine blood and radiographic investigations were carried out prior to the surgery.

An ideal cranioplasty material must fit the cranial defect and achieve complete closure. It should be radiolucent, resistant to infections, not dilate with heat, withstand biomechanical processes, easy to shape, inexpensive and ready to use.<sup>4</sup> Autografts from the cranium, tibia, ribs, scapula, fascia, sternum and ilium have been tried in the past with

little success. Autogenous bone is usually preferred over alloplastic material, although, even cranial bone graft may be unpredictable and the potential donor site morbidity is a disadvantage.<sup>5</sup> Moreover cranial contour cannot be obtained easily with tibia grafts while grafts obtained from the sternum and ileum, undergo resorption more often.<sup>6</sup>

Previously metal allografts used included aluminium, gold, silver, tantalum, stainless steel, titanium, lead, platinum and vitallium however heat conduction, difficulty to shape, and radiopacity limited their use as a suitable cranioplasty material. More recently, titanium meshes were used as a support to cement materials. In this way, the strong resistance against mechanical stress of the titanium and the ability to remodelling of the cement materials were combined. The titanium meshes showed good resistance to infection, even when in contact with the paranasal sinuses but is not a good option in cases with bad skin viability like multiple operations and radiotherapy.<sup>7</sup>

Non-metal allografts include Celluloids, Methylmethacrylate, Hydroxyapatite, Polyethylene, Silicon, Chorale, Ceramic and Cortoss™. Celluloids resulted in postoperative fluid collection.<sup>8</sup> The advantages of hydroxyapatite include minimal tissue reaction, increased bone repair, and good osteointegration. The main disadvantage is that this material is not very resistant to mechanical stress hence can easily break.<sup>9</sup> Silicon has been discontinued due to its soft built while chorale and ceramics lacked durability. Cortoss™ was not used due to the financial shortcomings of the patient.

Heat cured Poly Methyl Methacrylate (PMMA) was the material of choice for the implant fabrication, since it is easy to shape, lighter in weight, poor conductor of heat and radiolucent. The heat cured PMMA implant was fixed to the adjacent bone with the help of resorbable suture material which provided initial primary stability. The perforations created in the prosthesis also helped in retention. Animal experiments have revealed that acrylic adheres to the dura mater with no reaction to other underlying layers.<sup>10</sup>

A major disadvantage of using PMMA includes heat generation during its setting reaction which could cause harm to the underlying tissues and

traces of residual monomer found have been reported to be carcinogenic.<sup>11</sup> The former was addressed by adopting heat cured PMMA implants which were fabricated by an indirect approach which also helped achieve proper contour and a smoother finish. The residual monomer content in the polymerised resin could be decreased by the use of water-bath and microwave post-polymerisation.<sup>13,-15</sup> The problem of residual monomer in the heat cured PMMA in this case was addressed by immersing it in water for 48 hours. Due to the radiolucency of the implant, post-operative evaluation is limited however the gutta percha radiographic markers incorporated into the prosthesis allowed us to overcome this limitation of the prosthesis.

## CONCLUSION

Among the many materials used for cranioplasty,<sup>14</sup> bone cement has shown substantially higher rates of infection and complication. Titanium-based implants may obscure follow-up imaging for tumor patients. Heat cured PMMA implants remain a cost-effective and proven method to repair cranial defects that fulfills the goals of reconstruction for cranial defects.

## REFERENCES

1. Seckin Aydin, Baris Kucukyuruk, Bashar Abuzayed, Sabri Aydin, and Galip Zihni Sanus. Cranioplasty: Review of materials and techniques. *J Neurosci Rural Pract.* 2011; 2: 162-167.
2. Jaberi J, Gambrell K, Tiwana P, Madden C and Finn R. Long-term clinical outcome analysis of poly-methyl-methacrylate cranioplasty for large skull defects. *J Oral Maxillofac Surg.* 2013; 71: 81-88.
3. Rish BL, Dillon JD, Meirrowsky AM, Caveness WF, Mohr JP, Kistler J and, Weiss GH. Cranioplasty: a review of 1030 cases of penetrating head injury. *Neurosurgery.* 1979; 4:381-385.
4. Blake DP. The use of synthetics in cranioplasty: a clinical review. *Mil Med.* 1994; 159: 466-46.
5. Viterbo F, Palhares A and Modenese E J. Cranioplasty: the autograft option. *J Craniofac Surg.* 1995; 6: 80-83.
6. Rosenthal AH and Buchman SR. Volume

- maintenance of inlay bone grafts in the craniofacial skeleton. *Plast Reconstr Surg.* 2003; 112: 802-811.
7. Kuttenger JJ and Hardt N J. Long-term results following reconstruction of craniofacial defects with titanium micro-mesh systems. *Craniofac Surg.* 2001; 29:75-81.
  8. Blake DP. The use of synthetics in cranioplasty: a clinical review. *Mil Med.* 1994; 159: 466-469.
  9. Gosain AK. Hydroxyapatite cement paste cranioplasty for the treatment of temporal hollowing after cranial vault remodeling in a growing child. *J Craniofac Surg.* 1997; 8: 506-511.
  10. Drosos GI, Babourda E, Magnissalis EA, Giatromanolaki A, Kazakos K and Verettas DA. Mechanical characterization of bone graft substitute ceramic cements. *Injury.* 2012; 43: 266-271.
  11. Keyf, F, Keyf A. Harmful effects of methyl methacrylate and Formaldehyde from acrylic resin denture base materials. *The Saudi Dental Journal.* 1999;10:23-9.
  12. Jorge H et al. Biocompatibility of denture base acrylic resins. *Gerontology* 2007;24: 52–57.
  13. Ruyter IE. Release of formaldehyde from denture base polymers. *Acta Odontol Scand* 1980; 38: 17–27.
  14. Jaber J, Gambrell K, Tiwana P, Madden C, Finn R. Long-term clinical outcome analysis of poly-methyl-methacrylate cranioplasty for large skull defects. *J Oral Maxillofac Surg.* 2013;71:81-8.
  15. Megalaa N, Kayalvizhi G, Silas AJ, Sajeev R, Saravana Kumar MS. Role of herbal leaf extracts in caries prevention. *Int J Cont Med Res.* 2014;1(2):71-78