

CASE REPORT

Ultrasonographic Evaluation of Ameloblastoma -A Case Series

Aditi R¹, Rupesh Mandava², Sathasivasubramanian S³, Malarkodi T⁴

ABSTRACT

Introduction: Ultrasonography forms an important diagnostic aid in the evaluation of soft tissue pathologies in the head and neck region. It provides real-time images and does not require contrast media. It is non-invasive, economic, and easily available without exposure to ionising radiation. However, it is rarely used for assessment of bone pathologies as bone forms an obstacle for ultrasonographic evaluation.

Case report: Two cases of ameloblastoma were investigated clinically, ultrasonographically and radiologically. This paper demonstrates ultrasonographic findings in benign and malignant cases of ameloblastoma.

Conclusion: US may be used for evaluating the cystic lesions of the mandible and with more utility and imaging precision the use of cross-sectional imaging modalities like CT could be decreased; thus reducing the radiation and health care costs significantly.

Keywords: Ultrasonographic evaluation, ameloblastoma, ameloblastic carcinoma, odontogenic tumors

How to cite this article: Aditi R, Rupesh Mandava, Sathasivasubramanian S, Malarkodi T. Ultrasonographic evaluation of ameloblastoma -a case series. International Journal of Contemporary Medical Research 2015;2(4):865-869

¹Former Postgraduate, ³Professor and Head, ⁴Senior Lecturer, Department of Oral Medicine and Radiology, ²Assistant Professor, Department of Radiology, Sri Ramachandra University, Chennai, Tamil Nadu, India

Corresponding author: Aditi R, M.D.S., Former Postgraduate, Department of Oral Medicine and Radiology, Sri Ramachandra University, Chennai, Tamil Nadu, India.

Source of Support: Nil

Conflict of Interest: None

INTRODUCTION

Ultrasonography is an important imaging modality for the evaluation of soft tissue lesions and pathologies in the oral and maxillofacial region. It is non-invasive, easily available, economic and reproducible without

exposure to ionising radiation or the use of contrast media. It is usually considered that its application in bone lesions is highly restricted due to the reflection of the sonographic waves by the bone. But considering the mandibular cystic and solid tumours, a liquid content may exist within the lesion which may compress the mandibular bone and lead to a thinning of the cortical plate causing sonographic waves to pass through the thinned cortical bone thus enabling the lesion to be evaluated.^{1,2}

This paper demonstrates the initial evaluation of two cases of benign and malignant ameloblastoma and its differentiation with the use of Ultrasonography and correlating the US findings with the CT findings.

CASE REPORTS

GE Ultrasound machine LOGIQ P6 using a high resolution transducer the images were acquired in B-mode, with the use of Colour Doppler to see for vascularity.

Case 1

A 60 year old male patient, reported to the Department of the Oral Medicine and Radiology, SRU with a chief complaint of a swelling in the lower half of the face on the left side for the past 3 years. He had no history of pain, weight loss or trauma.

On extra oral examination (Fig 1), a single, diffuse swelling was evident beneath the lower lip towards the left side of the lower 1/3rd of the face. Skin over the swelling appeared normal in colour with a smooth surface. On palpation, it measured about 4 x 3cm in dimension, extending anteriorly 1 cm to the right of the midline, posteriorly to the inferior border of the mandible, superiorly 1cm below the lip and inferiorly involves the lower border of the mandible. It was hard in consistency, non-tender and fixed. Skin over the swelling was pinchable without any pulsations.

On intraoral examination, a single well-defined swelling was evident in the alveolar mucosa involving the edentulous region of 41-34 measuring approximately 2.5 x 1.5 cm. On the right side it extended upto the mesial aspect of 42, crossed the midline and extended onto the left side upto distal aspect of 35. Superiorly it involved the alveolar crest and onto the lingual side

an expansion with an obliteration of the lingual sulcus was noted. Inferiorly it obliterated the mucobuccal fold i.r.t edentulous region. Buccal and lingual cortical expansion was evident. On palpation, swelling was non-tender, labially bony hard in consistency and firm lingually.

An Orthopantomogram (Fig 3) revealed a single well-defined multilocular radiolucency in relation to the edentulous region extending from the mesial aspect of 43 to distal aspect of 35 with well corticated lateral and inferior margins, superior margin is ill defined with no cortication. The internal structure demonstrated a honey comb pattern.

The Extraoral ultrasound image revealed a cystic lesion of size of 3.1 x 1.8 cms noted arising from the mentum and the body of the mandible on the left side causing expansion of the mandibular bone in this region. There was a breach in the cortex with no evidence of calcification.

On Intraoral ultrasound no evidence of internal vascularity was seen and a small soft tissue component was seen to be projecting into the oral cavity below the tongue. No evidence of calcifications within. Minimal vascularity is seen within the lesion. Thus an expansile lesion with predominantly cystic component having a small soft tissue component causing expansion of the mandible in the region of the mentum was seen- features were in favour of adamantinoma (Fig 4).

On CT Scan of the supraorbital region to neck- (Plain and contrast), (Fig 5) An expansile lytic lesion of size 3.2 x 2.2 x 3.8 cms (Trans x AP x CC) was noted arising from the mentum and the body of the mandible on the left side. There was a breach in the cortex with erosion into the adjacent tooth roots. Small adjacent surrounding soft tissue component is seen which was seen to show minimal enhancement on contrast administration. Features were in favor of Ameloblastoma with no evidence of malignant change. The lesion was surgically resected and a histopathological confirmation to the hypothesis was established.

Case 2

A 60 year old male patient, reported to the Department of the Oral Medicine and Radiology, SRU with a chief complaint of a swelling in the left lower jaw for the past 1 year. Patient gave similar history of a swelling in the same site 4 years back for which he had undergone surgery and after which the swelling subsided.

On extra oral examination (Fig 6) A single, well defined, swelling evident in the left lower 1/3rd of the face roughly measuring about 5x5cm in dimension spheri-

cal in shape. Surface of the swelling was smooth.

On Palpation, swelling was soft in consistency superiorly, inferiorly the complete submandibular region was hard in consistency, non-tender, compressible superiorly and non-compressible inferiorly and non-reducible. Loss of sensation was evident over the swelling and below the lip on the left side on cotton wisp test.

On intraoral examination (Fig 7), a single, well defined swelling was evident in the alveolar mucosa of edentulous 36-38 region roughly measuring about 4.5 x 4.5 cm in dimension. On the superior aspect a single well defined growth was evident over the crest of the ridge of 36, 37 region. The growth was sessile, measured approximately 2cm x 2cm in size over the alveolar mucosa with an irregular surface. An intraoral sinus opening about 0.5 cm in size was evident in the left pterygomandibular raphe area with straw colored slow discharge mixed with blood. On palpation, it was non-tender, hard in consistency, Buccal and lingual cortical expansion was evident. Straw colored discharge mixed with blood was evident from the sinus opening on palpation of the swelling. A working diagnosis of recurrent ameloblastoma was given.

An Orthopantomogram (Fig 8) revealed, a well-defined radiolucency evident in the left body of the mandible with a well corticated scalloped border, extending from the distal surface of 32 upto the left sigmoid notch, with a loss of superior border of the mandible, and 0.5 cm short of the inferior cortex with bowing near the angle of the mandible. Margins were scalloped internally and irregularity of margins was evident towards the ramus of the mandible. A complete loss of lamina dura around 33, 34, 35 with superior tipping of 34, 35 was seen. The internal structure is completely radiolucent.

On ultrasonography (Fig 9), a soft tissue lesion of size 5.1 x 3.3 x 4.9 cms was noted in the region of the ramus of the left mandible causing expansion of the bone with cortical destruction having a cystic component measuring about 3.8 x 2.9 cm. the left mandibular condyle is seen to be normal. Significant vascularity was seen in the soft tissue component with evidence of bizarre pattern and multiple small vessels seen similar to neovascularity in malignant lesions. No evidence of calcifications are seen -- Features were in favour of a malignant lesion in the mandible with possibility of recurrent malignant ameloblastoma.

A CT Scan of supraorbital region to neck- (Plain and contrast) (Fig 10) revealed A large soft tissue density lesion measuring about 8.3 x 5.3cm was seen in the region of the ramus of the left mandible causing expansion of the bone with cortical destruction having a cyst-

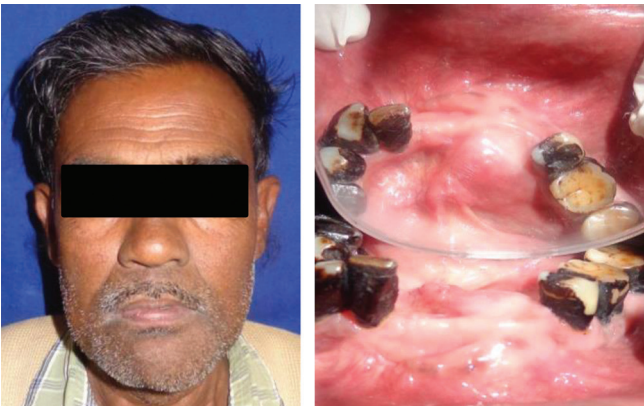

Figure-1: Extraoral; Figure-2: Intraoral

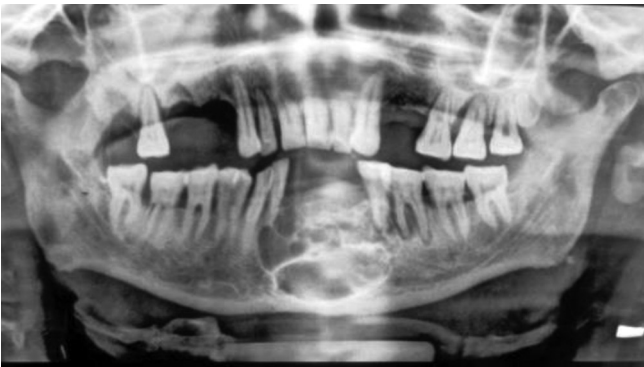

Figure-3: Orthopantomogram

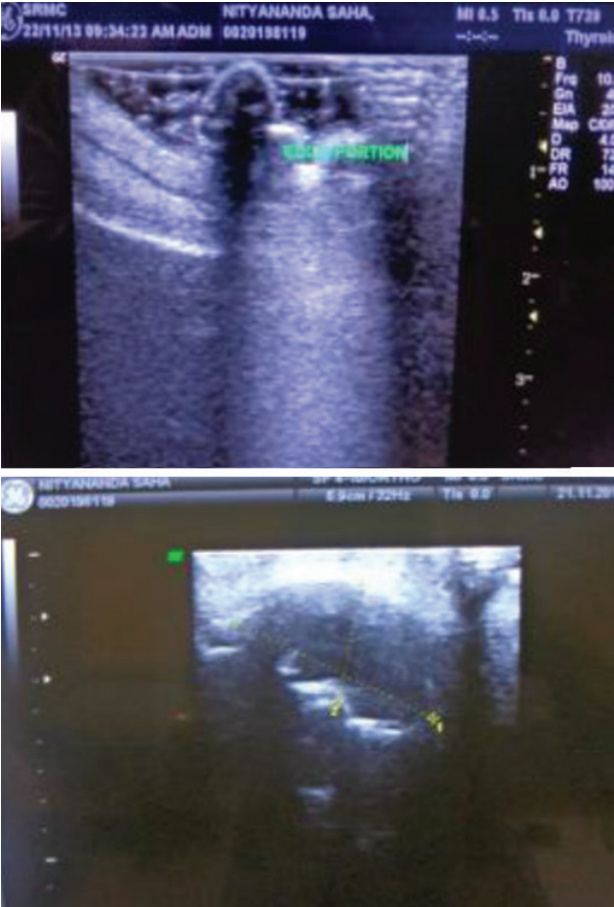
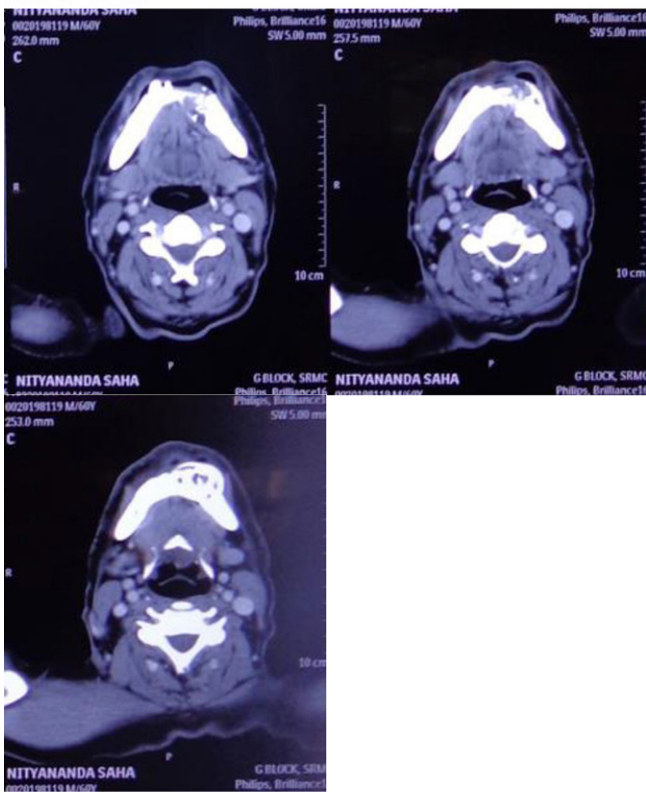


Figure-4: Ultrasonography

AXIAL VIEW



3D RECONSTRUCTION

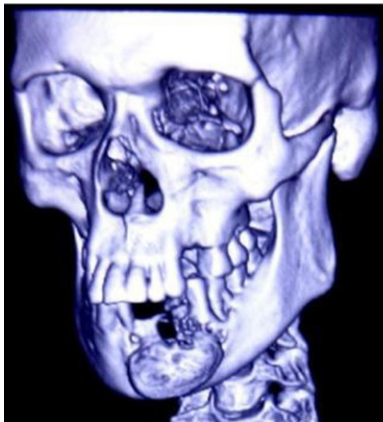

Figure-5: CT Scan with contrast

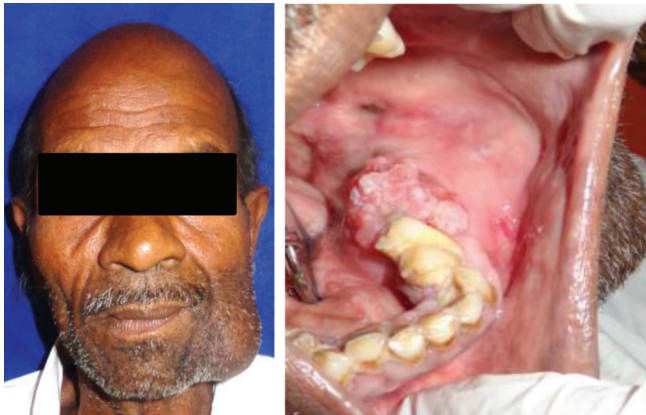

Figure-6: Extraoral; Figure-7: Intraoral

ic component measuring about 3.6 x 2.1cm. The lesion was seen to show heterogenous intense enhancement on contrast administration with evidence of displacement of the left lateral margin of the tongue medially, with no obvious evidence of invasion. Subcentimeter lymphnodes were seen in the submental and left submandibular locations. Features were suggestive of re-

currence of malignant ameloblastoma. The lesion and was surgically resected and a histo-

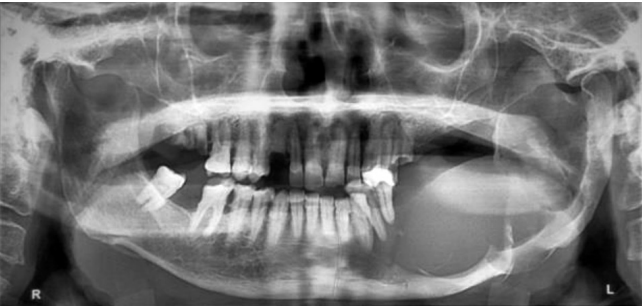
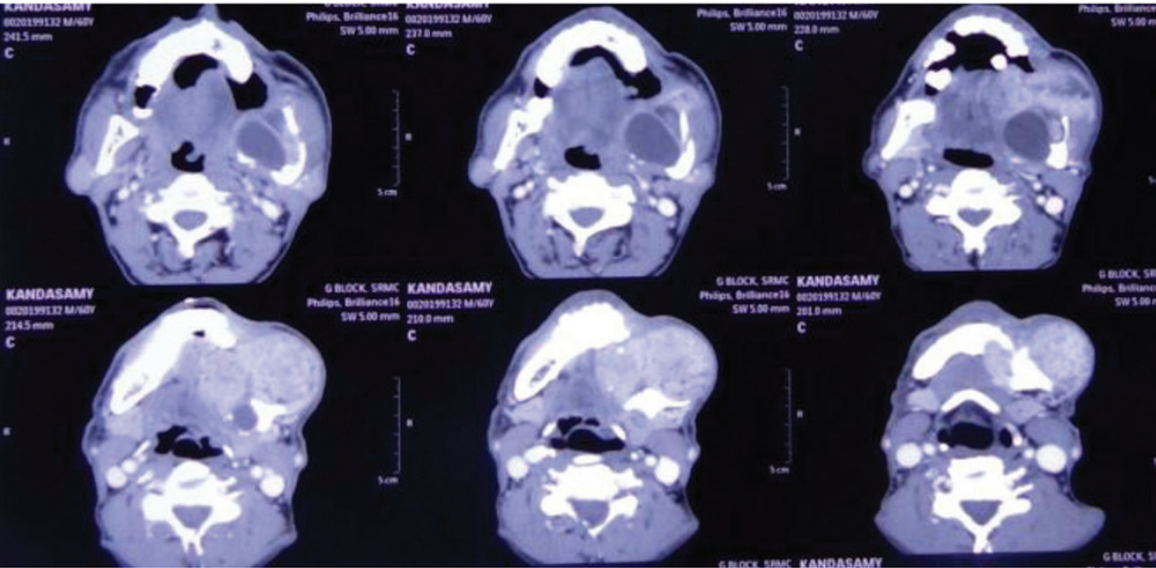


Figure-8: Orthopantomogram

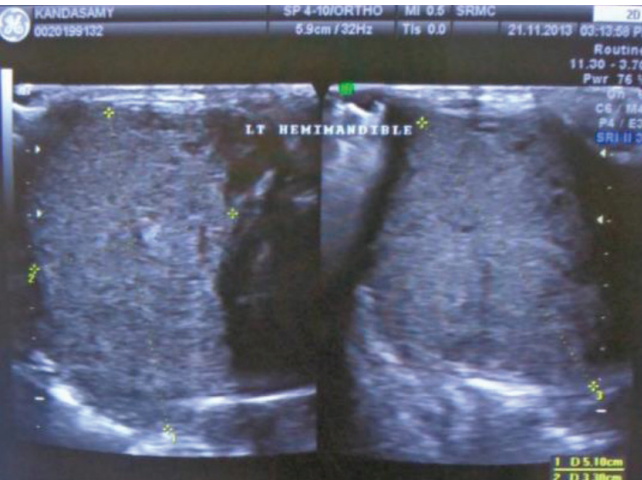

Figure-9: Ultrasonography

AXIAL VIEW



3D RECONSTRUCTION

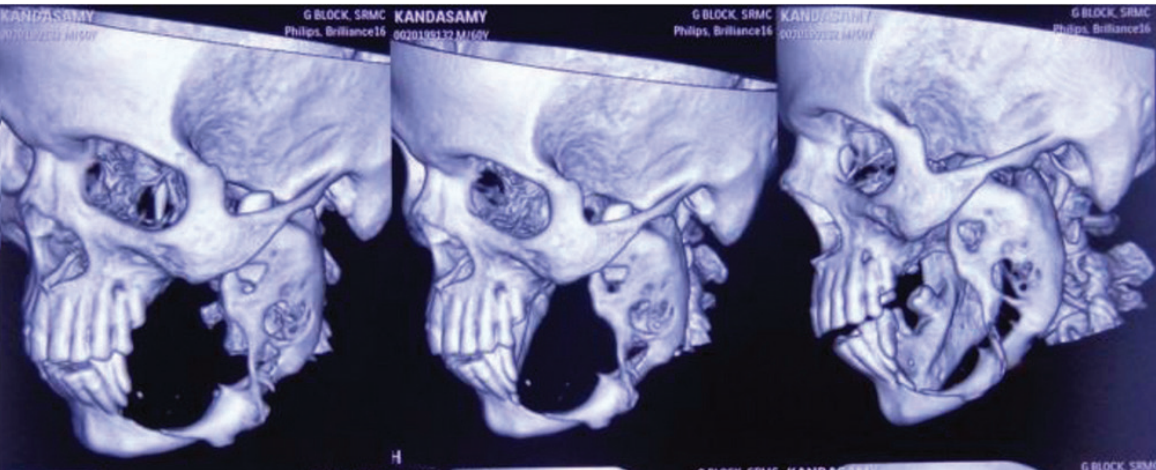


Figure-10: CT Scan with contrast

pathological confirmation was established was ameloblastic carcinoma.

DISCUSSION

In the first case the cystic component with small soft tissue component, breach in the cortex could be seen with ultrasound and were confirmed with CT. In the second case the increased vascularity, neovascularity, cystic and soft tissue components of the lesion and the cortical destruction could be noted clearly both suggesting a malignant etiology of the ameloblastic carcinoma.

Ultrasonographic imaging of the hard tissue (bone) mostly depicts the surface and contour of the bone and is of limited utility in visualising the internal structures. The application of ultrasound to the bone lesions has not attracted clinical attention before due to its inability to depict the internal structure of the bone as the ultrasound waves within the diagnostic frequency range are reflected by the normal bony surfaces. However, when there is a pathology which causes thinning of the cortical bone ultrasound becomes a useful tool for evaluation.³

Ameloblastoma is a true neoplasm of odontogenic epithelial origin. It is the second most common odontogenic neoplasm, and only odontoma outnumbers it in reported frequency of occurrence. Its incidence, combined with its clinical behavior which makes ameloblastoma the most significant odontogenic neoplasm.⁴ Ameloblastic carcinoma is most commonly found in the mandible (as in the presently reported case), where it involves the posterior portion more frequently than the anterior.⁵ Ameloblastic carcinoma is a rare malignant odontogenic tumor that can develop de novo (primary type) or by malignant transformation of an intraosseous or peripheral ameloblastoma (secondary type).⁶

Lu et al conducted a study that included nineteen subjects to demonstrate ultrasonographic characteristics of mandibular ameloblastoma and to assess the value of ultrasonography in diagnosis of the tumor and concluded that Ultrasonography can be used as an effective supplementary diagnostic method for mandibular ameloblastomas.² In cases of small intrabony lesions, this technique is not indicated, because ultrasonic waves cannot penetrate thick bone walls. In a patient with a swelling in the jaw, the first step in diagnosis is panoramic radiography. However, if the swelling is hard and fixed to adjacent tissues, CT is preferred³ but we chose to evaluate the lesion by ultrasonography to identify the utility of ultrasound in evaluation of these

lesions.

In all patients with cystic lesions in the mandible, US can be performed, as it allows us to identify the nature of the lesion, and to identify the ideal areas for execution of the biopsies.¹

CONCLUSION

Most of mandibular cystic lesions cause cortical expansion and consequent thinning, facilitating the passage of the ultrasonographic waves. The main advantage of US over simple orthopantomography is that US is a dynamic exam that allows to check the interior of the lesion, detecting areas of tissue proliferation, including biopsy areas. Bone cortices thinner than 1 mm may allow the passage of the ultrasonographic signal. The color Doppler flow imaging system was also used to assess the vascularity of the lesions.

Thus, US may be used for evaluating the cystic lesions of the mandible and with more utility and imaging precision the use of cross-sectional imaging modalities like CT could be decreased; thus reducing the radiation and health care costs significantly.

REFERENCES:

1. Shinohara EH, Kaba SP, Martini MZ, Hueb CH. Ultrasonographic evaluation of intramandibular ameloblastoma Indian Journal of Dental Research 2013;24:7-9
2. Lu L, Yang J, Liu JB, Yu Q, Xu Q. Ultrasonographic evaluation of mandibular ameloblastoma: A preliminary observation. Oral Surg Oral Med Oral Pathol Oral Radiol Endod 2009;108:e32-8
3. Gümüş S, Hoşgören B. Clinical and radiologic behaviour of ameloblastoma in 4 cases. J Can Dent Assoc. 2005;71:481-4.
4. Ramesh RS, Manjunath S, Ustad TH, Pais S, Shivakumar K. Unicystic ameloblastoma of the mandible: An unusual case report and review of literature. Head Neck Oncol. 2010;2:1-5.
5. Suomalainen A, Hietanen J, Robinson S, Peltola JS. Ameloblastic carcinoma of the mandible resembling odontogenic cyst in a panoramic radiograph. Oral Surg Oral Med Oral Pathol Oral Radiol Endod 2006;101:638-642
6. Sozzi, Davide, et al. Ameloblastic carcinoma in a young patient. Oral surgery, oral medicine, oral pathology and oral radiology 2014;117.5:e396-e402
7. Shinohara EH, Horikawa F. Cysts: Liquid content. Br Dent J 2005;199:587