

Thigh Hematoma Following Oral Anticoagulant Therapy: A Case Report

Sameeraja Vaddera¹, Lubna Shafi², Ramesh G Reddy³, Sreevani Gayatri⁴, N.Vijay Krishna⁵

ABSTRACT

Introduction: The major complication of oral anticoagulant therapy is bleeding. Acitrom (acenocoumarol), an oral anticoagulant is similar to warfarin but with longer half-life and lesser interactions. Management of warfarin-induced major bleeding in patients with mechanical heart valves is challenging.

Case report: We describe a case of thigh hematoma in a patient with chronic rheumatic heart disease in atrial fibrillation who had mitral valve replacement. Patient was on oral anticoagulant since 18yrs and underwent coronary angiogram 2 months back. Diagnosed as acitrom induced coagulopathy and was confirmed by computed tomography and prothrombin time.

Conclusion: Mechanical heart valve patients who are receiving stable dose of oral anticoagulants, should be monitored at regular intervals of 4 weeks and also should not neglect any non healing injuries. The major complication of oral anticoagulant therapy is bleeding. Management of warfarin-induced major bleeding in patients with mechanical heart valves is challenging. Proper education and early recognition of symptoms will prevent major complications. To the best of our knowledge, this is the first reported case of intramuscular hematoma of medial compartment of thigh due to acitrom following coronary angiogram through femoral approach.

Key Words: Oral anticoagulants, post mitral valve replacement, hematoma, intramuscular

INTRODUCTION

A large number of 4-hydroxycoumarins, with aromatic substituent at the 30 position, possess anticoagulant properties and collectively called coumarinic oral-anticoagulants (COAs). The commercially available coumarins include warfarin, acitrom, acenocoumarol and phenprocoumon. In India, acitrom is the popular drug of choice for oral anticoagulant therapy with many indications. In the western world, warfarin is given as oral anticoagulant. Both acitrom and warfarin belong to the same class of acenocoumarol drugs and exist in R- and S- enantiomeric forms.¹ To achieve and maintain an optimal warfarin dose, the prothrombin time and the international normalized ratio (INR) are monitored and doses are adjusted accordingly. An INR of less than 2 is associated with an increased risk of thromboembolism and an INR of 4 or more is associated with an increased risk of bleeding.² Warfarin therapy develop major bleeding complications due to a narrow therapeutic index, an unpredictable biological response (including genetic polymorphisms in warfarin metabolism) and multiple interactions with concomitant drugs, food and

other patient-related factors. For patients who are receiving a stable dose of oral anticoagulants, monitoring at an interval no longer than 4 weeks is suggested.³

CASE REPORT

A 65year old female patient came to emergency department with complaints of swelling of right lower limb since 5days associated with severe pain and inability to move since 3days. She had spotting through vagina since 3days. She underwent mitral valve replacement 18 years back for chronic rheumatic heart disease and was on Acitrom (acenocoumarol) 5mg. 2months back she underwent angiogram through right femoral approach for coronary artery disease. Since then she was on Acitrom (acenocoumarol) 2.5mg as she had mild bleeding after angiogram.

On examination, the patient was conscious, coherent with pale mucous membranes. Blood pressure was 130/80 mmHg, heart rate was 100 beats per min which was irregularly irregular. On inspection, swelling of right lower limb with signs of inflammation was seen. A large ecchymosis was seen on antero-medial side of right thigh [Figure 1] with intact peripheral pulses. Cardiac auscultation revealed irregular heart rate and rhythm and a late systolic murmur heard all over the precordial area. Abdominal examination was unremarkable. Neurological examination revealed right crural monoparesis with power of grade 1/5, symmetric reflexes and normal plantar response in both legs.

Investigations revealed hemoglobin of 5.8gm/dl, platelet count was 1.5lakh/cumm, wbc count-8,600, prothrombin time was raised and INR was 10.4. Patient was advised to stop acitrom and a high dose of vitamin K (10mg) was given. 3 units of FFP (Fresh Frozen Plasma), 1 unit packed cells were transfused. Her ECG revealed atrial fibrillation with fixed ventricular rate. Doppler of right lower limb suggested hematoma in antero-medial side of thigh in intramuscular plane of 4cms*3cms size. Computed Tomography (CT) of right thigh showed bulky muscles with patchy increase in density of 70 Hounsfield units (H.U) suggestive of hematoma in the medial compartment of thigh with size 3.7cms*3.1cms[Figure 2&3].

¹Assistant Professor, ²⁻⁴Junior Resident, Department of General Medicine, MNR Medical College, Telangana, India

Corresponding author: Dr. Sameeraja Vaddera, Assistant Professor, Department of General Medicine, MNR Medical College, Telangana, India

How to cite this article: Sameeraja Vaddera, Lubna Shafi, Ramesh G Reddy, Sreevani Gayatri, N. Vijay Krishna. Thigh hematoma following oral anticoagulant therapy: A case report. International Journal of Contemporary Medical Research 2016;3(2):390-392.

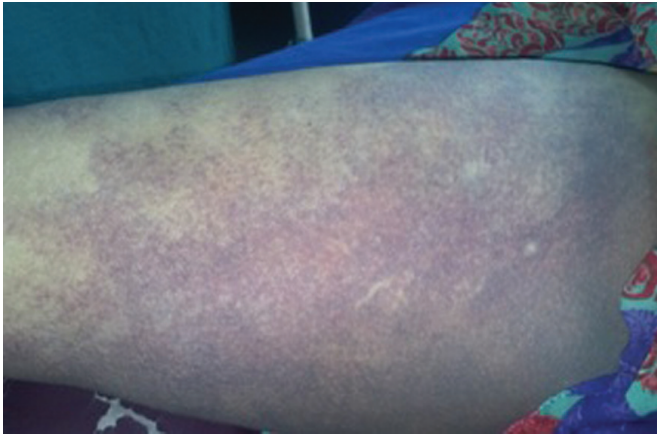

Figure-1: A large ecchymosis was seen on antero-medial side of right thigh

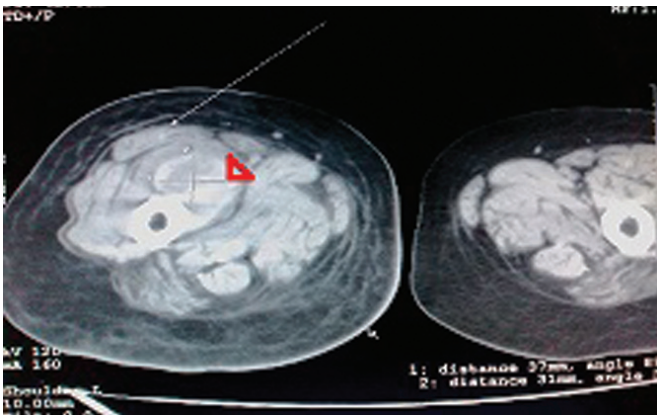


Figure-2: CT scan of right thigh showing bulky muscles with hematoma

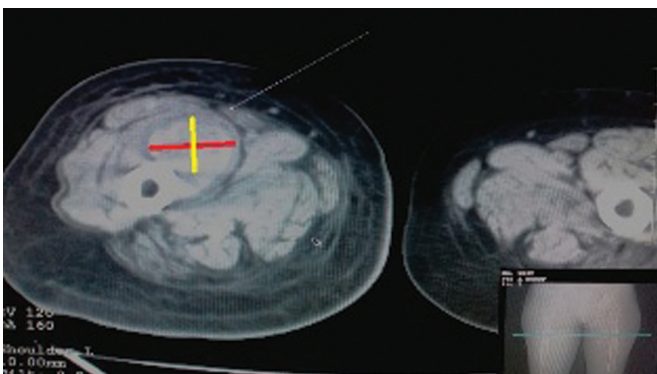


Figure-3: Hematoma in the medial compartment of thigh

2D Echo revealed atrial fibrillation with normal functioning prosthesis without any vegetations. Patient was started on antibiotics, anti-inflammatory drugs. Second dose of Vitamin K was given after 12hrs following which patient improved symptomatically. Repeat PT, INR was sent everyday. On 2nd day INR was 3.5. Swelling started decreasing in size and within a week her weakness was also improved to grade 4/5. Acitrom (acenocoumarol) 1mg started after INR came down to 2. Patient is under regular follow-up. She had no further episodes of bleeding and her INR was maintained between 2-2.5.

DISCUSSION

Bleeding and hemorrhage account for 10% adverse effects of anticoagulation treatment and are potential and severe complications.⁴ The International Society on Thrombosis and Hemostasis in 2005, defined major bleeding in non-surgical patients as: (1) fatal bleeding; and/or (2) symptomatic bleeding in a critical area or organ, such as intracranial, intraspinal, intraocular, retroperitoneal, intra-articular or pericardial, or intramuscular (iliopsoas) with compartment syndrome; and/or (3) bleeding causing a fall in hemoglobin level of 2 gm% or more, or leading to transfusion of two or more units of whole blood or red cells.⁵ Ansell et al., 2001 have grouped hemorrhages into major and minor. Major risk of hemorrhages during oral anticoagulation treatment as reported to be around 1-7.4% in cohort studies (Wiedermann and Stockner, 2008).

The severity of the bleed is often also dependent on the location of the bleed. The common sites of major bleeding related to warfarin are the gastrointestinal tract (40%-60%) and urinary tract (15%) followed by ICH/subdural hematoma and retroperitoneal bleed/abdominal compartment syndrome. The mortality due to major bleeding is 9.5%.⁶

Bleeding is treated differently according to the severity of the bleed. The treatment of bleeding is also determined by the International Normalised Ratio (INR) of the patient. There are mainly three ways of treating a bleed: 1. Discontinue the use of the vitamin K antagonist 2. Administer oral or intravenous vitamin K 3. Substitute clotting factors, which include fresh frozen plasma (FFP), prothrombin complex concentrates (PCC) or recombinant activated factor VII (rFVIIa).⁷

In patients with mechanical heart valves and major bleeding, ACC/AHA guidelines should be followed by using FFP and vitamin K intravenous injection.⁸ Both PCC and recombinant FVIIa potentially produce thrombotic complications which may restrict their use in mechanical heart valves as there is a chance of valve thrombosis which can be fatal. In view of this, our patient was treated with fresh frozen plasma and high dose of Vitamin K though she had major bleeding which could be fatal. Though the patient was on therapeutic dose of anticoagulation, she developed hemorrhage. This may be due to non healing of intervention site of angiogram and it gave a way to form hematoma when there is no other evidence of any internal or external hemorrhage.

CONCLUSION

Acenocoumarol/Nicoumalone (Acitrom) Acitrom an oral anti-coagulant is similar to warfarin but with longer half-life and lesser interactions. It is available as 1, 2 and 4 mg tablets. There are as many as 40 adverse effects of warfarin among which bleeding is commonest and most dreadful if not treated promptly. To the best of our knowledge, this is the first reported case of intramuscular hematoma of medial compartment of thigh due to acitrom following coronary angiogram through femoral approach. Excessive bleeding, or hemorrhage, can occur from any area of the body, and patients on warfarin should report any falls or accidents, as well as signs or symptoms of bleeding or unusual bruising.⁹

REFERENCES

1. Pharmacogenetic Aspects of Coumarinic Oral Anticoagulant therapies: *Ind J Clin Biochem* (July-Sept 2011) 26(3):222–229; DOI 10.1007/s12291-011-0133-3.
2. Levine MN, Raskob G, Landefeld S, Kearon C. Hemorrhagic complications of anticoagulant treatment. *Chest*. 2001;119(Suppl 1):108S-121S.
3. Pharmacology and Management of the Vitamin K Antagonists* American College of Chest Physicians Evidence-Based Clinical Practice Guidelines (8th Edition) Jack Ansell, MD; Jack Hirsh, MD; Elaine Hylek, MD, MPH; Alan Jacobson, MD; Mark Crowther, MD; and Gualtiero Palareti, MD: Antithrombotic and Thrombolytic Therapy 8th Ed: ACCP Guidelines.
4. Zago et al: Iliopsoas muscle hematoma and Warfarin :*Arq Bras Cardiol* 2010;94:e1-e3
5. Schulman S, Kearon C. Definition of major bleeding in clinical investigations of antihemostatic medicinal products in non-surgical patients. *J Thromb Haemost*. 2005;3:692-4.
6. Guerrouij M, Uppal CS, Alklabi A, Douketis JD. The clinical impact of bleeding during oral anticoagulant therapy: assessment of morbidity, mortality and post-bleed anticoagulant management. *J Thromb Thrombolysis*. 2011;31:419-23.
7. Oral anticoagulant therapy Ageno W, Gallus AS, Wittkowsky A, Crowther M, Hylek EM, Palareti G. *Chest*.2012;141(2-suppl):e44S-e88S. doi:10.1378/chest.11-2292.
8. Panduranga P, Al-Mukhaini M, Al-Muslahi M, Haque MA, Shehab A. Management dilemmas in patients with mechanical heart valves and warfarin-induced major bleeding. *World Journal of Cardiology*. 2012;4:54-9. doi:10.4330/wjc.v4.i3.54.
9. www.uptodate.com/contents/warfarin-coumadin-beyond-the-basics.

Source of Support: Nil; **Conflict of Interest:** None

Submitted: 14-12-2015; **Published online:** 04-01-2016