

## CASE REPORT

**Intra-Oral Vascular Malformation with Phleboliths**Jayam Raviraj<sup>1</sup>, Prashanthi S<sup>2</sup>, Dirasantchu Suresh<sup>3</sup>, Samiullashaik<sup>3</sup>**ABSTRACT**

**Introduction:** Vascular malformations of head and neck are a common entity. However, reports of vascular malformations of oral cavity associated with phleboliths are a rare phenomenon. Vascular malformations are congenital lesions which may or may not be clinically evident since birth. They have a tendency to grow along with the body growth of an individual. They are painless, bluish colored lesions, soft in consistency with nodular or racemose surface. The endothelial turnover is unaffected in vascular malformations in contrast to hemangiomas.

**Case report:** A 24 yr old female patient was diagnosed of vascular malformation of left buccal mucosa with radiographic evidence of phleboliths.

**Conclusion:** Vascular malformations should always be considered a differential diagnosis when presented clinically and radiologically similar to our case. This ensures minimal possibility of encountering fatal and uncontrolled bleeding complications.

**Keywords:** vascular malformations, hemangiomas, phlebolith, panoramic radiograph.

**How to cite this article:** Jayam Raviraj, Prashanthi S, Dirasantchu Suresh, Samiullashaik. Intra-oral vascular malformation with phleboliths. International Journal of Contemporary Medical Research 2015;2(4):822-823

<sup>1</sup>Professor, <sup>2</sup>Ex-Post Graduate Student, <sup>3</sup>Senior Lecturer, Department of Oral Medicine and Radiology, CKS Theja Institute of Dental Sciences & Research, Tirupati-A.P, India

**Corresponding author:** Dr. Jayam Raviraj, Flat No. 301, Brindavan Apartments, Above Karur Vysya Bank, K. T. Road, Tirupathi- 517501, Andhra Pradesh, India

**Source of Support:** Nil

**Conflict of Interest:** None

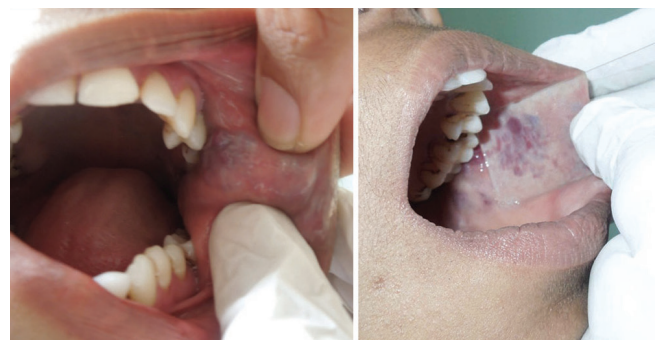**INTRODUCTION**

Vascular malformations are developmental abnormalities of vascular system. Long standing cases are known

to be associated with multiple calcification within these lesions which are termed phleboliths. We hereby report a case of intra-oral vascular malformation with phleboliths affecting left buccal mucosa.

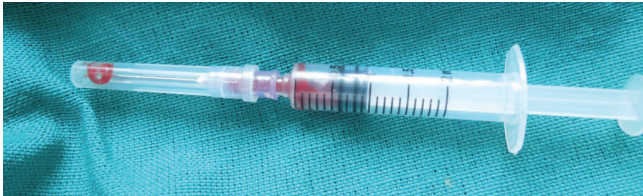**CASE REPORT**

A 24 year old female patient reported to the department with a chief complaint of painless swelling in her left inner cheek region since 20 yrs. Swelling gradually developed over a period of time and was not associated with any other significant changes. On extra-oral examination revealed a diffuse swelling in the left lower third of the face measuring approx. 3x3 cms, roughly spherical in shape and was soft in consistency, non-tender with no secondary changes. Intra-oral examination revealed a solitary bluish colored swelling in the left buccal mucosa [Fig-1A] extending anteriorly from the left retro-commisural area till the retromolar area measuring approximately 3x4 cms with racemose surface and on palpation revealed soft in consistency, non-tender and with no pulsations. Posterior regions of the lesion revealed multiple hard calcified areas. Diascopy test was positive [Fig-1B]. FNAC revealed frank blood [Fig-1C], which was bright red in color. Clinically the lesion was considered to be a vascular malformation associated with phleboliths. Panoramic radiograph revealed multiple calcified areas in the left mandibular ramus region, which were considered to be superimposition of soft tissue calcifications associated with the lesion [phleboliths] [Fig-2A]. To confirm this, an intra-oral periapical radiograph was taken with the

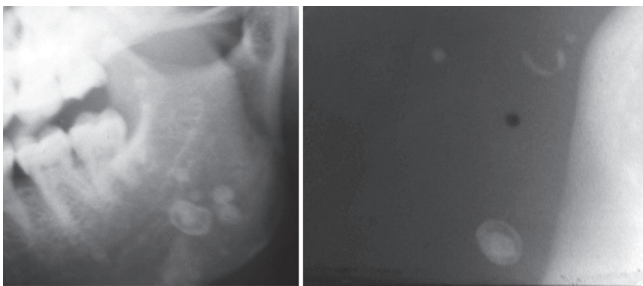


**Figure-1A:** Showing an intra-oral bluish colored lesion with racemose surface involving left buccal mucosa; **Figure-1B:** Showing positive Diascopy.

intra-oral film placed against the left buccal mucosa against the vascular lesion and exposed to x-rays. This resultant radiograph revealed multiple calcified areas with concentric pattern of calcification suggestive and confirmative of phleboliths [Fig-2B]. A final diagnosis of vascular malformation with phleboliths was considered.



**Figure-1C:** FNAC with aspiration of frank blood



**Figure-2A:** Cropped panoramic radiograph showing superimposition of soft tissue phleboliths over ramus of mandible region: **Figure-2B:** Intra-oral radiograph of soft tissue [left buccal mucosa] showing multiple calcifications.

## DISCUSSION

In 1982, Mulliken and Glowacki<sup>2</sup> proposed a binary classification system for vascular anomalies based on pathologic features. This system, which was adopted by the International society for the study of Vascular Anomalies [ISSVA]<sup>3</sup>, has since been expanded and is now widely accepted. The ISSVA classification system divides vascular anomalies into 2 primary biological categories: (1) Vasoproliferative or Vascular neoplasms and (2) vascular malformations.<sup>1</sup> The term hemangioma is reserved for vascular tumors only. During the proliferative phase they grow and resolve. The proliferative phase occurs during the first year, and spontaneous involution of hemangiomas is observed usually by the age of 7 years. Nearly 30% of hemangiomas are present at birth, and the rest develop within the first 3 months of life. There is substantial evidence of endothelial hyperplasia on obtaining biopsies from hemangiomas. In contrast, vascular malformations are congenital, developmental anomalies. 90% of them are present at birth and show no endothelial proliferation. They have no

tendency for spontaneous involution.

Vascular malformations are classified into high flow and low flow lesions based upon the amount of blood supplying the malformation. There is no increase in the local skin temperature or thrill when the lesion is palpated. Their typical slow growth may cause them to be asymptomatic for many years.<sup>4</sup> Our patient exactly had similar clinical presentation. The lesion was not clinically evident at birth and was noticed only during her first year of life and was more pronounced during her puberty.

Association of phleboliths with intra-oral vascular malformations is a rare phenomenon. According to Ribbert's theory, phlebolith formation begins with intravascular thrombus formation and is followed by progressive lamellar fibrosis. Phleboliths are intravascular calcifications observed in long standing cases. They present Radiographically as concentric layered calcifications, which are usually multiple in number.<sup>5</sup> The present case had a similar radiographic presentation of multiple concentric pattern of calcifications distributed over left buccal mucosa.

## CONCLUSION

In conclusion, we report a case of a rare intra-oral vascular malformation associated with phleboliths. Such lesions should always be kept in mind for differential diagnosis when presented clinically and radiologically similar to our case. This ensures minimal possibility of encountering fatal and uncontrolled bleeding complications.

## REFERENCES

1. Jayaraman V, Austin RD, Kannan S. Nonsurgical management of vascular malformation of masseter. *Indian J Dent Res* 2015;26:96-100.
2. Mulliken JB, Glowacki J. Hemangiomas and vascular malformations in infants and children: A classification based on endothelial characteristics. *Plast Reconstr Surg* 1982;69:412-22.
3. Enjolras O. Classification and management of the various superficial vascular anomalies: Hemangiomas and vascular malformations. *J Dermatol* 1997;24:701-10.
4. Garzon MC, Huang JT, Enjolras O, Frieden IJ. Vascular malformations: part I. *J Am Acad Dermatol* 2007;56:353-70.
5. Scolozzi P, Laurent F, Lombardi T, Richter M. Intraoral venous malformation presenting with multiple phleboliths. *Oral Surg Oral Med Oral Pathol Oral Radiol Endod.* 2003;96:197-200.