

## CASE REPORT

## A Case Report on Unilateral Choanal Atresia

Amit Kumar<sup>1</sup>, Abhinav Paul Minj<sup>2</sup>, Tarun Gurjar<sup>3</sup>, Chandra Kant<sup>4</sup>

## ABSTRACT

**Introduction:** Unilateral choanal atresia usually presents later in life than bilateral and may present in adults. Choanal atresia is an uncommon and rarely recognized cause of unilateral nasal obstruction. Here is a

**Case Report:** 19 year old male who presented with complains of unilateral nasal obstruction and discharge not clearly pointing to the diagnosis. The canalization was done endoscopically. This article focuses the role of CT scan and nasal endoscopy in the diagnosis and treatment of the same.

**Conclusion:** Our reported case highlighted the fact that choanal atresia especially unilateral is a rarely recognised cause of nasal obstruction and is often diagnosed late. Hence endoscopic/radiological investigations are mandatory to make a diagnosis for complaints of persistent nasal obstruction for so many years.

**Keywords:** Unilateral, Choanal, Atresia, Endoscopic

**How to cite this article:** Amit Kumar, Abhinav Paul Minj, Tarun Gurjar, Chandra Kant. A case report on unilateral choanal atresia. International Journal of Contemporary Medical Research 2015;2(4):997-999

<sup>1</sup>Senior Resident, <sup>2</sup>Junior Resident, <sup>3</sup>Junior Resident, <sup>4</sup>Prof & Head, Department of Otorhinolaryngology, Rajendra Institute of Medical Sciences, Ranchi

**Corresponding author:** Dr. Amit Kumar<sup>1</sup>Senior Resident, Department of Otorhinolaryngology, Rajendra Institute of Medical Sciences, Ranchi, India

**Source of Support:** Nil

**Conflict of Interest:** None

## INTRODUCTION

Choanal atresia is a developmental disorder in which the posterior nasal cavity fails to develop and therefore no communication between nasal cavity and nasopharynx. The Incidence of Choanal atresia is approximately 1 in 5000 to 7000 births.<sup>1</sup> It occurs more commonly in females than in males and is more often unilateral than bilateral.<sup>2</sup> Bilateral choanal atresia requires rap-

id management at birth and prompt diagnosis because neonates are predominantly obligate nasal breathers.<sup>3</sup> Unilateral choanal atresia is often diagnosed after several months of life. Unilateral choanal atresia is usually not associated with other facial anomaly or with syndromic malformations although most common associated congenital anomaly is CHARGE association (C=coloboma, H = heart disease, A = atresia of choanae, R = retarded growth and development, G =genital hypoplasia, E = ear deformities or deafness).<sup>4</sup> Persistent unilateral rhinorrhoea or failure to pass a catheter through the obstructed nasal fossa (during a general anesthesia for example) makes the diagnosis of choanal atresia probable. Choanal atresia is an uncommon and rarely recognized cause of unilateral nasal obstruction. This case report documents the case of a patient with unilateral choanal atresia who remained undiagnosed for many years.

## CASE REPORT

A 19 year old man presented with a prolonged history of complete nasal obstruction and discharge on left side. He also complained of loss of sense of smell on left side since childhood with associated features of mouth breathing and snoring. On examination he had slight facial asymmetry with the dorsum slightly deviated to right.

On speculum examination initially it was confused as a case of chronic rhinosinusitis as thick vicid secretion could be seen at the floor of nose. On x-ray PNS only hazy bilateral maxillary sinuses could be noted.

Patient was taken for endoscopic examination, which on suction of the left nasal cavity on first pass nasal endoscopy showed absence of posterior choanae, which was confirmed on Rhinography and CT-scan. It was finally diagnosed a case unilateral bony choanal atresia. This patient was treated multiple times before at many general practitioners as a case of allergic chronic rhinosinusitis.

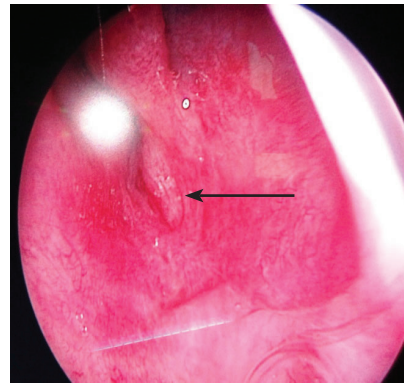
Computed tomography coronal cuts elicited bony atresia with prolapsed mucosal thickening at the left choanal with polypoidal mass at posterior choanae region. Rest of the investigations were within normal limits. Patient was posted for transnasal surgery. Endoscopic

transnasal route was preferred, with initial use of burr and later enlarged using dilators. A pack was placed pre operatively in nasopharynx to protect the structures in the area. Silastic tube was inserted for six weeks to maintain the patency. Antibiotics, anti-inflammatory, saline nasal spray and proper nasal toileting was advised and the patient made an uneventful post-operative recovery.

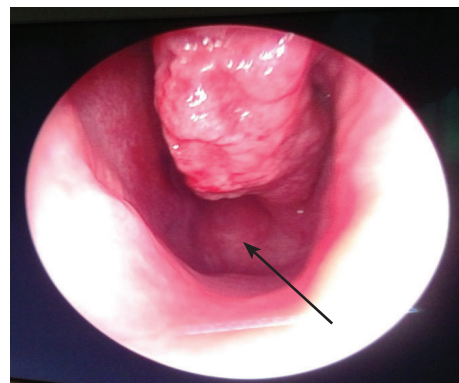
**DISCUSSION**

Choanal atresia is a congenital obstruction of posterior nasal aperture or Choanal usually thought to be secondary to persistence of either the nasobuccal membrane of Hochstetler or the buccopharyngeal membrane from the foregut. This membrane normally ruptures between the fifth and sixth weeks of gestation to produce choanae. Failure of this membrane to rupture causes atresia of choanae and may be bony, membranous or mixed.<sup>5</sup> Previously reports suggested a 90% bony stenosis and 10% membranous, but more recent analysis suggests a mixed bony/membranous in 70% and pure bony in 30%.<sup>6</sup>

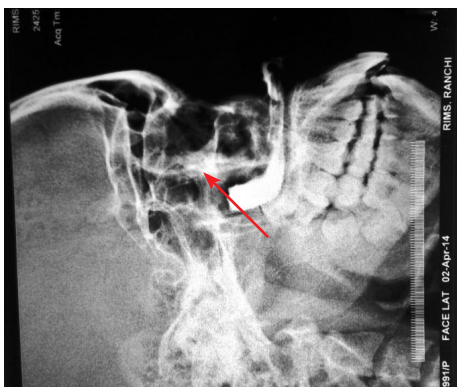
Unilateral or bilateral choanal atresia was first described by Roederer in 1751 and was first reported in



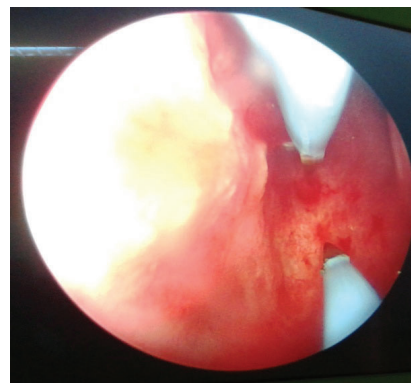
**Figure-3:** Endoscopic view of the atresia.



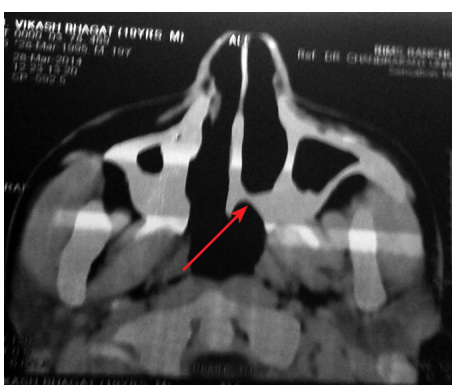
**Figure-4:** Endoscopic view of the atresia with inferior turbinate.



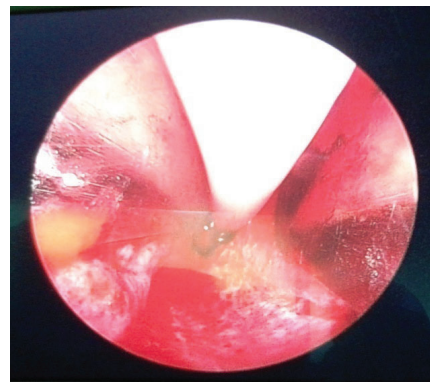
**Figure-1:** Rhinography Lateral view showing radio opaque substance not communicating the nasal cavity & Nasopharynx.



**Figure-5a:** Endoscopic view to creating opening at posterior choanae.



**Figure-2:** CT-Scan showing bony atresia



**Figure-5b:** Endoscopic view showing insertion of rubber catheter through opening at posterior choanae.

Britain in 1881 by Ronaldson. Carl Emmert in Bern operated successfully on a patient of choanal atresia in 1851. He perforated the bilateral choanal atresia via the transnasal approach using a curved trocar after having practiced the perforating force on the hard palate of child's corpse. Bilateral choanal atresia presents at birth as a respiratory emergency. Occasionally unilateral choanal atresia may present in young with feeding difficulties especially when the non-affected side of the face is occluded. Unilateral cases do not present until late childhood or adulthood.

Out of a hundred cases of choanal atresia, it is found that approximately 60-70 cases are unilateral whereas rest being bilateral. Several syndromes such as Crouzon's syndrome, Down syndrome, Treacher-Collins syndrome, DiGeorge syndrome may have presenting features of choanal atresia. There are several anomalies as well that may be associated with it such as polydactyly, nasal-auricular and palatal deformities, craniosynostosis and cleft palate.

In a study 78 children were reviewed to depict any comorbid conditions with Choanal atresia. This pie diagram concludes the presence of several conditions with choanal atresia. In other studies, CHARGE syndrome, obstructive sleep apnea, hematological problems, and prematurity or failure to thrive were also correlated to Choanal atresia. It was also found that bilateral choanal atresia and cardiac disorders co-existed in several cases.

In about 30% of cases they are pure bony, whereas in 70%, they are mixed bony-membranous.<sup>8</sup> Theatretic plate is usually positioned in front of the posterior end of the nasal septum. The anatomic deformities commonly seen are a narrow nasal cavity, lateral bony obstruction by the lateral pterygoid plate, medial obstruction caused by thickening of the vomer, and membranous obstruction.<sup>9</sup>

Acquired posterior choanal atresia has a very rare occurrence. Sometimes the actual cause of Acquired Choanal atresia is not known however, it can result due to any rhinopharyngeal injury for e.g. after surgery such as adenoidectomy or due to radiotherapy for nasopharyngeal carcinoma<sup>10</sup>; or can be associated with certain diseases like tuberculosis or syphilis of epipharynx, or sometimes by unknown causes.

## CONCLUSION

Choanal atresia can be an isolated anomaly, however 60% cases of congenital defect has found to be associated with Down's and Treacher Collin's syndrome

but may be found with other isolated defects such as micrognathia, tracheoesophageal fistula, cleft and high arched palate, missing teeth and facial cleft. In addition to these random associations choanal atresia has recently been linked with a number of specific defects the so called CHARGE association. Our reported case highlighted the fact that choanal atresia especially unilateral is a rarely recognised cause of nasal obstruction and is often diagnosed late. Hence endoscopic/radiological investigations are mandatory to make a diagnosis for complaints of persistent nasal obstruction for so many years.

## REFERENCES

1. Samadi DS, Shah UK, Handler SD. Choanal atresia: a twenty years review of medical co-morbidity and surgical outcomes. *Laryngoscope* 2003;113:254-8.
2. Dobrowski JM, Grundfast KM, Rosenbaum KN, Zajtchuk JT. Otorhinolaryngic manifestations of CHARGE association. *Otolaryngol Head Neck Surg* 1985; 93: 798-803.
3. Karampal Singh, Sarla Hooda, Punam Raghove, Geeta Ahlawat, Rashmi Taneja: Bilateral Congenital Choanal Atresia: A Case Report. *The Indian Anesthetists' Forum*, July 2011(2):<http://www.theiaforum.org>
4. Bergstrom L, Owens O. Posterior choanal atresia: a syndromal disorder. *Laryngoscope* 1984;94:1273-6.
5. Dunham ME, Miller RP. Bilateral choanal atresia associated with malformation of the anterior skull base: embryogenesis and clinical implications. *Ann Otol Rhinol Laryngol* 1992; 101: 916-9.
6. Paraya Assanasen, Choakchai Methetrirut. Choanal Atresia. *J Med Assoc Thai* 2009; 92: 699-706:<http://www.mat.or.th/journal>.
7. Harris J, Robert E, Kallen B. Epidemiology of choanal atresia with special reference to the CHARGE association. *Pediatrics* 1997; 99: 363-7.
8. Brown OE, Pownell P, Manning SC. Choanal atresia: a new anatomic classification and clinical management applications. *Laryngoscope* 1996; 106: 97-101.
9. Harner SG, McDonald TJ, Reese DF. The anatomy of congenital choanal atresia. *Otolaryngol Head Neck Surg* 1981; 89: 7-9.
10. Ku PK, Tong MC, Tsang SS, van Hasselt A. Acquired posterior choanal stenosis and atresia: management of this unusual complication after radiotherapy for nasopharyngeal carcinoma. *Am J Otolaryngol* 2001; 22: 225-9.