

CASE REPORT

Esthetic Management Of Connate Permanent Tooth Using A Silicon Putty Guide: A Case Report

Priyanka Razdan¹, Chanchal Singh², Kalpana Chaudhry³, Sonal Gupta³, Pranav¹

ABSTRACT

Introduction: A number of bizarre and unusual anomalies of the teeth have been reported in the literature. Gerniation is one of the odontogenic anomaly where in the teeth are united. It refers to the attempt at division of a tooth germ, resulting in formation of single large tooth, with groove or notch.

Case Report: This article is an illustration of esthetic management of geminated permanent maxillary lateral incisor using a Silicone Putty guide.

Conclusion: Esthetic management using direct composite build up is difficult and requires more time. Silicone putty stent serves as an accurate guide for restoration giving accurate incisal and proximal contours of the tooth.

Keywords: Developmental anomalies, Double tooth, Gerniation, Lateral incisor

How to cite this article: Priyanka Razdan, Chanchal Singh, Kalpana Chaudhry, Sonal Gupta, Pranav. Esthetic management of connate permanent tooth using a silicon putty guide: a case report. International Journal of Contemporary Medical Research 2015;2 (2):118-121

¹Post Graduate Student, ²Professor and Head, ³Reader, Department of Pedodontics, K.D. Dental College and Hospital, Mathura, India

Corresponding author: Dr. Priyanka Razdan, Post Graduate Student, Department of Pedodontics and Preventive Dentistry, K.D. Dental College and Hospital, Mathura, Uttar Pradesh, India

Source of Support: Nil

Conflict of Interest: None

INTRODUCTION

Odontogenic anomalies of number and form can occur in the primary and permanent dentition. These anomalies can occur as a result of conjoin-

ing or twinning defects. Gerniation is a developmental anomaly of form, which is recognized as an attempt by a single tooth germ to divide resulting in the large single tooth with a bifid crown and usually a common root and root canal. It is seen in permanent as well as in deciduous dentition.¹ There is an overall prevalence of 0.5% in deciduous dentition, 0.1% in permanent teeth and 0.02% in both dentitions. They more commonly occur in the maxillary anterior region.²

The terms such as fused teeth, dichotomy, dental twinning, synodontia, connation are often used to describe fusion or germination both of which are primary dental anomalies of teeth. Gerniated teeth are usually asymptomatic. The etiology is unknown, but trauma has been suggested as a possible cause in the anterior region, this anomaly can cause unpleasant esthetic appearance due to irregular morphology. If a deep groove is present these teeth may be susceptible to caries and periodontal disease may require endodontic intervention in some cases which may be complicated³. In clinical situation cases of fusion have appearance of congenitally missing tooth. While in germination the number of teeth in dentition is normal provided that the double tooth is counted as one unit.^{3,4} This paper reports aesthetic rehabilitation of a geminated right maxillary lateral incisor.

CASE REPORT

A 14 year old boy referred to the department of Pedodontics and Preventive dentistry complained about appearance of unpleasant maxillary lateral incisor and lip irritation. Patient did not complain of any previous painful symptoms in that region and his medical and dental histories were unremarkable. Clinical examination revealed irregular morphology representing conical double tooth in maxillary dental arch (Fig-1). The

intraoral periapical radiograph and maxillary occlusal view were taken (Fig-2,3). The clinic-radiologic correlation was concluded germination of right maxillary lateral incisor as the morphology of other teeth and number of teeth were normal.

Treatment plan for the patient included esthetic rehabilitation. The Upper and lower impressions were made in alginate and the models were prepared using dental stone. The Buccal bulge on the conical tooth was scraped off on the model and a laboratory wax up was done using inlay wax to mimic the final esthetic look. A composite build up guide was fabricated using additional type silicone elastomeric impression material (Fig 4) (attinis putty supersoft, polyvinylsiloxane, coltene/ Whatedent/ AG /Altstatten, Switzerland) to register the palatal surface, proximal contours and the incisal edges of right lateral incisor against which the composite resin would be build.(Fig 4). Using this silicone putty guide the Buccal bulge of right maxillary lateral incisor was then clinically trimmed. The teeth were etched for 15 seconds with 37% phosphoric acid (scotchbond, 3MESPE, St.paul, minn) then photopolymerised for 20 seconds. The silicone putty guide was then placed in the oral cavity and then the right maxillary lateral incisor was build using composite resin (3M ESPE, St.Paul, Minn) in increments that were photopolymerised. Final finishing and polishing was done using a composite finishing kit and sofex discs (3M ESPE, St. Paul, Minn) (Fig 5). A follow up was done with the patient after one month and the clinically acceptable results were obtained.

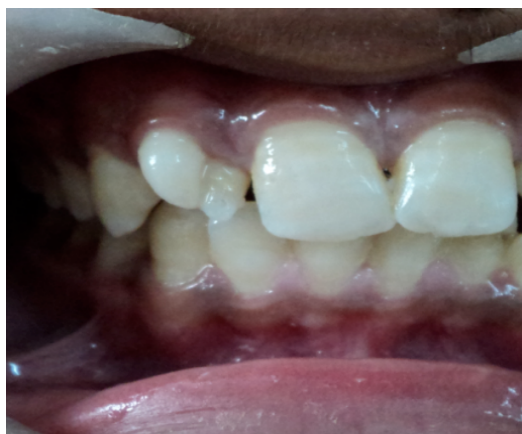

Figure-1: Intraoral view showing gemination of right maxillary lateral incisor

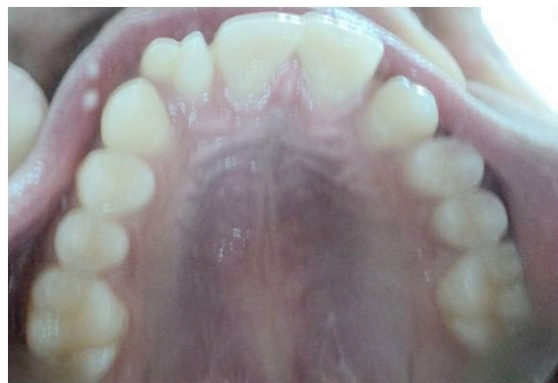

Figure-2: Intra oral view showing maxillary occlusal view

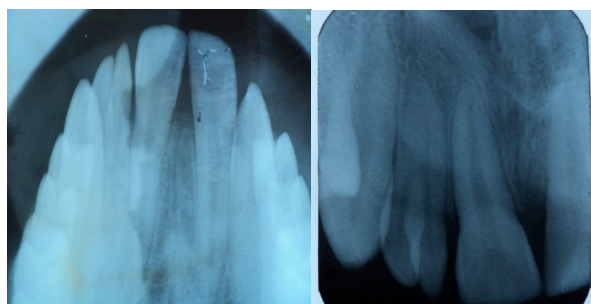


Figure-3,4: Radiographic view of geminated right maxillary lateral incisor

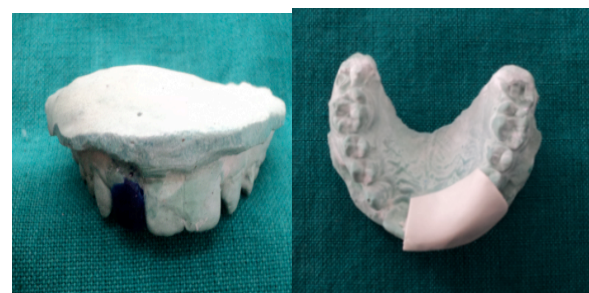

Figure-4: Mock up done using inlay wax and fabrication of silicone putty stent

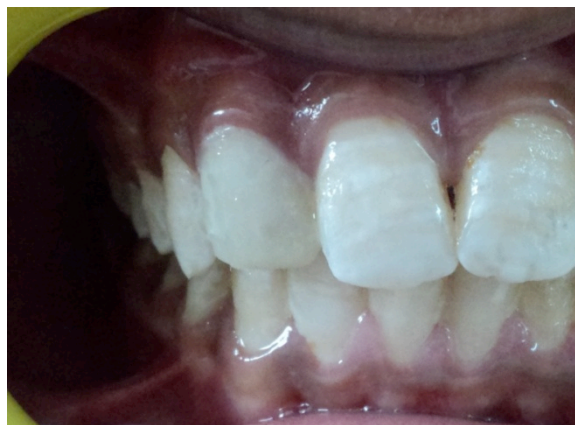

Figure-5: Intraoral view showing after esthetic build up

DISCUSSION

Gemination is the result of a developmental aberration of both mesoderm and the ectoderm. These disturbances are related to the local metabolic interferences occurring during morphodifferentiation of the tooth germ. The main etiology of the tooth germ remains unknown, but physical pressure leading to the union of teeth and genetic inheritance have been suggested as a possible cause⁵. It is hard to differentiate between germination and fusion. Some researcher's tried to differentiate them by counting the teeth. Madder's "two tooth" rule may be a practical way of differentiating between fusion and germination.⁴

It is essential to diagnose the anomaly carefully and to organize a conservative individualized treatment plan. Conventional radiography is almost universally used, e.g., periapical radiographs, occlusal radiographs and panoramic radiographs for the diagnosis of dental anomalies. However, all these diagnostic aids give only 2-D views of the tooth Abbas et al, used CBCT for diagnosing geminated central incisors.⁵ It provides 3D visualization of pulpal anatomy and construction of stereolithographic model for treatment planning.

According to Nik-hussein, the anomalies of permanent teeth are strongly associated with anomalies in primary dentition, for example, presence of germination in primary dentition is associated with involvement of permanent teeth in approximately 60% of cases.⁶ However in our case the patient did not have any dental abnormalities in his primary dentition with no evidence of same dental problems in his family members.

Gemination of maxillary central incisor was reported by many authors; Chipashvili et al pointed out that maxillary central incisor are most commonly affected by germination.⁵ This finding was in contrast of our case. Where as germination of maxillary permanent lateral with unilateral presentation was rarely reported. So our case is a rare clinical presentation. In the present case the right lateral incisor was peg shaped with two halves being joined separated by buccolingual groove. It was a single tooth with a single canal present radiographically. The

problem associated with geminated teeth are esthetics, malocclusion and crowding. The presence of groove and fissure on labial and lingual surface predispose the teeth for caries and periodontal disease.² Identification and diagnosing a rare and asymptomatic developmental anomaly like germination is essential as they cause problem with esthetics, malocclusion and crowding. The morphology predispose the tooth for caries and periodontal disease. Through knowledge of the existence and morphology of the germination helps the clinician for orthodontic, preventive, conservative, endodontic and prosthodontic treatment planning. Hasan et al reported esthetic restorations using putty matrix technique.^{7,8} A similar esthetic management was planned by Agarwal R et al for a primary double tooth using silicone putty guide.¹ Different cases require a variety of knowledge about alternative operative techniques, Turkasian et al reported esthetic rehabilitation of permanent maxillary central incisor utilizing all ceramic crowns.³ These fixed restorations treatment resulted in marked improvement in strength. The limitation in management of our case included that composite resin has compromised strength as compared to the ceramic crowns. Unfortunately our patient's parent could not afford any other treatment plan so management using direct composite using silicone putty guide. A systematic and problem solving approach made possible an esthetic outcome of the case and resulted in an extremely satisfied patient.

CONCLUSION

Esthetic management using direct composite build up is difficult and requires more time for trimming and polishing of the restoration. The silicone putty stent serves as an accurate guide for composite restoration giving accurate incisal and proximal contours of the tooth and appears to be good alternative to esthetic enhancement if such anomalies.

REFERENCES

1. Agarwal R, Chaudhry K, Munshi AK. Esthetic management of a primary double

- tooth using silicone putty guide:A Case report. CDA Journal 2013;41: 203-205
2. Rajeswari MRC, Anantalakshmi R. Gemination- Case Report and Review. Indian journal of multidisciplinary dentistry 2011;6: 355-356
 3. Turkasian S, Gokee HS, Dalkiz M. Esthetic rehabilitation of bilateral geminated teeth: A case report. Eur J Dent 2007;1:188-191.
 4. Bhargava M, Chaudhary D, Aggarwal S. Fusion presenting as germination:A rare case report. OMPJ 2012; 3: 211-214
 5. Shikri A, Baharvand M, Mortazavi H The largest bilateral germination of permanent maxillary central incisor: Report of a case. J Clin Exp Dent 2013;5:295-297
 6. Nik-Hussein NN, Abdul Majid Z. Dental anomalies in the primary dentition: distribution and correlation with the permanent dentition. J Clin Pediatr Dent. 1996;21:15–9.
 7. Hasan A, Sahid O. Esthetic Restoration, The putty matrix technique. Journal of the Dow University of Health Sciences Karachi 2013;7: 122-125
 8. Ghosh S, Gupta S, Singh K, Urs A . Verruciform Xanthoma Associated With Oral Submucous Fibrosis - A Report of An Unusual Case With Literature Review. International Journal of Contemporary Medical Research 2014;1:88-91