

# Pityriasis Versicolor on Male Genital Area: A Rare Presentation

Sheikh Manzoor<sup>1</sup>, Syed Shahab ud din Bukhari<sup>2</sup>, Suhail Raheem Rather<sup>2</sup>, Samia Aleem<sup>2</sup>

## ABSTRACT

**Introduction:** Pityriasis versicolor is a very common fungal infection. This disease is caused by infection due to yeast-*Malassezia furfur*. Presentation consists of a superficial scaling and a mild disturbance of skin pigmentation ranging from hypopigmentation to mild hyperpigmentation. Genital Pityriasis versicolor though rare, is not very uncommon, and should always be a part of differential diagnosis for such lesions in genital area.

**Case Report:** A 28 year old circumcised male patient presented to the outpatient department for consultation in view of three month history of a few hypopigmented lesions over the penile shaft and a few hyperpigmented lesions over the skin of pubic region. On clinical and woods lamp examination, genital pityriasis versicolor was diagnosed. The condition is very benign, but may be very worrisome for the patient due to the awkward location of the lesions. The patient should be reassured about the satisfactory outcome in this disease.

**Conclusion:** Genital Pityriasis versicolor though rare, is not very uncommon, and should always be a part of differential diagnosis for such lesions in genital area.

**Keyword:** Pityriasis Versicolor

## INTRODUCTION

Pityriasis versicolor is a very common fungal infection. This disease is caused by infection due to yeast- *Malassezia furfur* and *M. Globosa* being the most common ones.<sup>1,2</sup> This yeast is a normal skin commensal occurring in spore stage. In patients with clinical disease, this commensal organism becomes pathogenic and is found in both the yeast (spore) stage and the filamentous (hyphal) form.

The involved skin regions are usually trunk, back, abdomen and the proximal extremities. Face, scalp and genitalia are less commonly involved. The presentation consists of a superficial scaling and a mild disturbance of skin pigmentation ranging from hypopigmentation to mild hyperpigmentation.<sup>3</sup> In a few cases, the patients may have pruritus and erythema as well.

## CASE REPORT

A 28 year old circumcised male patient presented to the outpatient department for consultation in view of three month history of a few hypopigmented lesions over the penile shaft and a few hyperpigmented lesions over the skin of pubic region (Fig1). The lesions were non pruritic, with scaly surface. There was no preceding history of any cutaneous infection in the penile or pubic area. There was no history suggestive of any genital dermatoses like atopic eczema, psoriasis, allergic contact dermatitis or seborrheic dermatitis. The general physical examination and detailed systemic examination in this patient were otherwise unremarkable, except for similar

lesions over his trunk and back (Fig. 2). The baseline investigations like hemogram, liver function tests, kidney function tests, hepatitis serology and HIV serology were normal.

Woods lamp examination revealed yellow green fluorescence in the affected area. Samples were taken from the sites of the lesions in this patient. Potassium hydroxide (KOH) examination of these samples confirmed the diagnosis of pityriasis versicolor in view of the characteristic yeast and mycelia filaments seen therein. The patient was treated with topical ketoconazole for 4 weeks. After 4 weeks, the lesions had resolved completely and KOH examination from this area was negative.

## DISCUSSION

Pityriasis versicolor is a common benign superficial cutaneous fungal infection. The usual sites involved are the trunk, back, abdomen and proximal extremities.<sup>4</sup> The lesions in the genital area are very rare and there have been only few case reports of this presentation.<sup>5,6</sup> *Malassezia* is a commensal in most of the population. The reasons for the conversion of this commensal into a pathogen are not known exactly. But, various factors like humid and warm environment, genetic predisposition, immunosuppression and malnutrition are known to predispose to this condition.<sup>7-9</sup>

Various treatment modalities are available for this condition, These include oral drugs like fluconazole and itraconazole, and topical agents like selenium sulfide, sodium sulfacetamide, ciclopiroxolamine,<sup>17</sup> as well as azole and allylamine antifungals.

There was no evident factor like immunosuppression or malnutrition or humid and warm environment, which could be linked with the occurrence of this condition in our patient. There may have been some genetic factors involved, which we could not elicit.

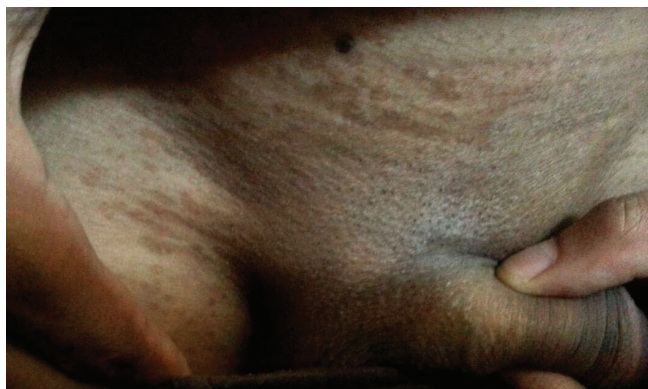Circumcised males are protected against the involvement of glans in various cutaneous infections and sexually transmitted infections, as has been reported in literature.<sup>10</sup> Similarly, in this indexed case the glans was not affected.

Genital Pityriasis versicolor though rare, is not very uncommon, and should always be a part of differential diagnosis for such lesions in genital area. The condition is very benign, but may be very worrisome for the patient due to the awkward

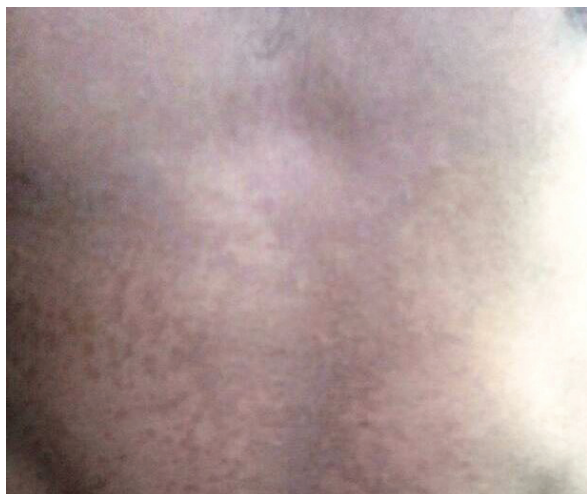
<sup>1</sup>Associate Professor, <sup>2</sup>Senior Resident, Department of Dermatology, STD and Leprosy, SKIMS MCH, Srinagar, India

**Corresponding author:** Syed Shahab ud din Bukhari, Senior Resident, Department of Dermatology, STD and Leprosy, SKIMS MCH Srinagar. 190017

**How to cite this article:** Sheikh Manzoor, Syed Shahab ud din Bukhari, Suhail Raheem Rather, Samia Aleem. Pityriasis versicolor on male genital area: a rare presentation. International Journal of Contemporary Medical Research 2016;3(3):634-635.



**Figure-1:** Hyperpigmented lesions over the skin of pubic region



**Figure-2:** Hyperpigmented lesions over trunk

location of the lesions. The patient should be reassured about the satisfactory outcome in this disease.

## CONCLUSION

Genital Pityriasis versicolor though rare, is not very uncommon, and should always be a part of differential diagnosis for such lesions in genital area.

## REFERENCES

1. Erchiga V, Florencio VD. Malassezia yeasts and pityriasis versicolor. *Curr Opin Infect Dis.* 2006;19:139-47.
2. Gaitanis G, Velegraki A, Alexopoulos EC, Chasapi V, Tsigonia A, Katsambas A. Distribution of Malassezia species in Pityriasis versicolor and seborrhoeic dermatitis in Greece. Typing of major pityriasis versicolor isolate *M.globosa*. *Br J Dermatol.* 2006;154:854-9.
3. Varada S, Dabade T, Loo DS. Uncommon presentations of tinea versicolor. *Dermatol Pract Concept.* 2014;4:93-96.
4. Daneshvar SA, Hashimoto K. An unusual presentation of Tinea versicolor in an immunosuppressed patient. *J Am Dermatol.* 1987;17:304-5.
5. Khaddar RK, Cherif F, Ben Hadid R, Mokni M, Ben Osman A. Penile shaft involvement in Pityriasis versicolor. *Acta Dermatovenerol Alp Pannonica Adriat.* 2008;17:86-9.
6. Crespo Erchiga V, Ojeda Martos A, Vera Casaño A, Crespo Erchiga A, Sanchez Fajardo F. Malassezia globosa as the causative agent of Pityriasis versicolor. *Br J Dermatol.* 2000;143:799-803.
7. Burkhart CG, Dvorak N, Stockard H. An unusual case of Tinea versicolor in an immunosuppressed patient. *Cutis.* 1981;27:56-8

8. Gulec AT, Demirbilek M, Seckin D, Can F, Saray Y, Sarifakioglu E et al. Superficial fungal infections in 102 renal transplant recipients: a case-control study. *J Am Acad Dermatol.* 2003;49:187-92.
9. Mendez-Tovar LJ. Pathogenesis of dermatophytosis and tinea versicolor. *Clin Dermatol.* 2010;28:185-9.
10. Mayer P, Schutz M, Schuppe HC, Jung A, Schill WB. Frequency and spectrum of Malassezia yeasts in the area of prepuce and glans penis. *BJU Int.* 2001;88:554-8.

**Source of Support:** Nil; **Conflict of Interest:** None

**Submitted:** 07-01-2016; **Published online:** 28-01-2016