

CASE REPORT

Florid Cemento-Osseous Dysplasia – A Rare Case Report In Indian Population

D.Kalyan Kumar¹, B.Kalyana Chakravarthy², K. Saraswathy Gopal³, N. Purnachandra Rao Naik¹, Mani Vasavi⁵

ABSTRACT

Introduction: Florid cemento-osseous dysplasia (FCOD) is a type of fibro-osseous lesion and represents a reactive process in which normal bone is replaced by poorly cellularized cementum-like materials and cellular fibrous connective tissues. It is strictly localized to the tooth-bearing or edentulous areas, often occurring bilaterally with symmetric involvements. Florid cemento-osseous dysplasia has been described as a condition that characteristically affects the jaws of middle-aged black women. It usually manifests as multiple radiopaque cementum-like masses distributed throughout the jaws.

Case report: A case of Florid cemento-osseous dysplasia occurring in a 42-year-old Indian female is reported which was rare in regard to race and sex. Multiple sclerotic masses with radiolucent border in the mandible were identified radiographically. Histopathological findings revealed formation of calcified dense sclerotic masses similar to cementum.

Conclusion: All clinical, radiographic, biochemical and histological features were suggestive of the diagnosis of Florid cemento-osseous dysplasia.

Keywords: Florid cemento-osseous dysplasia, Florid osseous dysplasia, Fibro-osseous lesions.

How to cite this article: D.Kalyan Kumar, B.Kalyana Chakravarthy, K. Saraswathy Gopal, N. Purnachandra Rao Naik, Mani Vasavi. Florid cemento-osseous dysplasia – a rare case report in indian population. International Journal of Contemporary Medical Research. 2015;2(2):232-235

Senior lecturer, Department of Oral Medicine and Radiology, ¹SIBAR College of Dental Sciences, Guntur, ²Sri Sai Dental College and Research Institute, Srikakulam, ³Professor and Head, Department of Oral Medicine and Radiology, Meenakshi Ammal Dental College, Chennai, ⁴Specialist Dental Clinic, Guntur, India

Corresponding author: Dr.D.Kalyan Kumar, Senior lecturer, Department of Oral Medicine and Radiology, SIBAR College of Dental Sciences, Guntur, India

Source of Support: Nil

Conflict of Interest: None

INTRODUCTION

Florid cemento osseous dysplasia refers to a group of fibro-osseous exuberant lesions with multi-quadrant involvement.¹ It is considered as a disease common among middle aged women of African origin, which was also reported among Caucasians and Asians.² In few cases, a familial trend can be observed. The lesions are usually asymptomatic and are incidental finding in panoramic radiographs.^{3,4} This paper reports one such incidental finding with a detailed discussion on etiopathogenesis, clinical, radiographic and histopathology.

CASE REPORT

A 42 yr old female reported to dental outpatient department with a complaint of pain in the left lower back tooth region for the past 10 days. Intraoral examination revealed deep caries in relation to left lower first premolar tooth, in addition patient presented with multiple edentulous areas seeking full mouth rehabilitation. Intraoral periapical radiograph (fig-1) of the premolar revealed proximal caries close to Pulpal tissue. In addition, an irregular periapical radiopacity was present in relation to the left lower first molar. Following this, the patient was subjected to panoramic radiograph (fig-2), which revealed irregular periapical radiopacities in relation to left upper second premolar and right lower first molar teeth region. IOPA of 23, 24, 25 teeth region revealed a well defined periapical radiopacity surrounded by a radiolucent rim. Based on radiographic evaluation a clinical diagnosis of Florid cemento osseous dysplasia was considered. With an informed consent, biopsy

was performed in the periapical region of left lower first molar tooth and submitted for histopathological evaluation. The decalcified section showed (fig-3) broad bony trabeculae with hematoxylic reversal lines and the bony trabeculae are arranged in a jigsaw puzzle and exhibited a mosaic pattern. The marrow spaces in between the trabeculae exhibited increased vascularity, few areas showed calcified tissues in the form of globules resembling cementum suggestive of Florid cemento osseous dysplasia.

DISCUSSION

Cemento-osseous dysplasias are a group of disorders known to originate from periodontal ligament tissues and involve, essentially, the same pathological process. They are usually classified, depending on their extent and radiographic appearances, into three main groups: periapical (surrounds the periapical region of teeth and are bilateral), florid (sclerotic symmetrical masses) and focal (single lesion) cemental dysplasias. Florid cemento-osseous dysplasia clearly appears to be a form of bone and cemental dysplasia that is limited to jaws.¹

Florid cemento-osseous dysplasia was first described by Melrose et al² in 1976. This condition has been interpreted as a dysplastic lesion or developmental anomaly arising in tooth-bearing areas. Florid cemento-osseous dysplasia is more commonly seen in middle-aged black women (in some series, more than 90 percent of patients), although it also may occur in Caucasians and Asians.^{3,4} The striking points concerned with this Florid cemento-osseous dysplasia are: (a) The reason for this racial and gender predilection is unknown (b). In some cases, a familial tendency⁴ has been reported, but most examples appear to represent isolated instances (c). The lesions show a marked tendency for bilateral and often quite symmetric involvement, and it is not unusual to encounter extensive involvement of all four posterior quadrants. The process may be totally asymptomatic and, in such cases, the lesion is detected when radiographs are taken for some other purposes. Symptoms such as dull pain or drainage are almost always associated with exposure of sclerotic calcified masses in the oral cavity. This

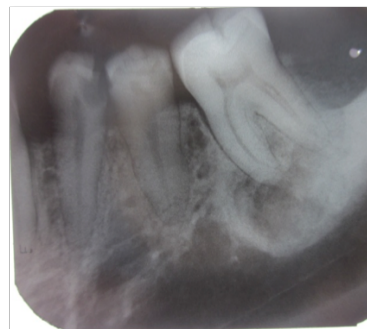


Figure-1: IOPA of 34,35,36 teeth region.

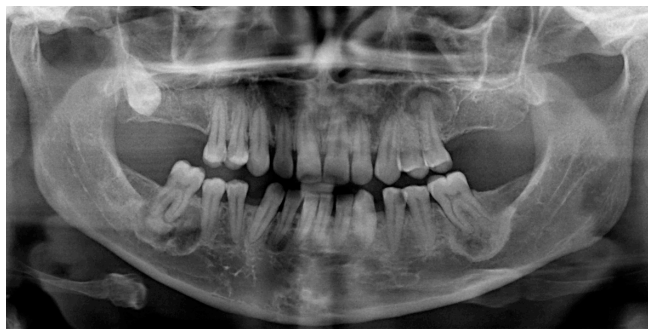

Figure-2: OPG

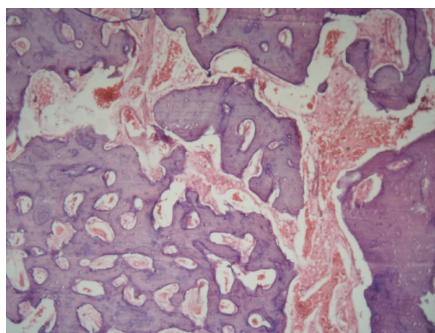


Figure-3: Histopathology

may occur as the result of progressive alveolar atrophy under a denture or after extraction of teeth in the affected area (d) Radiographically, the lesions appear as multiple sclerotic masses, located in two or more quadrants, usually in the tooth-bearing regions. They are often confined within the alveolar bone (e). Histologically, these lesions are composed of anastomosing bone trabeculae and layers of cementum-like calcifications embedded in a fibroblastic background. Management of florid cemento-osseous dysplasia may be difficult and not very satisfactory. The disease may persist for indefinite periods of time without causing any symptoms. For the asymptomatic patient, the best management consists of regular recall examinations with prophylaxis and reinforcement of good home hygiene care to control periodontal disease and prevent tooth loss.

Because the onset of symptoms is usually associated with exposure of the sclerotic masses to the oral cavity, biopsy or elective extraction of teeth should be avoided. Indeed biopsy increases the risk of infection or fracture of the jaw and it is not normally justified to surgically remove these lesions, as this often requires extensive surgery.^{5,6} Florid cemento-osseous dysplasia is a benign fibro-osseous lesion that must be differentiated from other benign fibro-osseous lesions such as fibrous dysplasia, ossifying fibroma, Paget's disease, and sclerosing osteomyelitis on the basis of combined clinical, radiographic, and histological features. However, this lesion do not appear to be developmental in nature such as fibrous dysplasia,⁷ nor do it show the characteristics of neoplasia such as ossifying fibroma.^{8,9} Paget's disease of the bone may have a cotton-wool appearance. However, this condition affects the bone of the entire mandible and shows loss of lamina dura, whereas florid cemento-osseous dysplasia is centered above the inferior alveolar canal and its cervical two thirds are normal.¹⁰ Paget's disease is often polyostotic, involving other bones such as spine, femur, skull, pelvis and sternum¹¹ and produces biochemical serum changes, such as elevated alkaline phosphate levels.^{12,13} No biochemical alterations and others bone involvement were found in the case reported.

Chronic diffuse sclerosing osteomyelitis is a primary inflammatory condition of the mandible presenting with cyclic episodes of unilateral pain and swelling and shows a single area of diffuse sclerosis containing small, ill-defined osteolytic areas. Where as florid cemento-osseous dysplasia is seen as multiple round or lobulated opaque masses. Chronic diffuse sclerosing osteomyelitis involves the body of the mandible from the alveolus to the inferior border and may extend into the ramus. Florid cemento-osseous dysplasia has been interpreted as a dysplastic lesion or developmental anomaly arising in tooth-bearing areas. In addition, florid cemento-osseous dysplasia is frequently associated with black women, while chronic diffuse sclerosing osteomyelitis is seen predominantly in adult Caucasian men.¹⁴ Florid cemento-osseous dysplasia may have similarities with jaw bone changes in familial adenomatosis coli (Gardner's syndrome),¹⁵ but

florid cemento-osseous dysplasia has neither skeletal changes or skin tumours or even the dental anomalies that are seen in this syndrome. In the present case no familial aspects of the disease could be established.

CONCLUSION

Normally, a diagnosis of florid cemento-osseous dysplasia in the jaws is made by clinical findings, radiographic features and histology. However, florid cemento-osseous dysplasia is a condition in which the diagnosis relies on radiology and clinical findings alone.

REFERENCES

1. Dađistan S, Tozođlu Ü, Göregen M, Çakur B. Florid cemento-osseous dysplasia: A case report. *Med Oral Patol Oral Cir Bucal*. 2007;12:E348- 50.
2. Melrose RJ, Abrams AM, Mills BG. Florid osseous dysplasia. A clinical-pathologic study of thirty-four cases. *Oral Surg Oral Med Oral Pathol*. 1976; 41: 62-82.
3. Kramer IRH, Pindborg JJ, Shear M. Neoplasma multiple enostosis, and gigantiform cementoma, and others lesions related to bone. In: World Health Organization (Editors)-Histologic Typing of Odontogenic Tumours. Berlin: Springer-Verlag; 1992; 28-31p.
4. Waldron CA. Fibro-osseous lesions of the jaws. *J Oral Maxillofac Surg*. 1985; 43: 249-262
5. Neville BW, Damm DD, Allen CM, Bouquot JE, eds. *Oral and Maxillofacial Pathology*. W.B. Saunders Company Philadelphia; Pennsylvania: 1995. p. 531-3.
6. Saadettin Dađistan, Ümmühan Tozođlu, Mustafa Göregen, Binali Çaku. Florid cemento-osseous dysplasia: A case report. *Med Oral Patol Oral Cir Bucal* 2007;12:E348-50.
7. Farzaneh AH, Pardis PM. Central giant cell granuloma and fibrous dysplasia occurring in the same jaw. *Med Oral Patol Oral Cir Bucal* 2005;10 Suppl 2: E1 30-2.
8. Perez-Garcia S, Berini-Aytes L, Gay-Escoda C. Ossifying fibroma of the upper jaw: report of a case and review of the literature. *Med Oral* 2004; 9: 333-9.
9. Galdeano Arenas M, Crespo Pinilla JI, Alvarez Otero R, Espeso Ferrero Verrier Hernandez A. Cemento-ossifying fibroma

- of mandibular gingiva: single case report. *Med Oral* 2004;9:176–9.
10. Langlais RP, Langland OE, Nortjé CJ. *Diagnostic Imaging of the Jaws*. 1st ed. Malvern: Williams & Wilkins; 1995.
 11. White SC, Pharoah MJ. *Oral Radiology - Principles and Interpretation*. 4th ed. Saint Louis: Mosby; 2000.
 12. Wolf J, Heitamen J, Sane J. Florid cemento-osseous dysplasia (gigantiformcementoma) in a Caucasian woman. *Br J Oral Maxillofac Surg* 1989;27:46
 13. Loh FC, Yeo JF. Florid cemento-osseous dysplasia in Orientals. *Oral Surg Oral Med Oral Pathol* 1989;68:748-753.
 14. Schneider LC, Mesa ML. Differences between florid osseous dysplasia and chronic diffuse sclerosing osteomyelitis. *Oral Surg Oral Med Oral Pathol* 1990;70:308–12
 15. Groot RH, van Merkesteyn JP, Bras J. Diffuse sclerosing osteomyelitis and florid osseous dysplasia. *Oral Surg Oral Med Oral Pathol Oral Radiol Endod* 1996;81:333–42.