

CASE REPORT

Multicystic Ameloblastoma: A Case ReportHarish Babu¹, Sudeshna Banerjee², Harshvardhan B³, Adeeb Hassan⁴, Modha Vishal D⁵**ABSTRACT**

Introduction: Ameloblastoma is the second most common, after odontoma, neoplasm of odontogenic origin. It is the most significant odontogenic neoplasm with its 18% incidence among all odontogenic tumours along with its clinical behaviour. Ameloblastomas are slow growing, painless tumours, rarely showing neurosensory changes with high recurrence rate (of 70%) and potential to undergo malignant transformation and metastasis (up to 2%). Ameloblastomas can appear in three different varieties – solid or multicystic, unicystic and peripheral.

Case Report: We report a case of multicystic ameloblastoma in a 30 years old female where in segmental resection and reconstruction with reconstruction plate along with free vascularized fibula flap was done.

Conclusion: The early diagnosis based on clinical and imaging data of patients with ameloblastoma is essential effective treatment of injury. Treatment decisions for ameloblastoma are based on the individual patient situation and the best judgement of the surgeon,

Keywords: Ameloblastoma, Multilocular, unicystic

How to cite this article: Harish Babu, Sudeshna Banerjee, Harshvardhan B, Adeeb Hassan, Modha Vishal D. Multicystic ameloblastoma: a case report. *International Journal of Contemporary Medical Research*. 2015; 2(2): 285-287

¹Reader, ^{2,3,4,5}Postgraduate student, Department of oral and maxillofacial surgery, The Oxford Dental College and Hospital, Bangalore, India, India.

Corresponding author: Dr. Harish Babu, Reader, Department of oral and maxillofacial surgery, The Oxford Dental College and Hospital, Bangalore, India.

Source of Support: Nil

Conflict of Interest: None

INTRODUCTION

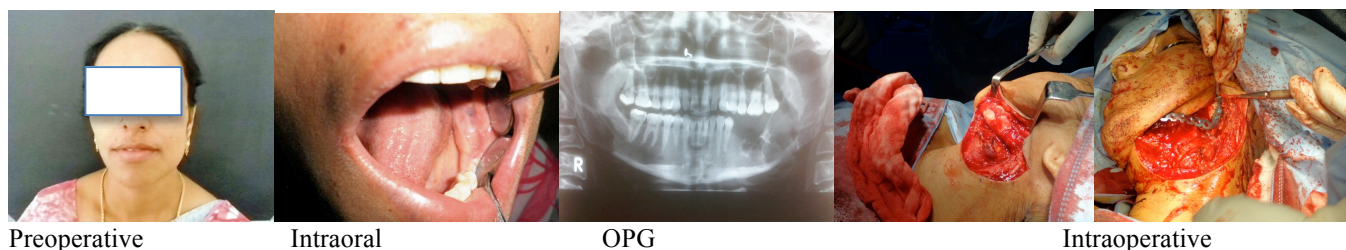
According to WHO 1992 definition Ameloblastoma is defined usually as:- unicentric, non-functional, intermittent in growth anatomically benign, locally invasive polymorphic neoplasm consisting of proliferating odontogenic epithelium, which usually has a follicular or plexiform pattern, lying in a fibrous stroma.¹ It accounts for 5-15% of all intraosseous ameloblastoma.²

Many benign lesions affects mandible, e.g. Ameloblastoma, radicular cyst, dentigerous cyst, keratocystic odontogenic tumour, central giant cell granuloma, fibro-osseous lesions and osteomas. These lesions may be having origin from the odontogenic or non-odontogenic source. The 2nd most common entity, after odontoma, in this group is ameloblastoma which is a true neoplasm of odontogenic origin. Ameloblastoma develops from the epithelial remnants of the enamel organ, epithelial remnants of malassez, reduced enamel epithelium and odontogenic cystic lining (e.g. of dentigerous cyst). Ameloblastomas can appear in three different varieties – solid or multicystic, unicystic and peripheral.³ multicystic ameloblastoma is the most common (85%) and most aggressive lesion, biologic behaviour of which was published by Gold 1991.⁴

Solid or multicystic ameloblastomas are often accidentally found as an asymptomatic “soap bubble” or “honeycomb appearance” commonly associated with unerupted third molar causing resorption of adjacent tooth roots.⁵

CASE REPORT

A 30 year old female patient reported with the complaint of a pain and swelling in the left lower jaw region since last 10 days. The patient gave a history of swelling on lower left jaw region from last 3 years. There was no history of similar swelling in the body. On extra oral examination, a single diffuse swelling about 4-5 cm in size was



seen in the left body and angle of mandible. The skin over the swelling was normal, without visible pulsation or secondary changes. On palpation the swelling was found to be non-tender, non-compressible, non-reducible and firm in consistency.

Intraorally, there was buccal and lingual expansion. The swelling was hard and non-tender. There was no rise in the temperature. Sub mandibular lymph nodes-Ipsilateral lymph node were palpable.

No cervical lymphadenopathy is present and neurosensory testing reveals normal mandibular nerve function and no other focal neurological deficit. In general examination the patient is well developed and well nourished.

Imaging

In this case OPG shows multilocular/soap bubble radiolucency extending from right first premolar to the sigmoid notch with loss of continuity of the lower border of the mandible.

In this patient, the panoramic radiograph demonstrates a multilocular, cystic-appearing lesion extending from right first premolar to the sigmoid notch of left side, also there is loss of continuity at the inferior border.

Surgical Treatment

Successful treatment is the treatment that renders an acceptable prognosis, causes minimal disfigurement and is based on the behaviour and growth and physical patterns, duration, relative anatomic location, clinical extent and histological findings of the tumour. High potential for recurrence (60-85%) after enucleation and curettage is observed so most surgeons tend to select more aggressive treatment options.⁶ for small lesions marginal resection with 1 cm safe margin beyond the radiographic limits was advocated.⁷

At the perforation site, overlying periosteum and resection (without maintaining the continuity)

was advised by many authors.⁸⁻¹¹

Mucosa was resected along with the tumour, leaving the condyle, and the defect was reconstructed with a standard reconstruction plate. Reconstruction of defect with free vascularized fibula flap and reconstruction plate is a good option after segmental resection.^{11, 4}

DISCUSSION

Ameloblastoma often persists as a slow growing, painless swelling, causing expansion of the cortical bones, perforation of the lingual and/or buccal plates and infiltration of soft tissues, occurring more frequently in the posterior mandible.¹² The lesions are often asymptomatic. In many patients, the lesion typically appears as a circumscribed radiolucency that surrounds the crown of an unerupted mandibular third molar, radio graphically resembling a dentigerous cyst.

There are seven histological types of ameloblastoma: follicular, plexiform, acanthomatous, granular cell, desmoplastic, basal cell, and unicystic variant, with the first two being the most common. Ameloblastoma can be either solid or multicystic, but they frequently demonstrate both characteristics. Although the majority of the tumours originate from within the maxilla or mandible, they can also be peripheral. The different histological variants don't significantly alter treatment considerations except for the unicystic and the peripheral types, which can't typically treated with enucleation and curettage.¹³

The long term follow ups with imaging are essential as multicystic ameloblastoma has recurrence rate of 50% in first five years after surgery. Unicystic variant show more favourable response to enucleation and curettage.^{14, 15}

CONCLUSION

The early diagnosis based on clinical and imaging

data of patients with ameloblastoma is essential effective treatment of injury. The decision must be based on the elimination of pathology considering the morbidity of treatment method and life quality in the rehabilitation of patients.^{7, 16}

Ameloblastoma is an aggressive tumour of odontogenic origin. There is some difference of opinion about preferable method of treatment, and the only unanimity centres around the fact that complete removal of neoplasm, regardless of how it is accomplished, will result in a cure of the patient. Treatment decisions for ameloblastoma are based on the individual patient situation and the best judgement of the surgeon.^{9, 10}

REFERENCES

1. Gulten, Vedat, Hilai. Unicystic Ameloblastoma in 8 years old child: A case report-review of unicystic ameloblastoma International dental and medical disorders 2008; 1:29-33.
2. Rakesh S, Ramesh, Suraj Manjunath, Tanveer H Ustad, Saira Pais k, Shivkumar. Ameloblastoma of mandible-an unusual case report and review of literature. Head and Neck Oncology, 2010; 1:29-33.
3. Gerzenshtein J, Zhang F, Caplanj, et al. Immediate mandibular reconstruction with microsurgical fibula flap transfer following wide resection for ameloblastoma Plast Reconstr Surg 2006; 117:178-182.
4. Gold L. Biologic behaviour of ameloblastoma. Clin Oral Maxillofac Surg 1991; 3: 21-71.
5. P Hollows, A Fasanmade & J P Hayter Case report: Ameloblastoma — a diagnostic problem British Dental Journal 2000; 18: 243 - 244
6. Pogrel MA, Montes DM. Is there a role for enucleation in the management of ameloblastoma? Int J Oral Maxillofac Surg. 2009; 38:807-12.
7. NevilleBW, DammDD, AllenCM, et al. Oral and Maxillofacial pathology, ed2, Newyork, 2002, WB Saunders.
8. Ferretti C, Polakow C, and Coleman H. Recurrent Ameloblastoma: Report of 2 Cases. J Oral Maxillofac Surg 2000; 58:800-4.
9. Müller H, Stootweg PJ. The growth characteristic of multilocular ameloblastomas. J. Max.-Fac. Surg. 1985; 13: 224-230.
10. Rosenstein T, Pogrel MA, Smith RA. Cystic ameloblastoma: behavior and treatment of 21 cases. J Oral Maxillofac Surg 2001; 59:1311-6.
11. Laskin DM, Giglio JA, Ferrer-Nuin LF: Multilocular lesion in the body of mandible: clinic pathologic conference Oral Maxillofac Surg 2000;60:1045-1048
12. Carlson ER, Marx RE: The Ameloblastoma: primary/ curative surgical management, J Oral Maxillofac Surg 2006; 64:484-494.
13. Sampson DE, Pogrel MA: Management of mandibular ameloblastoma: the clinical basis for a treatment algorithm J Oral Maxillofac Surg 1999;57:1074-1077.
14. Chapelle K, Stoelinga P, de Wilde P, et al: Rational approach to diagnosis and treatment of ameloblastoma and odontogenic keratocysts. Br J Oral Maxillofac Surg 2004; 42:381-390.
15. Sachs SA: Surgical excision with peripheral osteotomy definitive, yet conservative, approach to the surgical management of ameloblastoma. Oral Maxillofac Surg 2006; 64:476- 483.
16. Carlson ER, Marx RE: The ameloblastoma: primary, curative surgical management, J Oral Maxillofac Surg 2006; 64:484-494.