

## CASE REPORT

# Craniomaxillofacial Fibrous Dysplasia: Conservative Treatment or Radical Surgery? Report of Two Cases

Gayathri Goudar<sup>1</sup>, Manjunath.G.A<sup>2</sup>, Subramanya.G<sup>3</sup>, Ashoka.k<sup>4</sup>, Shwetha Kardalkar<sup>5</sup>, Jyothi Mahadesh<sup>6</sup>

## ABSTRACT

**Introduction:** Fibrous Dysplasia is a rare bone disease wherein the normal bone is replaced by fibrous tissue causing functional and aesthetic problems. They pose difficulty in diagnosis, treatment planning.

**Case Report:** We are presenting 2 cases of Fibrous Dysplasia wherein the treatment done was resection of body of mandible with reconstruction with iliac graft in the first case and a shave down procedure in the second case.

**Conclusion:** The type of surgical procedure is case dependent and requires follow up. But most cases of Fibrous Dysplasia are benign, with very less recurrence rate.

**Keywords:** Fibrous Dysplasia, mandible, radicle surgery

**How to cite this article:** Gayathri Goudar, Manjunath.G.A, Subramanya.G, Ashoka.k, Shwetha Kardalkar, Jyothi Mahadesh. Craniomaxillo facial fibrous dysplasia: conservative treatment or radical surgery?: report of two cases. International Journal of Contemporary Medical Research. 2015;2(2):292-296

<sup>1</sup> Professor and HOD, <sup>2,3,5</sup> Assistant Professor, <sup>4,6</sup> Professor, Department of Oral and Maxillofacial surgery & Dept of Oral Pathology, Sri Siddhartha Dental College and Hospital, Tumkur, India

**Corresponding author:** Dr. Gayathri Goudar, Professor and HOD, Department of Oral and Maxillofacial surgery, Sri Siddhartha Dental College and Hospital, Tumkur, India

**Source of Support:** Nil

**Conflict of Interest:** None

## INTRODUCTION

The fibro-osseous lesions of the jaws comprise a

diverse, interesting, and challenging group of conditions that pose difficulties in classification and treatment. From a clinical standpoint the FOL of the jaws may vary from the extensive and cosmetically or functionally disturbing lesions to a localized, asymptomatic lesions, detected only during a routine radiographic examination.<sup>1</sup> Dr G. Victor Boyko was one of the first surgeons to have presented a case of osteofibroma of the mandible associated with leontiasis ossea of the skull.<sup>2</sup> Leontiasis ossea term was suggested by Vichow in 1862 for bone diseases involving the upper face, this was a vague clinical term and referred to no specific type of pathology. It comprises 2.5% of all osseous and 7% of all benign bone tumors. In general they affect 1 in 4000 to 10,000 people.<sup>3</sup> FOL continues to present problems in classification, diagnosis, and management. It must be emphasized that precise diagnosis requires good clinical, radiological and histological correlation because the histological findings are almost similar for most of the FOL. A universally agreed classification for fibro-osseous jaw lesions is as follows:

### Classification of fibro-osseous lesion

1. Fibrous dysplasia
2. Reactive (dysplastic) lesions arising in the tooth bearing area. These are presumably of periodontal ligament in origin. It is divided into three types, based on their radiologic features although they seem to represent the same pathologic process
  - a. Periapical cement osseous dysplasia
  - b. focal cemento-osseous dysplasia
  - c. florid cemento-osseous dysplasia
3. Fibro-osseous neoplasms<sup>4</sup>

These are widely designated as cementifying fibroma, ossifying or cemento-ossifying fibroma.

The classification assist the surgeon in the diagnosis and treatment planning. Here we report two cases of FD of monostotic type, wherein radicular surgery was done in one patient and the other was managed conservatively.

### CASE REPORT 1

A male patient aged 20 years reported to our maxillofacial unit with the complaint of swelling in relation to lower back teeth around 3-4 years back. Patient presented with history of swelling which started as small size and gradually increased to attain the present size with no associated pain. Patient gave a history of surgery in relation to Right body of mandible 9 years back. Nothing significant was detected in medical history. Patient was moderately built and nourished. On extra oral examination facial prolife was grossly asymmetrical, Mouth opening 30-33mm, No deviation and no clicking sounds of TMJ, Lymph nodes-Not palpable.

**On palpation:** Diffuse swelling irt to left body of mandible measuring about 2 x 2.5 cms extending antero posteriorly 1cm below the angle of the mouth to the angle of mandible, superoinferiorly 2cm below the zygomatic arch to involve and extend 1cm below the lower border of the mandible. Swelling was hard in consistency and with no tenderness. Skin over swelling was normal with no local rise in temperature. On Intra oral examination, Swelling was measuring around 2.5 x 2cm, extending from 1st premolar till the ascending border of ramus with expansion of the buccal cortex with obliteration of sulcus with Carious-36 and lingually displaced-35,36, 37. On palpation, the inspection findings were confirmed. Swelling was hard in consistency with no tenderness. Mucosa over the swelling was normal. Provisional diagnosis was Fibro-osseous lesion of left body of mandible. Differential diagnosis of Ossifying fibroma, Cherubism, Chronic osteomyelitis, Paget disease, Osteosarcoma was given.

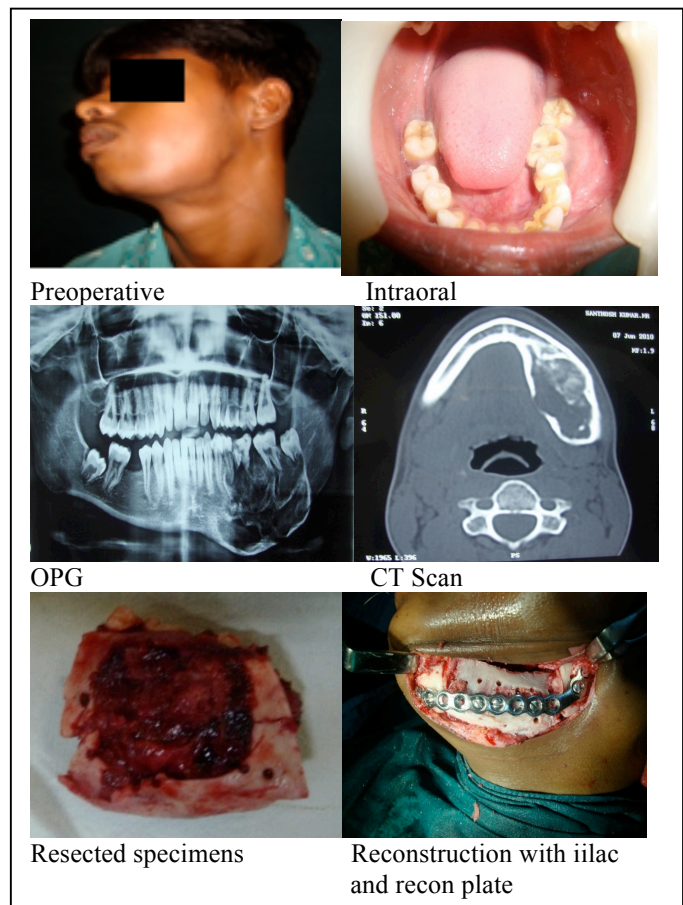
The following Investigations showed were advised Blood and biochemical investigations showed alkaline phosphate, serum calcium and serum phosphorus, which were in normal range. OPG revealed radiolucency with sparse radioopacity, giving a multicocular appearances wrt body

of mandible and lower border of the mandible expanded. Root resorption wrt 36,38.

CT Scan revealed a radioopacity interspersed with radiolucent mass extending from the premolar till the ascending ramus of the mandible, buccal and lingual cortex expanded with break in continuity of the lingual cortex at the junction of premolar and molar region.

Incisional biopsy, revealed highly cellular connective tissue stroma containing spindle shape fibroblast along with osteoid like tissues mostly not lined by osteoblasts, features suggestive of FOL.

The surgical treatment was done under G.A. Extra- oral submandibular incision placed along with intra oral degloving incision extending from canine up to molar. Using oscillating saw and



osteotome, body of mandible from lateral incisor upto the coronoid notch, was resected. Reconstruction done with iliac graft with recon-plate. Healing was uneventful, patient was on follow up for a period of 6 months. Histo pathological examination of the resected specimen showed woven type of bone with irregular

trabecular pattern scattered throughout the lesion, confirming a diagnosis of Fibrous Dysplasia, in the correlation with clinical features and radiographic findings.

## CASE REPORT 2

A male patient aged 24 years reported to our maxillofacial unit with the complaint of swelling in relation to upper right cheek region since 3-4 years, which started as a small peanut, in size and gradually increased to attain the present size with no associated pain. Medical History showed no abnormality. Patient gave a history of extraction of deciduous tooth irt right maxilla 4 years back. Patient was moderately built and nourished. On extra oral examination, there was gross facial asymmetry with mouth opening of 28-30mm and TMJ showed no deviation, no clicking sounds, Lymph nodes were not palpable. Diffuse swelling irt to right maxilla measuring about 2 x 2 cms extending about 0.5cm below the right infraorbital rim extending till the butt-ress superior inferiorly, and anterio posteriorly from the ala of the nose till the buttress region. On palpation, the swelling was hard in consistency and with no tenderness. Skin over swelling was normal with no local rise in temp. On Intra oral examination, there was a diffuse swelling extending from lateral to 1<sup>st</sup> molar with the obliteration of sulcus, measuring around 1.5x2 cms. Mucosa over the swelling was normal. On palpation the inspection findings were confirmed. Swelling was hard and non-tender in consistency. A Provisional diagnosis of Fibro-osseous lesion of right maxilla was given.

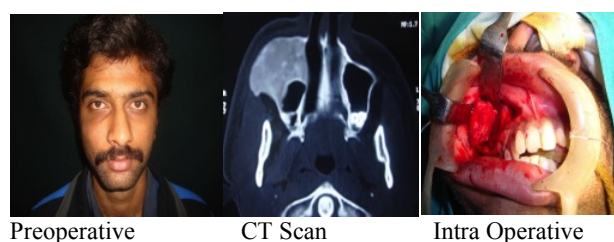
CT scan revealed expanded body lesion with ground glass appearance in right maxillary sinus (anterolateral wall) involving alveolar process and zygomatic process, features were suggestive of fibrous dysplasia.

Incisional biopsy report revealed cellular and fibrous connective stroma with plum cells intermixed with bone of varying size and shape. Under low magnification Chinese letter pattern appreciated, features were suggestive of FOL.

Surgical procedure was done under G.A, vestibular incision was given from right lateral incisor up to 2<sup>nd</sup> molar and a full thickness mucoperiosteal flap was raised to expose the

buccal cortex exposing the lesion. Osteotomy cuts were placed from canine to the first molar and the buccal cortex was removed. Bone was recontoured with flame shape tungsten carbide bur. Primary closure was done and healing was uneventful. The patient was satisfied, hence we lost the patient to follow up.

H/P examination of the resected specimen showed fibrous connective stroma with various shapes of trabecular pattern and the trabecle shows osteoblastic rim in only few areas. Osteocytes were found within the lacunae, confirming a diagnosis of Fibrous Dysplasia, with the correlation of the Clinical & radiographic features.



## DISCUSSION

Fibrous dysplasia, was first coined by Lichtenstein in 1938 as for multiple (polyostotic) bone lesions as described by Albright et al. as Osteitis fibrosa disseminata. Lichtenstein and Jaffe later expanded this lesion and isolated (monostotic) form of the disease which was considerably more common than the polyostotic form. Following Lichtenstein and Jaffe's paper, the diagnosis of Fibrous Dysplasia became very popular. Specific histologic criteria for diagnosing fibrous dysplasia is still not definitive and controversial. Most authors consider the disease to be non-neoplastic developmental (hamartomatous) lesion of bone.<sup>3</sup> FD is a disease of bone maturation and remodelling in which normal medulla and cortex are replaced by disorganised fibrous woven bone, which is more elastic and structurally weaker than normal bone. It is caused by the deletion of a bone maturation protein during embryogenesis and there is no evidence to suggest hereditary influence.<sup>5</sup> FD is of three types

1. Monostotic type: 80-85%
2. Polyostotic type:
  - a. Jaffe's type: many bones, pigmented lesions of skin (C.E.L.spots), (most of the skeleton is normal)



- b. Albright's syndrome: involving nearly all bones, Cushing's spots and endocrine disturbances

3. Craniofacial form: frontal, sphenoid, maxillary, ethmoid bones most affected, occipital and temporal less affected.<sup>4</sup>

Monostotic Fibrous Dysplasia are more common in females than males, more common in maxilla than mandible more in posteriorly placed than anterior. Commonly found to be unilateral rarely bilateral. MFD of the jaws, as defined by Waldron are seen approximately equally in males and females. Maxilla more common than mandible.<sup>3</sup> Maxillary lesions frequently involve adjacent group of bones separated by sutures (maxilla, zygoma, sphenoid, occiput) and hence are not strictly monostotic.<sup>5</sup> A painless enlargement of the involved bone is the most common presenting symptom. These are slow in onset, often the patient does not remember when the swelling first began, found during the first 2 decades of life.<sup>4</sup> FD must be differentiated from ossifying fibroma<sup>5</sup> which can be differentiated radiographically. Radiologic findings show early lesions to be more radiolucent than mature lesions. In rare cases there appears granular internal septa, giving a multi ocular appearance. The abnormal trabeculae are usually shorter, thinner, irregularly shaped, more numerous than normal. This creates a radio opacity that can vary.

1. It may have granular appearance (ground glass)
2. A pattern resembling the surface of an orange (peau-d-orange)
3. Wispy arrangement (cotton wool) or an amorphous dense pattern.

A distinctive characteristic is the organization of the abnormal trabeculae into a swirling pattern similar to a finger print.<sup>6</sup> The lesion is not radiographically well defined and it blends well into the surrounding bone. This is an important feature in differentiating FD from ossifying fibroma, which is radio graphically well defined. Maxillary lesions commonly involve the maxillary sinus so that waters views shows a radio dense area that largely or totally obliterate the maxillary sinus. Teeth in the involved area are not displaced and remains firm, root resorption is rare<sup>3,7,8</sup>

Histopathology shows irregularly shaped trabeculae of immature woven bone in a cellular fibroblastic stroma. The bone trabeculae are

delicate and not connected to one another, they assume curvilinear shapes resembling Chinese script writing. The bone trabeculae does not have osteoid rims or osteoblasts. The lesion has no definable borders, and the osseous trabeculae blend into the normal surrounding bone. They may undergo progressive maturation to a lesion consisting of lamellar bone. The bone trabeculae in the "mature" lesions tend to run parallel to one another.<sup>1,4</sup> Tiny calcified spherules maybe occasionally seen.<sup>8</sup>

Clinical management of FD, include complete resection of small lesions of the mandible. Diffuse and large lesions, especially those of the maxillary complex, requires extensive surgical procedures. In most cases, the disease tends to stabilize and stops growing when skeletal maturation is reached. Some patients with minimal cosmetic or functional deformity may not require surgical treatment. However, cosmetic deformity, associated with psychological problems or functional deformity, may require surgical intervention in the younger. It is estimated that between 25% and 50% of patients will show some regrowth after surgery, which is more common in younger patients suggesting that surgical intervention should be delayed till maturity. Malignant changes in FD, usually into an osteosarcoma, has been rarely reported. Radiation therapy for FD is definitely contraindicated as it carries the risk of post irradiation bone sarcoma. All the patient should be kept under long term follow up and any patients showing clinical or radiologic evidence of changes should be subjected to adequate biopsy to rule out sarcomatous change.<sup>4</sup>

Valentini V et al<sup>9</sup> has done a retrospective study on 68 patients diagnosed with CFD, he has done radical excision on 61 patients and six received conservative treatment. He advocated an aggressive surgical treatment with a good functional and esthetic result in most cases of monostotic type and even advocated radical treatment in cases involving maxilla and mandible and preferred a conservative approach in polyostotic cases and McCune Albright syndrome. Thus posing a question of conservative or radical surgery.<sup>9</sup>

In a study by A Kruse et al<sup>10</sup> on CFD: A 10 year database 1996-2006, he treated 8 pts with a monostotic form He concluded that FD should be

treated as conservatively as possible but in cases of functional disturbance that result from malignant transformation, or from the involvement of the optic foramen or the foramen magnum, an immediate operation is needed. Disfigurement can be another reason for operation.<sup>10</sup> J C Posnick reported 5 cases of CFD<sup>11</sup> where radical surgical procedures with reconstruction was done.

## CONCLUSION

The purpose of classification is to assist the surgeon to achieve a proper diagnosis that can transform into a good treatment planning. We can conclude that with the advancement of refined instrumentation and cranofacial surgical technique, a more aggressive, non-disabling approach is possible, especially in monostotic forms, but in polyostotic and McCune-Albright syndrome, a more conservative approach is preferred. Lifelong continuous monitoring of the involved region is required throughout the patient's life.

## REFERENCES

1. Waldron CA, Fibro-osseous lesions of the jaws, J Oral Maxillofac Surg 1985;43:249-262,.
2. Boyko GV ; J Oral Surg 1:100,1943.
3. Suneedh Gupta,K.Umesh,N.M.Warad and Shakeel Ahmed ,Fibrous dysplasia of maxillary bone: A case report ;Al J Med Sci 2011; 4:92-97
4. Waldron CA. Fibro-osseous lesions of the jaws. J Oral Maxillofac Surg 51:828-835,1993.
5. Robert E Marx ,Diane Stern,,Oral and Maxillofacial Pathology;2003Quintessence Publishing Co,Inc
6. Abdel Karim, Green.R,Preece. J. Craniofacial Polyostotic fibrous dysplasia: a case report & review of literature, O.Surg.,O Med.,O. Patho..Radio. Endo;2008;106:e49-e55.
7. D.S MacDonald-Jankowski; Fibro-osseous lesions of the face and jaws;Clinical radiology(2004)59,11-25.
8. Oral and Maxillofacial Surgery: Clinics of North America, Vol 9 Number 4, NOV 1997
9. Valentini.V, Cassoni.A, Marianetti TM, Terenzi, FaddaMT, Iannetti G Cranio maxillofacial fibrous dysplasia:conservative treatment or radical surgery ?A retrospective study on 68 patients.,Plastic Reconstr Surg.2009;123:653-60
10. AKruse,U.Pieles,M.O.Riener,Ch.Zunker,M. G.Bredell,K.W.Gratz; Craniomaxillofacial fibrous dysplasia: A 10 year database 1996-2006.British J Of Oral and Maxillofacial Surgery 47;3: 302-305.
11. J C Posnick. Fibrous dysplasia of the craniomaxillofacial region: current clinical perspectives.British J Of Oral and Maxillofacial Surgery 1998;36: 264-273.
12. A.S. Godse, S.P.Shrotriya, N.S.Vaid, Fibrous dysplasia of maxilla;Journal of Pediatric Surgery 2009;44:849-851.