

## CASE REPORT

# Crouzons Syndrome With Multiple Impacted Permanent Teeth - A Case Report

Saraswathi Gopal.K<sup>1</sup>, Madhubala.E<sup>2</sup>

## ABSTRACT

**Introduction:** Crouzon syndrome (CS) is a rare genetic disorder contributing to approximately 4.5% of all cases of craniofacial dysostosis. Craniofacial dysostosis is a cumulative term designated for a variety of skull deformities that arise due to developmental defects in the primitive mesoderm, leading to premature synostosis of the suture lines in the base of the skull and the vault. CS though inherited as an autosomal dominant trait, many cases of sporadic de novo mutations are reported arising from phenotypically normal parents. Incidence of this syndrome is approximately 15-16 per one million new borns.

**Case Report:** This article describes a case of a 27-year-old male whose history, clinical features and radiological features correlated with that of a classic Crouzon syndrome. Apart from the classic presentation this patient also had an expression of multiple impacted permanent teeth, which makes this case distinct.

**Conclusion:** Crouzon syndrome presents with various signs and symptoms which can be functionally and psychologically traumatic to the affected and to their families. Prenatal diagnosis and genetic counselling have a pivotal role in early diagnosis and prevention of this syndrome

**Keywords:** Craniosynostosis, FGFR gene, skull deformities, hypoplasia.

**How to cite this article:** Saraswathi Gopal.K, Madhubala.E. Crouzons Syndrome With Multiple Impacted Permanent Teeth- A Case Report. International Journal Of Contemporary Medical Research. 2015;2(2):Pp

<sup>1</sup>Professor and HOD, <sup>2</sup>Post Graduate Trainee, Oral Medicine And Radiology, Meenakshiammal Dental College And Hospital, Chennai

**Corresponding Author:** Dr.Madhubala, 15/16, "Rajkala", Ganpathraj Nagar, Virugambakkam, Chennai-600092

**Conflict of Interest:** None

## INTRODUCTION

The term Craniosynostosis is described as premature fusion of one or more cranial sutures. Craniosynostosis can be either isolated or can occur in association with a craniodystopic syndrome.<sup>1</sup> The craniosynostosis types are given in Table-1. Premature fusion of one or more of the cranial sutures disrupts growth along the peripheries and excessive growth at other sutures leads to skull distortion. Virchow demonstrated in 1851 that, after premature suture closure, growth proceeds parallel to the suture and is inhibited perpendicular to it (Virchow's law)<sup>2</sup>. Abnormal skull growth can lead to an increase in the intracranial pressure, impairment in the circulation of blood, airway obstruction causing breathing difficulties and when foraminal obliteration is involved it may lead to optic and auditory deficits. The affected may also have learning difficulties and adverse psychological effects.<sup>3</sup> The pathogenesis behind craniosynostosis can be traced to both contributory Genetic factors and environmental factors.<sup>4</sup> Over 180 syndromes associated with craniosynostosis have been reported most of the common ones exhibit dominant inheritance.<sup>4</sup> In syndromic cases the sutures at the skull base are also affected leading in more complications, affecting facial as well as skull development.<sup>5</sup> Craniosynostosis syndromes commonly encountered are Crouzon, Pfeiffer, Apert, Saethre-Chotzen and craniofrontonasal syndromes<sup>6</sup> and of these the first three syndromes share similar facial features. In Crouzon syndrome the limbs are not affected. Pfeiffer syndrome cases have a characteristic presentation of broad big toes and sometimes the thumbs with occasional mild skin webbing between other digits. Apert syndrome can be

differentiated from Crouzon's by the fact that fusion of at least the central three digits is seen also involving the underlying bone and the overlying skin.<sup>7</sup> French neurosurgeon Octave Crouzon was the first to describe Crouzon's syndrome in 1912. It is expressed in an autosomal dominant trait with 100% penetrance, however the expressivity is variable.<sup>8</sup> The genetic defect responsible for this syndrome is attributed to a mutation in the fibroblast growth factor receptor2 (FGFR2).<sup>9</sup> These sutural synostoses contribute to the premature fusion of skull base leading to shallow orbit, midfacial hypoplasia, maxillary hypoplasia and occasional upper airway obstruction. It is a comparatively rare genetic disorder and occurs in approximately 1 in 25,000 births worldwide.<sup>10</sup> This case report presents a man of 26 years with Crouzon's syndrome and an associated unusual presentation of multiple impacted permanent teeth.

## CASE REPORT

A 26 year old male patient reported with complaint of missing teeth in his upper and lower front jaw region for past 12 years. History revealed failure of eruption of permanent teeth after exfoliation of deciduous teeth and the patient experienced associated difficulty in mastication and speech. Patient's medical history revealed that he was a known epileptic with the last episode of seizures occurring approximately 1 year ago. Patient also had learning disabilities due to which he discontinued his studies. Family History revealed that Patient's parents were phenotypically normal and had a non consanguineous marriage. Patient had 2 siblings who were apparently normal. General examination revealed that even though conscious, co-operative, patient was only moderately oriented to time and place and responded to questions behindhand. He was of a Short Stature and showed Lumbar lordosis and a waddling gait. Facial Deformities that were evident were a high and large forehead with a pronounced convexity in the region of the anterior fontanelle, parrot beak appearance of nose, bilateral ocular proptosis, hypertelorism, divergent strabismus and low set ears.(Figure 1). Patient also had visual acuity problems, slurred speech with mild

hearing loss in left ear. Extra Oral examination revealed a concave profile with mid face deficiency due to a hypoplastic maxilla and relative mandibular prognathism. Intra oral examination revealed partial anodontia with only 16 teeth present clinically, inclusive of retained deciduous 83 and partially erupted 14, 17, 35.(Figure 2 ) OPG revealed presence of 35 teeth, with 11, 12, 13, 18, 21, 22, 23, 28, 31, 32, 33, 74, 75, 38, 41, 42, 43, and 48 being impacted within the alveolar bone. The roots of the impacted 38 and 48 were stunted. Hypoplasia of the maxillary sinus was evident. OPG also showed a shallow sigmoid notch and prominent ante-gonial angle (Figure3). Skull PA and Lateral Views reveal a depressed anterior fontanelle more appreciable on the PA view and convolution marking/ "paw marking" of the skull due to the gyri of the brain indenting and thinning the calvaria. Incomplete fusion of the sagittal suture was evident with discontinuity in the outline of the skull traced at the junction of the saggital suture. Shallow orbits were evident. Widening of the diploic space was seen in the occipital region. (Figure4) Maxillomandibular CBCT revealed hypoplasia of maxillary sinus, nasal septal deviation towards right side, decreased airway space, multiple impacted permanent and few deciduous teeth in the maxillary and mandibular arches, prognathic mandible and low set ears. Based on the clinical and radiographic findings we arrived at a final diagnosis of Crouzon's syndrome with an unusual expression of multiple impacted permanent and deciduous teeth. Further genetic studies could not be carried out in this patient due to non-compliance.

## DISCUSSION

Crouzons syndrome shows an autosomal dominant pattern of inheritance. Sporadic cases with an equal incidence have also been reported which may be attributed to probably new mutations. Various hypotheses by investigators postulate the association of these sporadic cases with advanced paternal age and that this mutation is more frequent in the sperm of older men.<sup>11</sup> This fact correlated with the present case with the age of the father during the patient's birth being 42. The constitutional morphological features of

Types of Craniosynostosis	
Isolated	Fusion of a single suture
Compound	Premature fusion of multiple cranial sutures
Syndromic	Typically involves premature fusion of multiple sutures and are hereditary forms of craniosynostosis with extracranial features

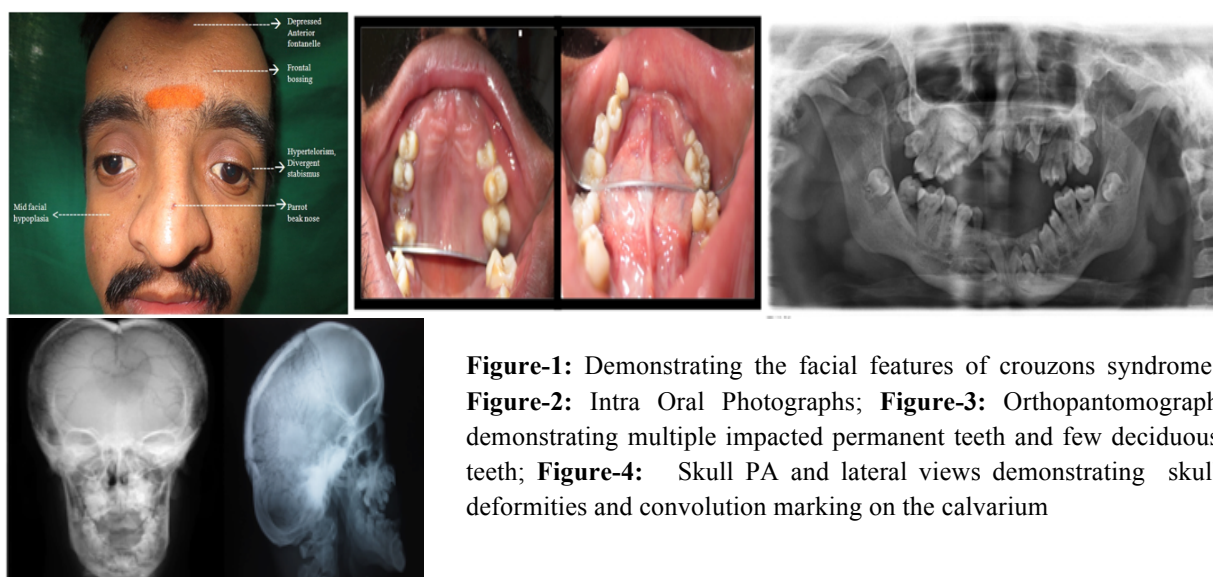
**Table-1:** Types of Craniosynostosis

Cranium	Craniosynostosis, Frontal bossing Depressed anterior fontanelle
Eye	Exophthalmos, Ptosis, Hypertelorism, Divergent strabismus
Ear	Low set ear Conductive hearing loss
Nose and Paranasal sinus	Beaked nose Deviated nasal septum
Facial Features	Maxillary Hypoplasia Malar deficiency Relative mandibular prognathism
Neurological	Headache Seizures

**Table-2:** Classic features of crouzons that correlated in our case

Crouzons Syndrome may not be present at birth and may gradually develop during the early childhood. The severity of expression of the cranial and facial malformations is proportional to the order and rate of progression of sutural synostosis which, in Crouzons commonly involves the sagittal and coronal suture. Predominance of craniosynostosis of the sagittal suture is noted in boys, while the coronal suture is involved more commonly in girls.<sup>12</sup> Our case also correlates to this fact with the sagittal suture being predominantly affected. Skull deformity is the prime clinical feature of Crouzons Syndrome and may range from brachycephaly to a boat-shaped head (scaphocephaly), a tower shaped skull (Oxycephaly/ Turricephaly), a flat skull (plagiocephaly), triangle-shaped head (trigonocephaly) or in severe disease cloverleaf skull (kleeblattschädel) like deformity.<sup>13</sup> In the present case the skull radiographs depicted a pear shaped deformity. Due to foraminal obliteration in the skull, reported history of seizures in our patient correlates with the features of this syndrome. Radiological examination performed using conventional views of the skull show premature suture closure and provides information about maxillomandibular relation. 'Paw marking' of the

skull is seen due to raised intracranial pressure.<sup>14</sup> Only when there is premature closure of the cranial suture lines which contributes to impairment of brain development due to increased intracranial pressure an extreme consequence of mental retardation may occur. However in our case mental ability and psychomotor development were within normal limits except for learning disabilities and his delayed, non-synchronous responses. Depressed anterior fontanelle, frontal bossing which are pathognomonic of Crouzons syndrome were also evident in our present case. The facial features of hypoplastic maxilla and zygoma, psittichorhina/ parrot beak-like nose due to the short and narrow maxilla are also classic features which were expressed in our case. Some cases present with narrow high-arched palate or cleft palate and in a few patients crowding of teeth as well as posterior crossbite and reverse overjet with anterior open bite and relative mandibular prognathism are usual findings. However as a rarity our case presented with multiple impacted permanent teeth and few deciduous teeth. Nearly one-third of affected patients suffer from auditory deficits which could be attributed to middle ear deformities due to pronounced midfacial hypoplasia. Our case had a similar presentation with hearing difficulties in left ear. 30 to 80% patients frequently present with Optic atrophy exhibiting ocular malformations including hypertelorism, proptosis due to the shallow orbits. Our case had above mentioned features along with divergent strabismus and associated loss of visual acuity. A summary of all the clinically positive finding for Crouzons Syndrome seen in our patient is enlisted in Table-2. Preventive protocol for couples at risk for having a child with crouzons syndrome includes prenatal diagnostic testing for FGFR gene mutation. Prenatal ultrasonic diagnosis of exophthalmos aids as a clue to the assimilating deformities and if diagnosed prenatally, at birth or shortly after birth, then nonsurgical intervention such as PD173074 a drug, (apyrido-[2, 3-d] pyrimidine, which is a selective FGFR tyrosine kinase inhibitor) may be used in future to curb the growth abnormalities seen with the syndrome and to limit the complexity of surgical intervention.



**Figure-1:** Demonstrating the facial features of crouzons syndrome; **Figure-2:** Intra Oral Photographs; **Figure-3:** Orthopantomograph demonstrating multiple impacted permanent teeth and few deciduous teeth; **Figure-4:** Skull PA and lateral views demonstrating skull deformities and convolution marking on the calvarium

Management calls for an early multidisciplinary approach with the surgical treatment beginning as early as 3-6 months of age of the child attempting to release bony ankylosis to avoid gross consequences leading to impaired brain development<sup>15</sup> Craniofacial reconstructive surgery including advancement of the maxilla and frontonasal complex; and other surgeries like rhinoplasty, oculoplasty can be done later in life. The ultimate treatment motive is to phase reconstruction so as to coincide with the facial and psychosocial growth patterns hence making early and accurate diagnosis of Crouzon syndrome essential. In our case, complex treatment plan involving a multidisciplinary therapeutic and cosmetic approach was formulated for the patient and is under execution.

## CONCLUSION

Tremendous advances in identifying the inheritance mode, preventive measures and early therapeutic measures are yet to make an impact with Crouzon's syndrome still remaining a significant cause of morbidity at a global level. Healthcare professionals should constantly revise their knowledge of syndromes associated with dysmorphic faces and also update themselves to identify undiagnosed cases, so that the needy may be identified and addressed with early investigation and management as required to

prevent complications due to late diagnosis.

## REFERENCES

1. Doorenbosch X, Campbell J, Umaphysivam K. Risk factors for developing recurrent raised intracranial pressure post cranial vault remodelling in nonsyndromic craniosynostosis in children: a systematic review protocol. *The JBI Database of Systematic Reviews and Implementation Reports*, 2013;11:54 - 63
2. Delashaw JB, Persing JA, Jane JA. Cranial deformation in craniosynostosis. A new explanation. *Neurosurg Clin N Am*. 1991; 2:611-20.
3. Wilkie A.O. Craniosynostosis—genes and mechanisms. *Hum. Mol. Genet*. 1997; 6:1647–1656
4. SA Boyadjiev. Genetic analysis of non-syndromic craniosynostosis; *Orthod Craniofacial Res* 2007;10:129–137
5. Headlines - The Craniofacial Support Group, October 2002 ;1 – 8
6. Agochukwu NB, Solomon BD, Muenke M. Impact of genetics on the diagnosis and clinical management of syndromic craniosynostoses, *Childs Nerv Syst*. 2012; 28:1447–1463.
7. Robin NH, Falk MJ, Haldeman-Englert, C.R. FGFR-related craniosynostosis syndromes. *GeneReviews* [online] University of Washington, Seattle



8. Padmanabhan V, Hegde AM, Rai K. Crouzon's syndrome: A review of literature and case report. *Contemporary Clinical Dentistry* 2011; 2:211-214. .
9. Silva DL, Neto FX, Carneiro SG, Palheta AC, Monteiro M, Cunha SC et al. Crouzon's Syndrome: Literature Review. *Intl Arch Otorhinolaryngol* 2008;12: 436-41
10. Gopikishan S, Meena D K, GulatiR.K; Crouzon's Syndrome: A Case Report; *Paripex - Indian Journal Of Research* 2014; 3:4-7
11. Glaser RL, Jiang W, Boyadjiev SA, Tran AK, Zachary AA, Van Maldergem L, Johnson D, Oldridge M, Wall SA, et al. Paternal origin of FGFR2 mutations in sporadic cases of Crouzon syndrome and Pfeiffer syndrome. *Am J Hum Genet* 2000;66:768-777
12. Carinci F, Pezzetti F, Locci P, et al. Apert and Crouzon Syndromes: Clinical Findings, Genes and Extracellular Matrix. *J Craniofac Surg.* 2005, 3:361-6;.
13. Khanna PC, Thapa MM, Iyer RS, Prasad SS. Pictorial essay: The many faces of craniosynostosis. *Indian J Radiol Imaging.* 2011;21:49-56..
14. Vinayak R, Ritvij P, Mayank V, Akshay P, Abhishek M, Vaibhav G, Tejas C. Crouzon Syndrome: A Case Report. . *IJHSR.* 2015; 5: 428-431.
15. Kasat VO, Saluja H, Baldawa R, Ladda R. Crouzon syndrome: A case report and review of literature. *J Cranio Max Dis* 2014;3:56-60