

REVIEW ARTICLE

Diagnostic Algorithm For Detection of Cysts of Oro-Facial Region

Prakriti Dayal¹, Junaid Ahmed², Nandita Shenoy³, Ravikiran Ongole⁴, Aureus Dsouza¹

ABSTRACT

The first step towards diagnosing cysts is a thorough history and physical examination. Certain cysts have a specific age, gender and site predilection and some have a tendency for recurrence. Some cysts can occur after trauma (ex- trauma to minor salivary glands in the oral cavity can lead to the formation of a mucocele), and some patients may give a history of previous extractions and impacted teeth (thus pointing to a diagnosis of primordial or dentigerous cyst). Thus a thorough history can go a long way in excluding other cyst-like lesions which can present in the oral cavity. A diagnostic algorithm would help in enlisting various cysts which present specific appearances, either on clinical, chair-side or radiographic investigation. This review was an attempt at classifying cysts on the basis of all the above, as a means of establishing diagnostic clarity in clinical practices.

Keywords: Cyst, diagnosis, Radiographic interpretation

How to cite this article: Prakriti Dayal, Junaid Ahmed, Nandita Shenoy, Ravikiran Ongole, Aureus Dsouza. Diagnostic Algorithm For Detection of Cysts of Oro-Facial Region. International Journal of Contemporary Medical Research. 2015;2(2):323-326

¹Post Graduate, ²Professor and Head, ³Associate Professor, ⁴Professor, Department of Oral Medicine and Radiology, Manipal College of Dental sciences, Mangalore-575001. Affiliated to Manipal University

Corresponding author: Dr. Junaid Ahmed, Professor and Head, Department of Oral Medicine and Radiology, Manipal College of Dental sciences,

Source of Support: Nil

Conflict of Interest: None

INTRODUCTION

Cysts of the jaws and maxillofacial region were

recognized long before the discovery of x-rays in 1895. John Hunter, the noted anatomist, published a monograph in 1774 that seemed to describe a patient with an infected maxillary cyst¹. The association of cysts with teeth was popularized by Fauchard and they have been extensively recorded in literature since then¹. Kramer, in 1974, defined a cyst as ‘a pathological cavity having fluid, semifluid or gaseous contents and which is not created by the accumulation of pus’.² Most cysts, but not all, are lined by epithelium. According to Merwyn Shear, cysts of the oro-facial region may be seen associated with the jaws, maxillary antrum and those in the soft tissues of the head and neck.³

Cysts and cyst-like lesions are commonly encountered in the dental practice. Patients may present with a blizzard of symptoms which may be confounding to the clinician. Most of them are asymptomatic and are incidental findings during a routine radiography. A thorough knowledge of the various cysts and cyst-like lesions that may present in the oral cavity is mandatory. Understanding the pathogenesis, clinical and radiographic features and differentiating them from lesions with similar appearances is of utmost importance in deciding the course of treatment for the particular lesion.

The various approaches and clues to diagnosis are described below, which can help oral diagnosticians plan a holistic treatment plan.

APPROACH TO DIAGNOSIS

The first step towards diagnosing cysts is a thorough history and physical examination. Certain cysts have a specific age, gender and site predilection and some have a tendency for recurrence. Some cysts can occur after trauma (ex- trauma to minor salivary glands in the oral cavity can lead to the formation of a mucocele), and some patients may give a history of previous

extractions and impacted teeth (thus pointing to a diagnosis of primordial or dentigerous cyst). Thus a thorough history can go a long way in excluding other cyst-like lesions which can present in the oral cavity. For example, patients with Mucous retention cyst or mucocele in the maxillary sinus may present with obliteration or haziness of the maxillary sinus, thus radiographically mimicking chronic maxillary sinusitis, which should be ruled out by history of recurrent rhinitis, post-nasal drip and heaviness of head.

Physical examination of cysts may reveal a non-specific swelling, which may be asymptomatic or present with pain due to secondary infection or pressure effect. Various investigations such as FNAC and radiographs may reveal additional information to aid in the diagnosis. In most cases, biopsy alongwith correlation of the clinical/radiographic clues leads to a definitive diagnosis.

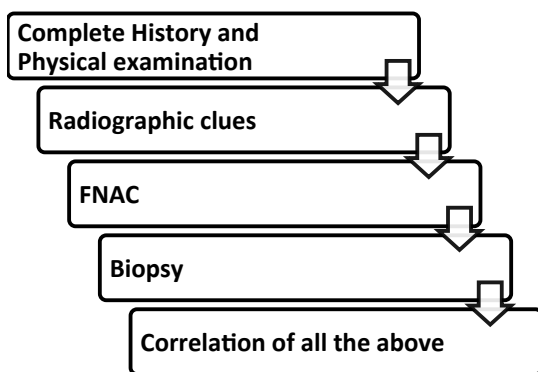


Figure-1: Flowchart for approach to diagnosis

Initiation of cyst formation due to various factors results in the proliferation of the epithelial cells and the formation of small cavity. The odontogenic remnants which cause initiation are: Cell Rests of Malassez, Reduced Enamel Epithelium, Cell Rests of Serres (Dental Lamina).

Diagnostic clues can be based on various parameters:

- Based on clinical features
 - Gender predilection
 - Age group predilection
- Based on site predominance
- Based on aspirate fluid
- Based on radiographic features
- Based on histologic features

Based on clinical features of cysts

- Small cysts are usually symptomatic
- Large cysts exhibit huge swelling and pain, and associated abnormalities in teeth such as missing tooth, impacted tooth, supernumerary tooth, displacement of tooth, non-vital tooth, carious tooth, etc.
- Presence of fluctuation in the swelling upon palpation
- Condition of the bone plate-bulging and thinning over the outer cortical bone plate

Gender predilection

Females	Males
Nasolabial cyst	Dentigerous cysts
Aneurysmal Bone cyst	Odontogenic Keratocyst
Post operative maxillary cyst	Glandular Odontogenic cyst
Mucous retention cysts	Nasopalatine Duct cyst
	Solitary Bone cyst

Age group predilection:

Seen predominantly in children are:

- Eruption cyst
- Gingival cyst of infants
- Mid-palatine raphe cyst of infants
- Juvenile paradental cyst

The other cysts of the jaws and maxillary antrum do not show any specific age group predilection. They can be seen in a wide age group.

Based on anatomical site of the jaws:

Maxilla

- Maxillary impacted 3rd molar region
 - Dentigerous cyst
- Maxillary impacted canine region
 - Dentigerous cyst
- Maxillary anteriors
 - Radicular cyst
 - Calcifying odontogenic cyst
 - Lateral periodontal cyst
- Maxillary ridge
 - Gingival cyst of infants

Mandible-

Angle of the mandible, Ascending ramus of mandible:

•Odontogenic Keratocyst

3rd molar region:

•Dentigerous Cyst

•Paradental Cyst

1st / 2nd molar region

•Buccal bifurcation cyst

Premolar region

•Lateral Periodontal cyst

•Gingival cyst of adult

Canine to molar region

•Aneurysmal Bone cyst

•Stafne Bone cyst

•Solitary Bone cyst

•Odontogenic keratocyst

Mandibular anteriors

•Eruption cyst

•Glandular odontogenic cyst

Chairside investigations:

- Vitality test
- Aspiration
- Biopsy

Vitality Assessment:**Non-vitality of teeth due to cyst:**

- Radicular cyst

Based On Aspiration:

- Pale or Straw coloured fluid, rich in cholesterol crystals:
Dentigerous cyst, Radicular cyst, Periodontal cyst
- Creamy, cheese like material:
Odontogenic Keratocyst
- Yellowish discharge:
Infected cysts (pus filled)
Calcifying odontogenic cysts (viscous, granular material)
- Blood tinged fluid
Aneurysmal Bone cyst
- Air on aspiration
Maxillary sinus, Traumatic Bone Cyst
- Negative aspiration
Solid tumour mass

Radiographic Diagnosis

Radiographs are quintessential in establishing a

diagnosis by excluding other cyst-like lesions that may occur in the jaws. Various radiographic modalities can provide different diagnostic clues of different areas of interest helping in narrowing the spectrum of differential diagnosis to be considered.

- **Intra-Oral Periapical Radiography:** For small peri-apical cysts to see the teeth involved, to evaluate vitality as well as extent of smaller cysts.
- **Occlusal Radiography:** To check the cortical plate expansion/perforation
- **Orthopantomogram:** Recommended in most cases. The entire extent, size etc. can be assessed
- **PNS:** To show relation to maxillary antrum and nasal cavity
- **Lateral Oblique (Mandible):** To check proximity to lower border
- **PA view:** To check expansion of the ramus of mandible
- **CT scan:** For a complete assessment of extent and expansion
- **CBCT scans:** Was found to be superior to conventional CT in detecting cortical bone involvement and delineating the mandibular canal⁴
- **Other non-ionizing modes of investigation:**
 - **MRI :** Proximity to other soft tissues and perforation
 - **Ultrasonography:** For cysts of the soft tissues of head and neck region

Radiographic Assessment parameters

- Location
 - The epicentre of a cyst is the geographic centre of the lesion. Smaller cysts may be assumed to have equal growth in all directions.
- Odontogenic cysts are typically located superior to the inferior alveolar nerve canal within the mandible and may have a pericoronal position relative to an impacted tooth.
- When in the maxilla, odontogenic cysts usually present with a cortical boundary between the cyst and the internal structure of the sinus, which indicates an origin outside the sinus, and can thus be differentiated from cysts intrinsic to the maxillary sinus.

- Border

Well-defined, ill-defined or a corticated border characterized by a thin radiopaque line.

In case of secondary infection, this border may become thicker, sclerotic or ill-defined.⁵

- Shape

Most cysts can be identified by their external shape which is generally spherical (in cross-section), circular or oval. (For example, Nasopalatine cysts can take the form of round, oval, inverted-pear shaped, or heart shaped radiolucencies; Nasolabial cysts are generally circular or oval lesions, but in postero-anterior views on MRI may be seen as kidney-shaped or spherical lesions)⁵

The rounded shape generally indicates their fluid filled state. This rounded aspect is lost if the cyst has decompressed and collapses.

Scalloped outlines analogous to a series of contiguous arcs may be seen (as seen in solitary bone cyst)⁵

- Internal Structure

Most cysts have a radiolucent center.

Presence of internal septa may create a multilocular appearance. (For example, OKCs or cystic ameloblastomas)

Cysts may also develop ill-defined internal dystrophic calcifications. (For example, calcifying epithelial odontogenic cyst)

- Effect on surrounding structures

Slow growing, displaces roots of adjacent teeth (example, Dentigerous cyst)

Displaces canal or sinus floor (example, Odontogenic keratocyst, dentigerous cyst)

Radiographic appearances of common cysts

UNILOCULAR LESIONS	MULTILOCULAR LESIONS
<ul style="list-style-type: none"> • Inflammatory paradental cyst • Dentigerous cyst • Odontogenic keratocyst • Periapical cyst • Solitary Bone cyst • Incisive canal cyst • Lateral periodontal cyst • Residual cyst • Gingival cyst • Stafne bone cyst • Post-surgical maxillary cyst 	<ul style="list-style-type: none"> • Odontogenic keratocyst • Botryoid odontogenic cyst • Glandular odontogenic cyst • Aneurysmal bone cyst

Based on tissue of origin-cysts can be classified as:

- Cell rests of Malassez
 - Radicular cyst

- Residual cyst
- Reduced enamel epithelium
 - Dentigerous cyst
 - Eruption cyst
 - Paradental cyst
 - Calcifying odontogenic cyst
- Rests of Serrae
 - Odontogenic keratocyst
 - Lateral periodontal cyst
 - Gingival cyst of adult and newborn
 - Glandular odontogenic cyst

CONCLUSION

Cysts are routinely discovered in clinical dental practice. Understanding the pathogenesis, clinical and radiographic features and differentiating them from lesions with similar appearances is of utmost importance in deciding the course of treatment for the particular lesion

This review was an attempt at classifying cysts on the basis of all the above, as a means of establishing diagnostic clarity in clinical practices. A holistic approach should be followed in managing these lesions appropriately, and the patients should be put on regular follow-up to avoid chances of recurrences and discomfort to the patient.

REFERENCES

1. Toller P. Origin and growth of cysts of the jaws. *Ann R Coll Surg Engl.* 1967 May; 40: 306–336.
2. Kramer I.R.H. Changing views on oral disease. *Proceedings of the Royal Society of Medicine.* 1974;67, 271–276.
3. Shear M, Speight P. *Cysts of the Oral and Maxillofacial Regions (Fourth edition).* Blackwell Publishing Ltd, 2007
4. Stoetzer M, Nickel F, Rana M, Lemound J, Wenzel D, von See C et al. Advances in assessing the volume of odontogenic cysts and tumors in the mandible: a retrospective clinical trial. *Head & Face Medicine* 2013, 9:14
5. Bharatha A, Pharoah MJ, Lee L, Tay KY, Keller A, Eugene Y. *Pictorial Essay: Cysts and Cyst-like Lesions of the Jaws.* Canadian Association of Radiologists Journal 2010;61:133-143