

CASE REPORT

Direct Posterior Restorations Using Fibre Reinforced Composites: An Alternative To Conventional Composite Resins

Renita Soares¹, Ida de Noronha de Ataíde², Marina Fernandes³, Rajan Lambor³

ABSTRACT

Introduction: Fibre-reinforced composites (FRC) are designed to replace dentin, and thereby enable biomimetic restoration of teeth. Besides improving the strength of the restoration, incorporation of glass fibres into composite resins leads to favourable fracture patterns, improved fracture toughness and control over polymerization shrinkage by virtue of the randomly oriented fibres.

Case report: The following two case reports describe the reconstruction of molars with compromised cusps and marginal ridge using a combination of bulk short fibre reinforced composite as a substructure and surface layer of nanofiller composite.

Conclusion: This technique presents a conservative and time saving approach towards rehabilitation of molars in stress bearing areas precluding the use of expensive indirect restorations.

Keywords: Fibre reinforced composites, composite resin, posterior restorations, fracture

How to cite this article: Renita Soares, Ida de Noronha de Ataíde, Marina Fernandes, Rajan Lambor. Direct Posterior Restorations Using Fibre Reinforced Composites: An Alternative To Conventional Composite Resins. International Journal of Contemporary Medical Research. 2015;2(2):262-265

¹Post graduate student, ²Professor and Head, ³Assistant Professor, Department of Conservative dentistry and Endodontics, Goa Dental College and Hospital, Goa, India

Corresponding author: Dr. Renita Soares, Department of Conservative dentistry and Endodontics, Goa Dental College and Hospital, Goa, India

Source of Support: Nil

Conflict of Interest: None

INTRODUCTION

A variety of techniques are currently available at our disposal to restore teeth with moderate coronal defects in the posterior region which include direct complex restorations and indirect restoration such as inlays and onlays.¹

Direct restorations have been largely utilised for the restoration of posterior teeth due to their low cost and acceptable clinical performance, when compared to indirect traditional cast gold and ceramic restorations.²

Despite the fact that both amalgam and composite resins are considered suitable materials for restoring large cavities, the improved performance of composite resins, the adhesive properties along with the increasing demand for esthetic perfection have encouraged clinicians to select resin based composites as an alternative to silver amalgam.^{2,3,4}

A number of clinical reports in the literature have discussed the durability of these restorations over long periods.⁵

Even though acceptable survival rates are achieved with direct posterior restorations, the replacement of failing restorations is still a relevant issue.²

Opdam et al. revealed that vital teeth with incomplete fractures can be treated successfully by replacing the amalgam fillings with bonded composite restorations.⁶

However, undesirable properties such as the relatively high brittleness, polymerization shrinkage and low load-bearing capacity of current particulate filler composites (PFC's) have resulted in limited success and still hinder their use in large stress-bearing areas.^{1,5} Demarco et al. cited fracture and secondary caries as the main reasons for their failure.²

In recent year's fibre reinforcement has been introduced to address these deficiencies. The fibre reinforced composite has shown to possess adequate flexural modulus and strength to function successfully in the mouth.^{7,8}

Short Fibre Reinforced Composite (FRC) has been introduced as a restorative composite resin. It consists of a combination of a resin matrix, randomly oriented E-glass fibres and inorganic particulate fillers.⁵

The following case reports aim to highlight the application of fibre reinforced composite resin as an alternative to conventional composites and indirect restorations for the reconstruction of posterior teeth with extensive caries and compromised cusps.

CASE PRESENTATION

Case 1

A 35 year old male patient presented to the Dept. of Conservative Dentistry and Endodontics with occasional pain on food lodgement and sensitivity in relation to mandibular left second molar. Upon clinical examination a large carious lesion involving the buccal surface and the cusps was noted (Fig-1). Radiographic analysis revealed carious lesion extending into the dentin closely approximating the pulp (Fig-2).

Vitality testing was carried out and the patient responded positively. Based upon the findings of the history, clinical, radiographic examination and auxiliary aids an appropriate treatment plan was chalked out taking into consideration the patients economic status as well. A minimally invasive technique utilising fibre reinforced composite restoration was planned.

Rubber dam isolation was done and caries excavation was carried out until a sound dentin base was obtained. Considering the amount of remaining dentin thickness and its proximity to the underlying pulp, it was proposed to place a biomimetic material as an indirect pulp capping agent. Biodentine (Septodont, France) was mixed as per manufacturer's instructions and a 2 mm thick layer was placed on the floor of the prepared cavity (Fig 3).

In order to reinforce the remaining tooth structure, it was elected to restore the tooth using

short fibre reinforced composite as a substructure. EverX Posterior (GC, America) was the material that was chosen for the procedure. After the setting of the biodentine, the adhesive protocol was followed and the FRC was extruded from the compoule and compacted into the cavity incrementally. Each increment was light cured for 20 seconds. The overlying 2mm of the occlusal surface was reconstructed using nanofiller composite (CeramX duo, Dentsply). Finishing and polishing of the restoration was carried out subsequently (Fig 4).

The patient was periodically evaluated at 6 months and 1 year interval. At the one year follow up the tooth was asymptomatic with good marginal integrity, anatomical form and absence of fractures, secondary caries and discoloration (Fig 5).

Case 2

A 22 year old female patient reported to the Dept. of Conservative Dentistry and Endodontics with complaint of food lodgement and fractured restoration in relation to maxillary right first molar. Patient gave a history of the restoration being done one year ago. Clinical examination revealed a failing fractured composite restoration involving the mesio-occlusal aspect with loss of marginal integrity (Fig 6). Radiographic assessment revealed secondary caries in relation to the restoration (Fig 7).

Taking into account the past failure of the restoration, it was decided to reinforce the missing tooth structure by using short fibre reinforced composite.

Rubber dam was placed to obtain adequate isolation and caries excavation was carried out. The open sandwich technique was employed wherein a resin modified glass ionomer liner was placed to protect the underlying pulp and provide fluoride release as well (Fig 8).

Following its setting, a short fibre reinforced composite restoration (EverX Posterior, GC America) was incrementally layered to serve as a dentin substitute. Each increment was light cured for 20 seconds as per manufacturer instructions (Fig 9).

The overlying 2mm of the occlusal surface was structured using nanofiller composite (Ceram-

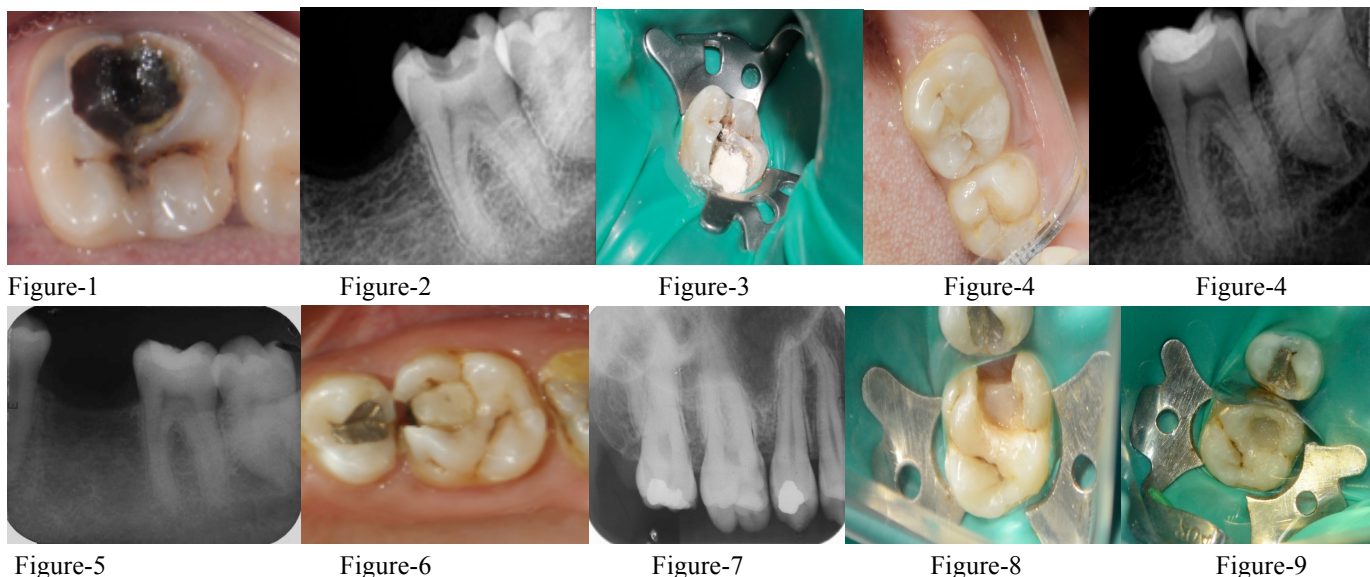


Figure-1: Preoperative photograph showing large carious lesion; **Figure-2:** Preoperative radiograph; **Figure-3:** Biodentine placed on the cavity floor; **Figure-4:** Postoperative intraoral and radiographic view; **Figure-5:** One year follow up radiographic view; **Figure-6:** Preoperative intraoral view; **Figure-7:** Preoperative radiograph; **Figure-8:** Following caries excavation and placement of RMGIC liner; **Figure-9:** Fibre reinforced composite placed; **Figure-10:** Postoperative intraoral and radiographic view

X duo, Dentsply). Finishing and polishing of the restoration was carried out subsequently (Fig 10). The patient is currently under regular follow up protocol.

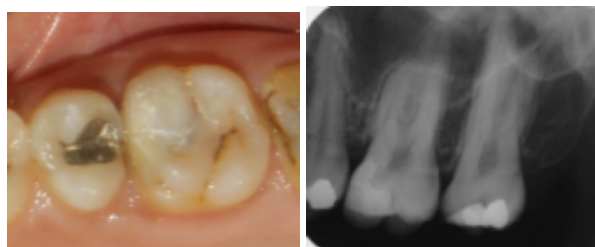

Figure-10: Postoperative intraoral and radiographic view

DISCUSSION

Extensive carious lesions with compromised marginal ridges and cusps pose a challenge to clinicians for their effective reconstruction and rehabilitation.

Besides considerable improvements in the field of adhesive dentistry, the last decade has witnessed the introduction of the concept of fibre reinforcement in restorative dentistry. The mechanical advantages of Fibre reinforced composites (FRC's) which have surpassed those of the conventional composites include their flexural

strength, fatigue strength, elastic modulus and bond strength.¹⁰

Extreme occlusal forces in the posterior region predispose to fracture of the enamel, but crack propagation continues towards the dentin where it is completely absorbed. From this point of view, FRC base mimics the supportive function of dentine during loading and acts as dentine replacing material.¹¹

Two of the mechanisms by which fibres exert high strain to failure on brittle composite matrix are by functioning as a stress-bearing component and by their crack-stopping or crack-deflecting mechanisms.⁷

Therefore the function of bulk short fibre composite substructure is based on supporting the surface particulate filler composite (PFC) layer. The reinforcing effect of the fibre fillers is based on stress transfer from polymer matrix to fibres, which also contributes to the fracture toughness of the material.^{1,5,11}

Garoushi et al evaluated the load bearing capacity and fracture pattern of combined FRC and PFC with conventional composite resin. The authors reported good performance of the combination of bulk short fibre composite substructure and surface layer of particulate filler composite in high stress bearing areas that permitted crack

propagation while catastrophic fractures was noted in conventional PFC only.¹ Frater et al, demonstrated that short FRC base improves the fracture resistance and the failure mode of posterior composite restorations.¹²

FRC's possess an increased depth of cure and can be placed in bulk increments of 3mm thereby saving considerable amount of clinical time. Le Bell et al. stated that fibre-reinforced composites conduct and scatter the light better than conventional composite resin.^{5,13}

Polymerization shrinkage is one of the critical limitations of the light-cured dental composites. Such shrinkage induces contraction stress at interface between composite resin and cavity walls, leading to gap-formation and secondary caries.¹¹

Literature reports that the short fibre composite resin has an improved control over the polymerization shrinkage stress, resulting in overall reduced marginal microleakage when compared with conventional PFC's.¹⁴

CONCLUSION

Fibre reinforced composites appear to be a promising restorative option over conventional composites and indirect cast restorations by allowing minimally invasive preparations and reinforcing the remaining tooth structure against potential fracture. Although the observation period in the first case is limited to one year, the results are encouraging. Further long term controlled clinical trials are necessary to substantiate the treatment outcome and justify their application in restorative dentistry.

REFERENCES

1. Sufyan Garoushi, Enas Mangoush, Mangoush Vallittu, Lippo Lassila. Short Fiber Reinforced Composite: a New Alternative for Direct Onlay Restorations. *Open Dent J* 2013;7:181-185
2. Flávio F. Demarco, Marcos B. Corrêa, Maximiliano S. Cenci, Rafael R. Moraes, Niek J.M. Opdam. Longevity of posterior composite restorations: Not only a matter of materials. *Dent Mater* 2012;28:87-101.
3. Giachetti L, Scaminaci Russo D, Bambi C, Grandini R. A review of polymerization shrinkage stress: Current techniques for posterior direct resin restorations. *J Contemp Dent Pract* 2006;4:79-88.
4. Simone Deliperi, David N Bardwell. Reconstruction of non vital teeth using direct fibre reinforced composite resin: a pilot clinical study. *J Adhes Dent* 2009; 11:71-78.
5. Sufyan Garoushi, Eija Säilynoja, Pekka K. Vallittu, Lippo Lassila. Physical properties and depth of cure of a new short fibre reinforced composite. *Dent Mater* 2013; 29:835-41.
6. Opdam NJ, Roeters JJ, Loomans BA, Bronkhorst EM. Seven-year clinical evaluation of painful cracked teeth restored with a direct composite restoration. *J Endod.* 2008; 34:808-11.
7. Vasundhara Shivanna, Pallavi B. Gopeshe-tti. Fracture resistance of endodontically treated teeth restored with composite resin reinforced with polyethylene fibres. *Endo-dontology* 2012;24:71-77.
8. Meng Zhang, Jukka Pekka Matinlinna. E-Glass Fibre Reinforced Composites in Dental Applications. *Silicon* 2012;4:73-78.
9. Suresh Nandini. Indirect resin composites. *J Conserv Dent* 2010;13:184-94.
10. Sufyan Garoushi, Akikazu Shinya, Akiyoshi Shinya, Pekka Vallittu. Fibre reinforced onlay composite resin restoration: a case report. *J Contemp Dent Pract* 2009;10:104-110.
11. Sufyan K. Garoushi, Marwa Hatem, Lippo V. J. Lassila, Pekka K. Vallittu. The effect of short fibre composite base on microleakage and load-bearing capacity of posterior restorations. *Acta Biomater Odontol Scand*, 2015; Early Online: 1-7.
12. Fra'ter M, Forster A, Keresztu'ri M, Braunitzer G, Nagy K. In vitro fracture resistance of molar teeth restored with a short fibre reinforced composite material. *J Dent.* 2014;42:1143-45.
13. Julian G. Leprince, William M. Palin, Julie Vanacker, Joseph Sabbagh, Jacques Devaux, Gaetane Leloup. Physico-mechanical characteristics of commercially available bulk-fill composites. *J Dent* 2014;42:993-1000.
14. Garoushi S, Vallittu PK, Watts DC, Lassila LVJ. Polymerization shrinkage of experimental short glass fibre reinforced composite with semi-inter penetrating polymer network matrix. *Dent Mater.* 2008;24:211-215.