

Claspless Cast Partial Denture with Extracoronar Semi-Precision Attachments and Milled Abutments.

Jadhav Amit B.¹, Sanyal Pronob K.², Suragimath Girish³, Sushma R.⁴

Introduction: The partial edentulous patient has several options for prosthetic treatment including fixed and removable solutions. The mastication, phonation and esthetics: The trident factors are very important to achieve the successful outcome of treatment. Satisfactory restoration in a patient with a partially edentulous situation can be challenging especially for unilateral or bilateral missing posterior segment. Successful restoration can be done with various conventional and contemporary treatment options. One such treatment modality is attachment-retained cast partial dentures. This paper describes a case report of a patient with maxillary bilateral distal extension edentulous span restored with a cast partial denture having an extracoronar castable precision attachment (RHEIN 83 OT STRATEGY attachments system).

Case Report: A 70 year old male patient was reported with missing posterior maxillary teeth bilaterally. The remaining teeth in maxillary arch were periodontally compromised. After complete clinical and radiographic examination, a prosthetic treatment plan was designed. Fixed removable prosthesis with extracoronar precision attachments and milled abutments were planned for the maxillary kennedy's class-I arch.

Conclusion: The partially edentulous patients restored with a fixed removable prosthesis experiences more satisfaction with their prosthesis, improved masticatory ability and nutrition, along with improvements in psycho-social aspects of life.

Keywords: Claspless Cast Partial Denture, Precision Attachments, Milled Abutment, Fixed Removable Prosthesis.

INTRODUCTION

In our clinical practice, we come across patients with variety of needs and demands regarding their missing teeth. In order to replace these missing teeth a thorough knowledgeable treatment planning becomes an essential key to success. Amongst the various conditions, posterior edentulism (Kennedy's Class I and II) is most common.

Prosthetic options for these patients include fixed dental prosthesis or a removable dental prosthesis. The fixed treatment options include dental implants, but due to economic factors, unavailability of specific bone requirements or long duration of treatment not all patients can benefit from dental implants. Removable treatment options could be either cast partial dentures as a long term treatment modality or resin based partial dentures as an interim treatment option.

Another option, which has all the advantages of fixed prosthesis in addition to support, stability, and retention, is the Cast Partial Denture with Precision attachments. Treatment with a cast partial denture with precision attachments is an affordable choice to fulfil the patient's esthetic demands in addition to providing good prognosis for the prosthesis and preservation of the remaining dentition.¹ A cast partial denture with milled abutments and precision attachments is a treatment option for restoration of such long span partially

edentulous maxillary arches. This prosthesis meets all the above requirements.

CASE REPORT

A 70 year old male patient was referred to Department of Prosthodontics, with missing posterior maxillary teeth bilaterally. He gave a medical history of diabetes, hypertension since five years and has undergone bypass surgery twice in last two years. He also gave history of unsatisfactory acrylic partial denture usage.

On intraoral examination, it was found that the patient had missing all maxillary premolars and molars bilaterally and edentulous mandibular arch with porcelain fused to metal fixed partial denture replacing missing 31, 32, 41 and 42. The remaining teeth in maxillary arch were periodontally compromised with grade III mobility in relation to 22 [Figure 1(a)]. On intraoral periapical radiographic examination, it was found that all maxillary anterior teeth were root canal treated of which 12 and 22 showed fractured crowns. Extraction of 22 was carried out under local anaesthesia followed by post and core treatment of 12 [Figure 1(b)].

After complete clinical and radiographic examination, a prosthetic treatment plan was designed. Fixed removable prosthesis with extracoronar precision attachments {(154PSC) Rhein83, USA} and milled abutments were planned for the maxillary kennedy's class-I arch.

- 1. Tooth Preparation:** Abutment teeth (11, 12, 13, 21 and 23) were prepared to receive full veneer metal crowns with ceramic facing on 11, 12 and 13 and full veneer metal bridge with ceramic facing on 21, 22 and 23. The prepared abutments were temporized after making definitive impression.
- 2. Lab Procedure:** Abutments were waxed up {DFS, Germany} to receive crowns and bridge. Milling of lingual area of completed wax patterns was done by using milling machine {Mariotti, Italy} [Figure 2(a)] with wax milling bur {Jota AG, Switzerland}. Articulation spaces and bulkiness were evaluated in order to proceed with optimal positioning of attachments using parallelometer

¹P.G. Student, ²Professor and H.O.D., ⁴Associate Professor, Department of Prosthodontics, Crown and Bridge, ³Professor and H.O.D, Department of Periodontology, School of Dental Sciences, Krishna Institute of Medical Sciences, Deemed University, Karad, Maharashtra, India

Corresponding author: Dr. Amit Jadhav, 'Anupam' Plot No-10, Lahoti Houses, Mangalwar Peth, Karad. District- Satara. State: Maharashtra. India.

How to cite this article: Jadhav Amit B., Sanyal Pronob K., Suragimath Girish, Sushma R. Claspless cast partial denture with extracoronar semi-precision attachments and milled abutments. International Journal of Contemporary Medical Research 2016;3(3):707-709.

mandrel {(75AC04) Rhein83, USA}.

3. **Casting of PFM prosthesis with Attachment and Final Cementation:** Metal ceramic crowns waxed up with attachment structure were casted and porcelain firing was done. Trial seating of the finished prosthesis was performed, palatal surface was milled [Figure 2(b)] and after finishing and polishing cementation of crowns and bridge was done using Glass Ionomer Cement {Meron-VOCO-Cuxhaven, Germany}.
4. **Refractory Cast:** Master cast poured in dental stone (Type IV), Duplicating caps {(047CSD) Rhein83, USA} fitted on to male component of master cast, undercuts were blocked by using block out wax {Yeti Dental, Germany}, spacer wax adapted [Figure 2(c)] and mould obtained with reversible hydrocolloid duplication materials {Bego, Germany}; [Figure 2(d)]. Mould was poured by using refractory materials {Brevest R1, Bredent Germany} to get refractory cast.
5. **Metal Framework Casting and Trial:** Refractory cast was waxed-up, sprued and casted in the laboratory for the designed cast partial denture framework, [Figure 3]. The metal framework was checked on master cast and tried in patient's mouth for the accuracy of fit and jaw relation recorded.
6. **Wax-Up Trial:** Teeth setting trial was done in patient's mouth. The trial denture was sent for acrylization {Dentek, SP Dental, India} and cast partial denture finished.
7. **Securing the Precision Attachment:** Retentive component of the precision attachment were secured to the metal framework before insertion of denture.
8. **Positioning the Prosthesis in Patient's Mouth:** Complete seating of finished maxillary combined prosthesis with extracoronar castable distal extension precision attachment was evaluated clinically in the patient's mouth and the patient was recalled after 24 hrs for post insertion check-up [Figure 4].

DISCUSSION

Restoration of a long span partially edentulous maxilla with tooth supported prosthesis is challenging because of inherent anatomic limitations and unfavourable biomechanics present after the loss of teeth. When considering the anatomic limitations of a partially edentulous maxilla, the need for a properly designed prosthesis that results in favourable biomechanical stress distribution, esthetics, phonetics, comfort, and hygiene is of prime importance.²

Lothigius *et al.*³⁻⁵ have described techniques for fabrication of a hybrid maxillary prosthesis by using attachments. Van Rooke⁶ has described a technique for using electrical discharge machining (spark erosion), which was devised by Silard, to fabricate a fixed-removable prosthesis.

Parallel walls of milled surface of fixed prosthesis and closer adaptation of the cast partial denture to milled surface provide frictional resistance improving retention and stability of the prosthesis. Part of the cast partial denture which contacts the milled surface provides indirect retention against the force of gravity and during mastication aiding in retention. It provides large amount of support to the cast partial

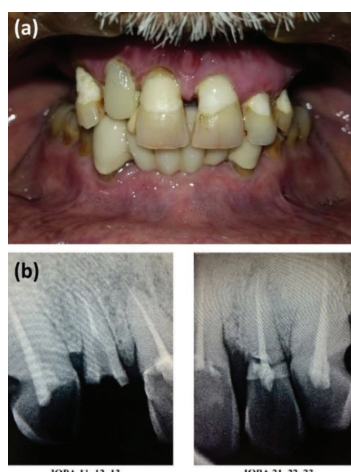


Figure-1: Preoperative View. (a) Intraoral Examination, (b) Radiographic Examination

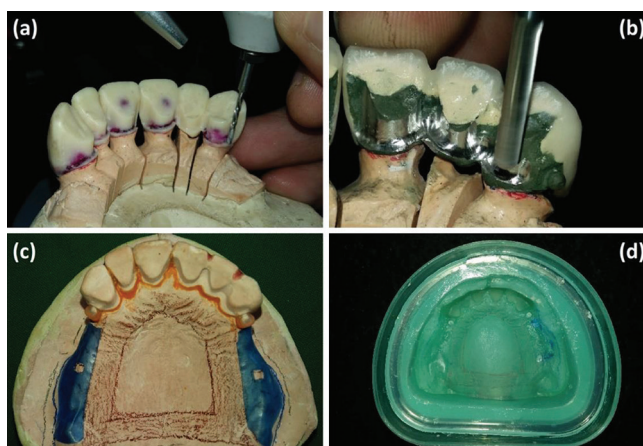

Figure-2: (a)Wax Milling, (b) Metal Milling, (c) Cast Ready for Duplication, (d) Mould to obtain Refractory Cast.

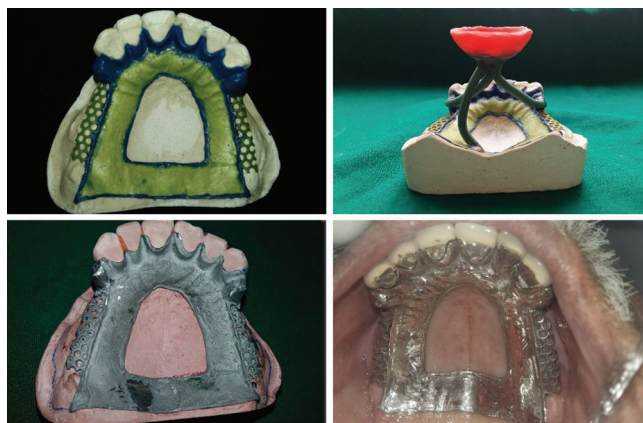

Figure-3: Wax-Up for Cpd Framework, Spruing, Casting and Try In Procedure

denture allowing all the forces to distribute evenly among all the teeth with milled surface.⁷

There are several indications for the use of attachments as a coupling between FPD and RPD. Esthetics (avoidance of unsightly clasps), support, stabilization, and fixation (resistance to separation of RPD and FPD) have been emphasized. Apart from improving esthetics and retention of removable partial dentures, the availability of precision attachment has made designing of removable partial dentures more flexible.

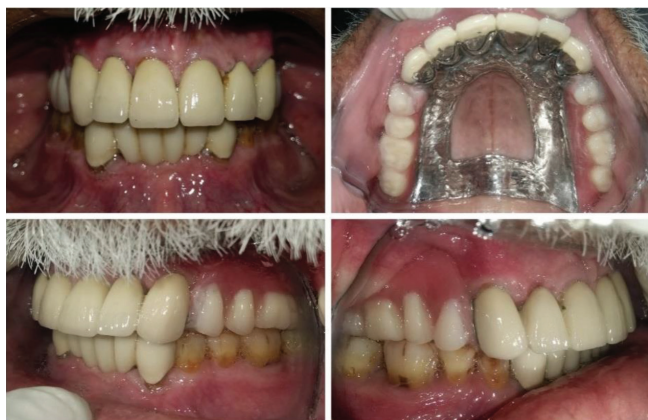

Figure-4: Denture Insertion.

In present case semi precision non rigid attachments were preferred (Rhein 83- OT Strategy) for fixation between fixed and removable partial dentures as it fulfills most of the criteria suggested for attachment selection. However precision attachments are not without disadvantages. Most of the attachments are very small and come with many parts to assemble. Construction of such attachment require skill. The parts of the attachment are sometimes exposed to wear and tear and needed to be replaced over time.⁸

CONCLUSION

The treatment of a complex, partially edentulous patient using a combination of fixed and removable partial dentures and precision attachments as retentive elements has long been considered as among the most sophisticated forms of care.

The creation of milled guiding planes itself can serve as precision attachments to enhance the stability and retention of the removable partial denture

The partially edentulous patients restored with a fixed removable prosthesis experiences more satisfaction with their prosthesis, improved masticatory ability and nutrition, along with improvements in psycho-social aspects of life.

REFERENCES

1. Jeyavalan MI, Narasimman M, Venkatakrishnan CJ, Philip JM. Management of long span partially edentulous maxilla with fixed removable denture prosthesis. *Contemp Clin Dent*. 2012;3:314-16.
2. Chee WW. Treatment planning: Implant-supported partial overdentures. *J Calif Dent Assoc*. 2005;33:313-6.
3. Lothigius E, Smedberg JI, De Buck V, Nilner K. A new design for a hybrid prosthesis supported by osseointegrated implants: 1. Technical Aspects. *Int J Oral Maxillofac Implants*. 1991;6:80-6.
4. Smedberg JI, Lothigius E, Nilner K, De Buck V. A new design for a hybrid prosthesis supported by osseointegrated implants: 2. Preliminary clinical aspects. *Int J Oral Maxillofac Implants*. 1991;6:154-9.
5. Kramer A, Weber H, Benzing U. Implant and prosthetic treatment of the edentulous maxilla using a bar-supported prosthesis. *Int J Oral Maxillofac Implants*. 1992;7:251-5.
6. Van Roekel NB. Prosthesis fabrication using electrical discharge machining. *Int J Oral Maxillofac Implants*. 1992;7:56-61.

7. Brudvik JS, Shor A. The milled surface as a precision attachment. *Dent Clin N Am*. 2004;48:685-708.
8. Makkar S, Chhabra A, Khare A. Attachment retained Removable partial denture: a case report. *International Journal of Computing and Digital Systems*. 2011; 2:39-43.

Source of Support: Nil; **Conflict of Interest:** None

Submitted: 19-01-2016; **Published online:** 09-02-2016