

REVIEW ARTICLE

CBCT Imaging: Adding A New Dimension To Orthodontic Diagnosis, Treatment Planning And Its Assessment

Neha Assudani¹, Suresh Ludhwani²

ABSTRACT

The 21st century has seen rapid developments in the science of orthodontics. Cone beam computed tomography is a diagnostic imaging modality which produces high-quality, accurate three-dimensional information of the maxillofacial skeleton, including the teeth and their surrounding tissues. Since its inception it is gaining popularity as premier diagnostic tool in every specialty of dentistry both as research and clinical tool. Recently, with advent of low dosimetry levels CBCT scanners there is significant trend towards CBCT replacing OPG and cephalogram in orthodontics. The aim of this paper is to review the current literature on the applications of CBCT in orthodontics and highlight its areas of further research.

Keywords: CBCT, Cone Beam, Orthodontics

How to cite this article: Neha Assudani, Suresh Ludhwani. CBCT imaging: adding a new dimension to orthodontic diagnosis, treatment planning and its assessment. International Journal of Contemporary Medical Research. 2015;2(2):386-392

Source of Support: Nil

¹Senior lecturer, Department of Orthodontics, Ahmedabad dental college, ²Senior lecturer, Department of Oral medicine and Radiology, College of dental science and research, Ahmedabad, India

Corresponding author: Dr. Suresh Ludhwani, 28, Mukta Madu society, Near yuganada park, Bhairavnath road, Maninagar, Ahmedabad-38008, Gujarat, India.

Conflict of Interest: None

INTRODUCTION

The cone-beam computed tomography (CBCT)

scanners were introduced in the late 1990's as an evolutionary process resulting from the demand for three-dimensional (3D) information obtained by conventional computerized tomography (CT) scans.¹ It was started in 1982 at Mayo Clinic for angiography and shortly, the US Food and Drug Administration (FDA) approved in 2001. The CBCT technology differentiates itself from CT technology in shape or trajectory of beam used to capture the image. The CT uses a fan shaped beam to take multiple individual slices that are later reconstructed to form a 3D composite image. On the other hand, the cone shaped beam captures the entire object with one quick scan, translating to far low dose of radiation. Taking this into consideration CBCT has an edge over CT but with only drawback of low soft tissue image quality.²

The routine diagnostic records include plaster models, photographs & 2D radiographs. These 2D representations of 3D objects suffer from several limitations like magnification, distortion, superimposition & misinterpretation of structures.

APPLICATIONS OF CBCT IN ORTHODONTICS

Pre-Treatment

- Anatomy Assessment
- Cephalometric Analysis
- Treatment Planning

- Anatomy Assessment

3D Evaluation of Impacted Tooth Position and Anatomy

It is most common reason for use of CBCT imaging. An orthodontist can use a 3D constructed digital model, from cone beam data,

of impacted cuspid teeth to evaluate the vector of force & positioning of bracket needed to move the cuspid into proper position without impinging on surrounding teeth such as maxillary central & lateral incisor roots (Figure-1).³

Cleft Palate Assessment

CBCT in patients with cleft lip & palate is useful to estimate size of the osseous defects & the spatial relationship of the defect to other anatomic structures which are difficult to obtain in 2D images. Also for clinical assessment of bone graft quality following alveolar surgery.⁴⁻⁷

Assessment of Age & Growth

Yang et al has created software to calculate the pulp/tooth volume ratio based on cone-beam CT images.⁸ It was the first study concerning dental age estimation based on CBCT images. CBCT scans can be used to reliably assess cervical vertebrae maturity, which provides a consistent evaluation of skeletal maturity.⁹

Assessment Skeletal Symmetry or Asymmetry

Dental and skeletal asymmetries are best visualized and three dimension visualization makes it accurate. It can also help in diagnosing unilateral crossbite vs one shift of the mandible into centric occlusion by measuring maxilla and mandible in three dimension.¹⁰

Airway Morphology & Relationship to Obstructive Sleep Apnea

Airway analysis are routinely done on Lateral Cephalograms measuring soft and hard tissue landmarks. Reconstructed 2D images from CBCT have an edge over the conventional radiographs in terms of accuracy. Especially axial cuts of 3D CBCT provides more visible images. Complex anomalies like enlarged adenoids and obstructive sleep apnea can be easily diagnosed on CBCT. In study by Ogawa et al, sleep apnea affected subjects showed significant decrease in airway volume area on 3D CBCT.¹² Lateral cephalograms have been routinely used to assess the airway using techniques involving both tissue and soft tissue points. Conventional radiography and reconstructed 2D CBCT images provide similar assessments of the airway. In comparison, axial cuts of 3D CBCT scans provide soft tissue

points that are derived from the projection of shaded areas, which are more clearly visible in axial CBCT cuts compared with conventional radiographs, thereby enhancing airway assessment.¹¹ Three-dimensional CBCT-assisted airway analysis also facilitates the diagnosis and treatment planning of complex anomalies including enlarged adenoids and obstructive sleep apnea.¹² (Figure-2)

Cephalometric Analysis

3 Dimensional Cephalometric Assessment

Limitations of 2D cephalometrics have been well known since its introduction by Broadbent and Horfath in 1931 and more recently reported by Adams, Moshiri & Sarver. Johnston states that "As complex 3D structures are projected onto a 2D plane, there are several restrictions including superimposition of anatomical structures thus errors in landmark identification, magnification & distortion."

The CBCT allows 3D visualization of anatomic structures in all 3 planes sagittal, coronal & transverse. Landmark identification is greatly enhanced in CBCT images with magnification & contrast adjustment. Multiplanar views are especially advantageous in identifying bilateral landmarks such as condylion, gonion, & orbitale, which are frequently superimposed in conventional radiographs. With the help of softwares such as Dolphin (Dolphin Imaging & Management Solutions) and InVivo Dental (Anatomage), numerous cephalometric analysis can be carried out on CBCT images such as Downs, Steiner, Tweed, Ricketts and colleagues, Jacobson's WITS analysis, McNamara, Farkas, the Farkas/Mayes 3D facial analysis (Mayes J, personal communication, 2003),²⁷ Arnett and Bergman, Sarver, and Idiculla and colleagues. Moreover, by evaluation of landmarks, lines, distance & angles on CBCT the surface areas & volume can be assessed.¹³ (Figure-3)

Super impositions

Treatment result can be best assessed by superimposition of pre and post - treatment in three dimension in comparison to traditional lateral cephalometric superimposition. The introduction of CBCT allows clinicians to

perform pretreatment & posttreatment superimposition in three dimensions thus eliminating errors that occur with traditional lateral cephalometric superimposition. These superimpositions help in better assessment of treatment outcomes.

TREATMENT PLANNING

Planning for placement of dental implants and temporary anchorage devices (TADs)

The knowledge of root positioning can greatly enhance the opportunity for placement & success of mini-implants. The CBCT scan provides more accurate views to assess thickness of cortical bone, the location of maxillary sinus or inferior alveolar canal, the exact location of roots & inter root distance.¹⁴⁻¹⁶ Surgical guides that have been developed using a method employing high resolution CBCT scans and rapid prototyping have been shown to provide accurate placement of TADs on the buccal aspect of the jaws.¹⁷ Three-dimensional CBCT image-based stereo lithographic surgical stent guides have also been found to be more accurate than 2D surgical guides in micro implant placement.¹⁸ (Figure-4)

Orthognathic Surgery Treatment Planning & Distraction Osteogenesis

Using dedicated third party softwares, simulations of virtual repositioning of jaws, osteotomies, distraction osteogenesis and other intervention can be implemented. Its aids in presurgical treatment planing and patients can be well educated with the outcomes of the surgery. Several applications of CBCT in orthognathic surgery treatment simulation, guidance & outcome assessment have been developed. CBCT 3D surface reconstructions of jawbones are used for preoperative surgical planning & simulation in patients with traumas & skeletal malformations. Simulations of Virtual repositioning of jaws, osteotomies, distraction osteogenesis & other interventions can be implemented when coupled with dedicated softwares.¹⁹

Orthognathic Superimposition with CBCT Imaging

Studies of surgical treatment outcome may be

facilitated by using a new superimposition method which enables the operator to superimpose a custom surface mesh of the first CBCT image onto a second CBCT image of the anterior cranial base.²⁰

Orthodontic Treatment Planning

3D imaging will allow the orthodontist to automatically measure such things as the Bolton tooth size and arch length discrepancy quickly and accurately. Measurements of both erupted and unerupted teeth as well as the arch length available can be analyzed and the appropriate timing of an orthodontic course of action can be determined.²¹ This information can also allow for evaluation of different treatment options, such as different extraction patterns (serial extraction versus later phase extraction) and for minimum, moderate, or maximum anchorage requirements. Also possible expansion or uprighting of buccal and/or anterior segments, and/or interproximal stripping to gain arch length can be evaluated. In non-extraction cases, if the treatment plan calls for expansion or uprighting of the dental or skeletal arches, then the gains in arch length can be measured by the computer, and the orthodontist can decide if this treatment fits into the treatment scheme. (Figure-5)

Virtual Models

Study models in 3D CBCT acts as an best education tool. It is not only beneficial for the doctors as it spares time in taking alginate impression and making plaster models but also for the patients as it includes visualization of impacted teeth, root completion and alveolar bone.^{13,22} CBCT data can be used to produce 3D digital study models without the need for alginate impressions. It avoids patient discomfort & saves orthodontists valuable chair time. These models are of higher diagnostic value other than digital models because it includes not only the tooth crowns but also roots, impactions, developing teeth & alveolar bone.^{13,22}

MID-TREATMENT

Root Resorption

Root morphology & resorption have traditionally been assessed via periapical radiographs.

However CBCT provided enhanced visualization of roots making it a valuable tool for assessing pre orthodontic or post orthodontic resorption.²²⁻²⁴

TMJ assessments of condylar anatomy in three dimensions

TMJ has a pivot role in the orthodontics outcomes, as alteration in size, form, quality and spatial relationship of the osseous joint components can often cause highly adverse clinical manifestation, progressive bite changes and leading to unpredictable outcomes. CBCT has an edge over 2D imaging as it provides an opportunity to visualize and quantify the local and regional effects associated with TMJ abnormalities. Cases with centric occlusion vs centric relation disturbances, unilateral Class II malocclusion may involve displacement of the position of the TMJ in CO vs CR could get an aid in diagnosis and treatment planning with help of CBCT. TMJ pathologies that result in alterations in the size, form, quality and spatial relationships of the osseous joint components often cause highly adverse clinical manifestations, progressive bite changes and lead to unpredictable orthodontic outcomes. Such changes are difficult to characterize accurately with 2D radiographic imaging. In contrast, by allowing the concurrent visualization of TMJs, the maxillomandibular spatial relationships and occlusion, CBCT images provide clinicians with the opportunity to visualize and quantify the local and regional effects associated with TMJ abnormalities. The cases involving centric occlusion vs centric relation (CO/CR) discrepancies, unilateral Class II malocclusions or a retrognathic mandible may involve displacement of the position of the TMJ in CO vs CR, and could benefit from additional diagnostic information derived from CBCT scans.²⁵⁻²⁶

Assessment of Maxillary Expansion

Correction of transverse deficiency in adolescents is most commonly treated by Rapid maxillary expansion treatment. Role of the two dimensional (2D) cephalometric radiographs is limited due to overlapping of structures leading to difficulty in landmark identification and measurement errors. With application of CBCT, such difficulties can

be overcome. Rapid maxillary expansion treatments have been used widely to correct maxillary transverse deficiency problems in adolescents. Limitations of the two-dimensional (2D) cephalometric radiographs such as overlapping of structures leading to landmark identification errors and measurement errors obstruct the assessment of the skeletal and dental changes that occurs after the rapid maxillary expansion. The CBCT scanning technology overcomes these obstacles & provides superior reliability & greater accuracy in evaluation of bone changes.²⁷⁻³⁰

Investigation of Orthodontic-Associated Paraesthesia

Post orthognathic surgery, minor oral surgery and endodontic treatment procedure, sensory disturbances of the lower lip and chin area has been noted. However, on rare occasion sensory disturbances secondary to orthodontic treatment has been recorded. Such neuronal disturbances are classified as neuropraxias and they usually result due to compression of inferior alveolar nerve bundle. Such effect usually last for few hours to several months till the complete sensory recovery is achieved. Such disturbances can be easily diagnosed on cbct with mandibular nerve markings. Sensory disturbances of the lower lip and chin area are commonly reported after orthognathic surgery, after dentoalveolar surgery following endodontic treatment, or following removal of the mandibular third molars. In contrast, reports of sensory disturbances occurring secondary to regular orthodontic treatment are extremely rare. However, when they do occur, they can only be diagnosed by CBCT. These neural disturbances that occur during orthodontic treatment are classified as neuropraxias and they usually result from temporary conduction blockade due to compression of the inferior alveolar nerve bundle. The duration of the effects that patients experience may range from a few hours to several months, and usually, complete sensory recovery is achieved. A report by Chana et al. (2013) of orthodontic treatment-induced transient mental nerve paresthesia demonstrated the importance of CBCT scans as the sole aid in obtaining a definitive diagnosis of this clinical condition.³¹

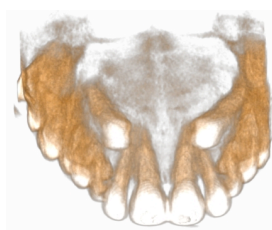
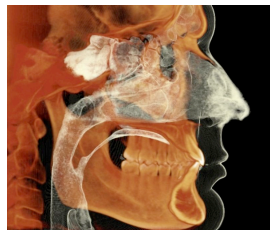
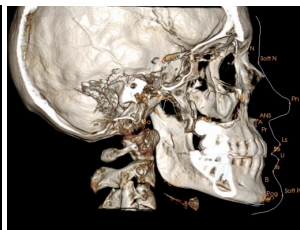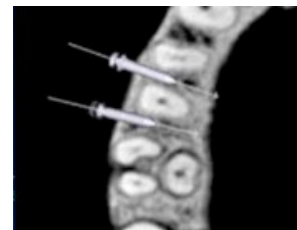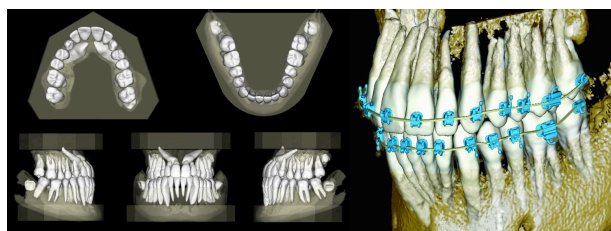
**Figure-1****Figure-2****Figure-3****Figure-4**

Figure-1: CBCT for impacted canine, Oroscan Ahmedabad; **Figure-2:** Airway Assessment Using CBCT, Imaging Sciences International; **Figure-3:** CBCT For 3D Cephalometric Analysis, Imaging Sciences International; **Figure-4:** CBCT For Accurate placement of Orthodontic Mini Implants, Oroscan Ahmedabad

**Figure-5**

Figures-5: Virtual models for orthodontic treatment planning using CBCT, Imaging Sciences International

Figure-6

orthodontic appliances has been demonstrated using CBCT image data with existing technology to virtually plan a patient's treatment and the manufacturing of custom appliances with 3D printing technology. Such advances appear to be rapid, and they also promise efficient and effective patient-specific treatments. Correspondingly, Orametrix (Richardson, TX) is a company that has been using CBCT technology for the last several years to provide the data necessary for planning and executing technology-assisted treatment through its Sure-Smile system.³²⁻³³ (Figure-6)

ADVANCEMENT

Invisalign Aligner

Impressions of patients are shipped to align technology where it is scanned for fabrication of aligners. It may be possible in future to execute the entire fabrication process of aligners using CBCT digital data. CBCT images can be used to create the virtual models, thus negating the need to take & mail impressions & bite registration. This information can be transferred electronically to laboratories and aligners can be fabricated.³⁰

Indirect Bonding of Brackets

Construction of hard copy of models from CBCT image can be used for laboratory procedures required for indirect bonding.

Custom Made Brackets & Wires

CBCT image data assisted fabrication of custom lingual orthodontics appliances has been demonstrated to virtually plan a patient's treatment plan and manufacturing of custom appliances with 3D printing technology. Orametrix (Richardson, TX) is a company that had developed its Sure-Smile system for planning and executing technology. Such advances are promising in terms of effectiveness of patient treatment.^{32, 33} The fabrication of custom lingual

CONCLUSION

CBCT has become widely available and acceptable by orthodontists with the newer advancements in the imaging machines, techniques, and stimulations softwares which can assist in treatment planning & translational products. The tide seems to be turning. Will the OPGs, Cephalograms, Periapical Radiographs in orthodontics soon be considered outdated, even irresponsible imaging? It is foreseeable that with extremely low radiation dose CBCT scanners, orthodontic community will shift towards CBCT as a routine imaging modality of choice in everyday practice.

REFERENCES

1. Ahmed Ghoneima, Eman Allam, Katherine Kula and L. Jack Windsor. Chapter 8 :Three-Dimensional Imaging and Software Advances in Orthodontics, Orthodontics: Basic Aspects and Clinical Considerations:
2. Danforth RA, Peck J, Hall P. Cone beam volume tomography: an imaging option for diagnosis of complex mandibular third

- molar anatomical relationships. *J Calif Dent Assoc* 2003;31: 847–52.
3. Wriedt, S., Jaklin, J., Al-Nawas, B., Wehrbein, H. Impacted upper canines: examination and treatment proposal based on 3D versus 2D diagnosis. *J. Orofac. Orthop.* 2012;73:28–40
 4. Miracle AC, Mukherji SK: Conebeam CT of the Head and Neck, Part 2: Clinical Applications. *Am J Neuroradiol* 2009; 10.3174/ajnr.A1654
 5. Kumar V, Ludlow JB, Mol A, Cevdanes L: Comparison of conventional and cone beam CT synthesized cephalograms. *Dentomaxillofacial Radiology* 2007;36:263–269.
 6. Hamada Y, Kondoh T, Noguchi K, Iino M, Isono H, Ishii H, et al. Application of limited cone beam computed tomography to clinical assessment of alveolar bone grafting: a preliminary report. *Cleft Palate Craniofac J* 2005;42:128–137
 7. Oberoi S, Chigurupati R, Gill P, Hoffman WY, Vargervik K. Volumetric assessment of secondary alveolar bone grafting using cone beam computed tomography. *Cleft Palate Craniofac J* 2009;46:503–511
 8. Yang F, Jacobs R, Willems G: Dental age estimation through volume matching of teeth imaged by cone-beam CT. *Forensic Science International* 2006; 159S:S78–S83.
 9. Shi H, Scarfe WC, Farman AG. Three-dimensional reconstruction of individual cervical vertebrae from cone-beam computed-tomography images. *Am J Orthod Dentofacial Orthop* 2007;131(3): 426-432. 100.
 10. S. L. Hechler, “Cone-beam CT: applications in orthodontics,” *Dental Clinics of North America*, vol. 52, no. 4, pp. 809–823, 2008.
 11. Vizzotto M.B., Liedke G.S., Delamare E.L., Silveira H.D., Dutra V., Silveira H.E. A comparative study of lateral cephalograms and cone-beam computed tomographic images in upper airway assessment. *Eur. J. Orthod.* 2012;34(3):390–393. [PubMed]
 12. Ogawa T., Enciso R., Shintaku W.H., Clark G.T. Evaluation of cross-section airway configuration of obstructive sleep apnea. *Oral Surg. Oral Med. Oral Pathol. Oral Radiol. Endod.* 2007;103:102–108. [PubMed]
 13. William E. Harrell, Jr. 3D Diagnosis and Treatment Planning in Orthodontics *Semin Orthod* 2009;15:35-41
 14. Baumgaertel S, Hans MG. Buccal cortical bone thickness for mini-implant placement *Am J Orthod Dentofacial Orthop* 2009;136: 230-235
 15. Harrell W.E: Three-dimensional diagnosis & treatment planning: The use of 3D facial imaging and 3D cone beam CT in orthodontics and dentistry. *Australian Dental Practice.* July/August 2007;102-113
 16. Kim SH, Yoon HG, Choi YS, Hwang EH, Kook YA, Nelson G: Evaluation of interdental space of the maxillary posterior area for orthodontic mini-implants with cone-beam computed tomography. *Am J Orthod Dentofacial Orthoped* 2009;5:635-641.
 17. Gonzalez SM: Cortical bone thickness of the maxilla and mandible for mini-implant placement. Master Thesis University of Iowa 2008 (Retrieved August 2009 from <http://ir.uiowa.edu/etd/36>).
 18. Christensen GJ: The ‘mini’-implant has arrived. *JADA* 2006; 137: 387-390.
 19. Kim S.H., Choi Y.S., Hwang E.H., Chung K.R., Kook Y.A., Nelson G. Surgical positioning of orthodontic mini-implants with guides fabricated on models replicated with cone-beam computed tomography. *Am. J. Orthod. Dentofacial Orthop.* 2007;131:S82–S89.
 20. Qiu L., Haruyama N., Suzuki S., Yamada D., Obayashi N., Kurabayashi T., Moriyama K. Accuracy of orthodontic miniscrew implantation guided by stereolithographic surgical stent based on cone-beam CT-derived 3D images. *Angle Orthod.* 2012;82:284–293.
 21. Swennen, Gwen RJ, Wouter Mollemans, and Filip Schutyser. "Three-dimensional treatment planning of orthognathic surgery in the era of virtual imaging." *Journal of oral and maxillofacial surgery* 2009;10: 2080-2092.
 22. Kau CH, Littlefield J, Rainy N, Nguyen JT, Creed B. Evaluation of CBCT digital models and traditional models using the Little's Index. *Angle Orthod.* 2010;80: 435–439.
 23. Lund H, Grondahl K, Grondahl HG. Cone beam computed tomography for assessment of root length and marginal bone level

- during orthodontic treatment. *Angle Orthod* 2010;80:466–473
24. Van Elslande D, Heo G, Flores-Mir C, Carey J, Major PW. Accuracy of mesiodistal root angulation projected by cone-beam computed tomographic panoramic-like images. *Am J Orthod Dentofacial Orthop* 2010;137:S94–99
 25. Honey OB, Scarfe WC, Hilgers MJ, Klueber K, Silveira AM, Haskell BS, et al. Accuracy of cone-beam computed tomography imaging of the temporomandibular joint: comparisons with panoramic radiology and linear tomography. *Am J Orthod Dentofacial Orthop* 2007;132:429–438
 26. Guyuron B. Facial deformity of juvenile rheumatoid arthritis. *Plast Reconstr Surg* 1988;81:948–951
 27. Lagravèrea MO, Gordonb JM, Guedesc IH, Mird CF, Careye JP, Heof G, Majorg PW. Reliability of Traditional Cephalometric Landmarks as Seen in Three-Dimensional Analysis in Maxillary Expansion Treatments. *Angle Orthod*. 2009;79: 1047–1056.
 28. Osorio F, Perilla M, Doyle DJ, Palomo JM: Cone Beam Computed Tomography: An Innovative Tool for Airway Assessment. *Anesthesia and Analgesia* 2008;106:1803–1807.
 29. Garrett BJ, Caruso JM, Rungcharassaeng K, Farrage JR, Kim JS, Taylor GD. Skeletal effects to the maxilla after rapid maxillary expansion assessed with cone-beam computed tomography. *Am J Orthod Dentofacial Orthop* 2008;134:8–9.
 30. Rungcharassaeng K, Caruso JM, Kan JY, Kim J, Taylor G. Factors affecting buccal bone changes of maxillary posterior teeth after rapid maxillary expansion. *Am J Orthod Dentofacial Orthop* 2007;132: 428 e1–8
 31. R.S. Chana, W.A. Wiltshire, A. Cholakakis, G. Levine Use of cone-beam computed tomography in the diagnosis of sensory nerve paresthesia secondary to orthodontic tooth movement: a clinical report *Am. J. Orthod. Dentofacial Orthop.*, 2013;144:299–30
 32. Ye, N., Li, J., Zhang, K., Yang, Y., Lai, W. Computer-aided design of a lingual orthodontic appliance using cone-beam computed tomography. *J. Clin. Orthod*. 2011;45:553–559.
 33. Larson, B.E. Cone-beam computed tomography is the imaging technique of choice for comprehensive orthodontic assessment. *Am. J. Orthod. Dentofacial Orthop*. 2012;141:402–411.