

# A Clinical Study on the Role of Laser Photocoagulation in Proliferative Diabetic Retinopathy

Ruma Das<sup>1</sup>, Nilay Talsania<sup>2</sup>, Abhisek Mondal<sup>3</sup>, Vikash Sharma<sup>3</sup>

## ABSTRACT

**Introduction:** Diabetic retinopathy is a microvascular complication of Diabetes mellitus which remains the number one cause of blindness in developed countries. Aims and Objectives of the present research were to evaluate the role of frequency double diode pumped Nd: YAG green laser photocoagulation in progression of diabetic retinopathy with effect on visual acuity and to study the adequate power, duration, retinal spot size and number of burns required to perform laser photocoagulation and complications associated with it.

**Material and methods:** Prospective study done for 1 year in the Dept. of Ophthalmology, Silchar Medical College and Hospital, Silchar. 50 cases (type 2 diabetes mellitus with PDR or CSME confirmed by F.F.A). Visual acuity; Ophthalmoscopic examination; Slit lamp examination; Fluorescein study; Optical Coherence Tomography; were done on all patients. All cases of laser photocoagulation were reviewed 3 weekly, 3 monthly and 6 monthly.

**Results:** Maximum patients were in the age group of 50-59 years (48%) and male preponderance (66%) was seen. Duration of diabetes is an important predictor of progression of diabetic retinopathy. In our study 46% (23 cases) of cases are having diabetes from last 10-15 years. Power used for grid/focal laser was less than that required for PRP. The spot sizes required for grid/focal is lesser than that for PRP. It was seen that resolution or improvement in the macular edema occurred in 81.57% of cases after focal/grid laser photocoagulation on follow up. It was also seen that neovascularization regressed in 72% of the cases after PRP on follow up. The commonest complication was vitreous haemorrhage (7.5%) followed by chronic macular edema (5%).

**Conclusion:** Laser photocoagulation decreases the chances of severe visual loss due to complications of diabetic retinopathy and reduces the ocular morbidity. Rational and timely laser therapy is an important method to control diabetic retinopathy.

**Keywords:** Laser photocoagulation, proliferative diabetic retinopathy

## INTRODUCTION

Diabetic retinopathy is a microvascular complication of Diabetes mellitus which remains the number one cause of blindness in developed countries and its incidence is increasing in the developing countries too. The best predictor of diabetic retinopathy, which may be due to type- I or type- II diabetes is the duration of the disease.<sup>1</sup> 27% of the patients who have type- I for 5-10 years and 71-90% who have diabetes for >10 years suffered from diabetic retinopathy.<sup>2</sup> In patients with type-II diabetes, prevalence of retinopathy 11-13 years after the onset of diabetes was 23%, after 16 or more years it was 60%.<sup>3</sup>

Blindness in diabetic retinopathy is primarily the result of formation of new vessels as in proliferative diabetic retin-

opathy (PDR)<sup>4</sup> and diabetic macular edema (DME)<sup>5</sup>, which is the most common cause of decreased vision as in other cases.

To date laser photocoagulation has remained the only noninvasive mode of treatment for proliferative diabetic retinopathy and diabetic maculopathy. Using timely laser photocoagulation as advocated by diabetic retinopathy study (DRS) and early treatment diabetic retinopathy study (ETDRS), severe visual loss can be reduced by 95%.<sup>6</sup> Aims and Objectives of the present research were to evaluate the role of frequency double diode pumped Nd: YAG green laser photocoagulation in progression of diabetic retinopathy with effect on visual acuity and to study the adequate power, duration, retinal spot size and number of burns required to perform laser photocoagulation and complications associated with it.

## MATERIAL AND METHODS

Our study is a prospective study conducted in Silchar Medical College and Hospital, Assam over a period of 1 year.

### Inclusion criteria for selection of cases were:

Patients presenting at the Retina clinic in the Department of Ophthalmology, Silchar Medical College and Hospital, with following criteria:

Patients diagnosed to have proliferative diabetic retinopathy and/ or clinically significant macular edema and giving consent to be part of study.

### Exclusion criteria for the study were:

Medical contraindication for laser or refusals, lost follow up, hazy ocular media, pregnancy, concomitant ocular pathology (glaucoma, high myopia, hypertension etc), and type-I diabetes mellitus cases.

**Number of cases recruited:** 50 cases of type 2 diabetes mellitus with PDR or CSME confirmed by F.F.A (Precision of 5%, Prevalence of PDR to be 3.4%<sup>7</sup>, Population of 55 lakhs, CI level of 95%). Institutional board approval was obtained from the Ethical committee of our institution.

**Diagnostic tests performed:** Visual acuity; Ophthalmoscopic examination; Slit lamp examination; Fluorescein study (Zeiss Fundus Camera, Visucam Lite); Optical Coher-

<sup>1</sup>Associate Professor, <sup>3</sup>Post Graduate Trainee, Department of Ophthalmology, Silchar Medical College and Hospital, Assam, <sup>2</sup>Class 1 Eye Surgeon, Department of Ophthalmology, Siddhpur civil hospital, Gujarat, India

**Corresponding author:** Dr. Ruma Das, Green Park, Meherpur, Silchar, Cachar, Assam-788015, India

**How to cite this article:** Ruma Das, Nilay Talsania, Abhisek Mondal, Vikash Sharma. A clinical study on the role of laser photocoagulation in proliferative diabetic retinopathy. International Journal of Contemporary Medical Research 2016;3(3):855-858.

ence Tomography (3<sup>rd</sup> generation Cirrus HD OCT (Spectral Domain Technology)).

Doubled diode pumped Nd: YAG (532x2nm) green laser photocoagulation done in 3 sittings. Among the laser parameters used in various modes of delivery, interval was kept constant whereas spot size, power and duration varied from case to case. Patients were then discharged with a NSAID eye drop and reviewed at a weekly interval for the second and the third sittings subsequently. In each visit before laser procedure visual acuity, SLE, IOP and a thorough fundus examination was done. All cases of laser photocoagulation were reviewed 3 weekly, 3 monthly and 6 monthly. In each follow up visit VA, SLE, IOP, Indirect Ophthalmoscopy, Gonioscopy were done to examine for regression of neovascularization, resolution of macular edema and to rule out any complication. FFA if required is repeated after 3 months.

**RESULTS**

Out of 50 patients 33 (66%) were Males. The age ranged from 30-70 years and maximum cases in age group 50-59 years ( 48%). Duration of diabetes mellitus since diagnosis ranged from 0->15 years. Maximum number of patients were having diabetes from last 10-15 years 23 cases (46 %). The total of 80 eyes were divided into four groups – (i) PDR only, (ii) PDR with HRC, (iii) PDR with CSME, (iv) CSME only. 28 eyes (35%) fell into the first group, 14 (17.5%) into the second, 8 (10%) into the third and 30 (37.5%) into the fourth group. Eyes having PDR/PDR with HRC, PRP was done (52.5%); those having diffuse macular edema grid laser was given (13.75%). For focal macular edema focal laser was given in (23.75%) of the eyes and the ones having both PDR and CSME, grid laser and PRP were given together (10%).

Power used for grid/focal laser was less than that required for PRP. Further power used for focal was <100mW in 57.8% of the cases and was in the range of 100-199 mW for the rest. In case of grid laser <100 mW was required in 36.8% of the cases and 100-199 mW for the rest of the eyes.

The spot sizes required for grid/focal was lesser than that for PRP. Further spot size required for grid was <100 µm in 36.87% and 100-199 µm in 63.15% of eyes. In case of focal <100 µm was required in 89.47% and 10.52% required 100-199 µm. Therefore the largest spot size was required for grid laser than focal in more number of eyes. In case of PRP spot size ranged from 200-300 µm. Grid included eyes underwent

grid alone (11 cases) and also the ones which were subjected to grid and PRP (8 cases). Similarly in case of PRP, PRP alone was done in 42 and PRP and grid in 8 eyes.

Duration of 0.1 second was used in all eyes in which PRP was done. 89.47% of eyes undergoing grid laser required 0.1 second and only 10.52% of eyes required 0.05 second. Therefore it can be seen that most of the eyes required a duration of 0.1 second for adequate laser photocoagulation. Only in case of focal, 47.37% of eyes required 0.05 second. For focal laser, average 153 numbers of burns and for grid laser 357 numbers of burns were delivered in a single sitting for the adequate laser photocoagulation. In case of PRP average number of burns given in a single sitting was 643. These were given in three sittings (643x3). The actual number of burns varied from eye to eye in different types of laser.

Some percent of eyes undergoing laser photocoagulation showed improvement in visual acuity. Stabilization of visual acuity was also achieved in most of the eyes. Some percentage of eyes showed decrease in acuity due to laser complications or progression of cataract on follow up (Table 01), (Pie Chart 01).

The table-2 shows the post laser BCVA in those eyes having baseline.

**VA ≥ 6/18:** From the above chart it can be seen that 78.9% of the eyes showed improvement or stabilization of visual acuity. In 16% of the eyes there was moderate visual loss and in 5% severe visual loss occurred after laser procedure.

**VA in the range of 6/24 to 6/60:** From the above chart it can be seen that 56% of the eyes remained in the same group, 23% of the eyes showed improvement and 21% deteriorated to ≤6/60 after laser photocoagulation.

**VA < 6/60:** From the Table 02 it can be seen that in 72% of the eyes, VA remained stable. Only 27% of the eyes showed improvement to 6/24-6/60. In no eye, VA in the range of 6/6-6/18 was achieved.

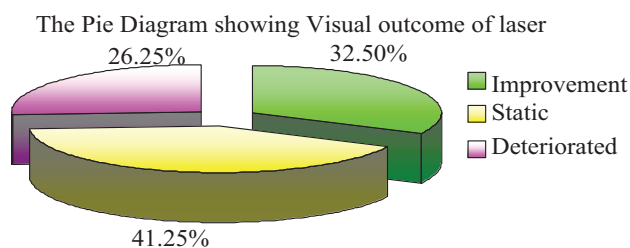
It was seen that resolution or improvement in the macular edema occurred in 81.57% of cases after focal/grid laser photocoagulation on follow up. Neovascularization regressed in 72% of the cases after PRP on follow up. It was seen that the commonest complication was vitreous haemorrhage (7.5%) resulting in significant drop in visual acuity. The next commonest complication was chronic macular edema (5%). In some of the eyes (2.5%) pre retinal haemorrhage over the macula resulted in decreased visual acuity. Few (2.5%) com-

BCVA	Focal	%	Grid	%	PRP+Grid	%	PRP	%
Improved	07	36.8%	03	27.3%	02	25%	14	33.3%
Static	08	42.10%	06	54.5%	03	37.5%	16	38%
Deteriorated	04	21.05%	02	18.2%	03	37.5%	12	28.5%
Total	19	100%	11	100%	08	100%	42	100%

**Table-1:** Status of Visual acuity after Laser photocoagulation

Baseline BCVA	Post laser BCVA						Total
	6/6-6/18	%	6/24-6/60	%	<6/60	%	
6/6-6/18	15	78.9%	03	15.78%	01	5.2%	19
6/24-6/60	09	23%	22	56.4%	08	20.5%	39
<6/60	00	00%	06	27.2%	16	72%	22

**Table-2:** Status of Visual acuity after Laser photocoagulation in relation to pre treatment visual acuity.



**Pie Chart-1:** The Pie Diagram shows the overall success rate of different types of laser on BCVA. Improvement in visual acuity occurred in 32.50% of the case. Stabilization of visual acuity occurred in maximum number (41.25%) of the eyes. Therefore overall success accounts to 73.75%.

plained of moderate pain after the laser procedure. Apart from these complications visual loss occurred in few due to development or progression of cataract with time.

## DISCUSSION

### Demographic Profile

Yanko et al. (1983)<sup>8</sup> reported that diabetic retinopathy is the commonest cause of newly reported blindness in 41-60 years of age group. Age ranges from 38-72 years with a mean age of 57.62 years in our study.

Shrestha S, Karki DB, Byanju R et al. (2007)<sup>9</sup> reported an increased incidence of males (58%) having diabetic retinopathy in their study. In our study it was found that there was more number of males (66%) having DR requiring laser photocoagulation than females (33%).

Mohan Rema, Purushothaman Sujatha et al. (2005)<sup>10</sup> reported  $14.4 \pm 6.4$  years mean duration of diabetes mellitus. Our study closely correlates with other studies in terms of mean duration of diabetes mellitus i.e., 13.32 years.

### Laser Parameters

**a. Power used (mW):** In our study the power used for grid/focal photocoagulation is in the range of 80-120mW which was lesser than that used by Y.K. Dastur<sup>11</sup> and Kajo Bucan, Milan Ivanisevic et al<sup>12</sup>, in their study.

**b. Average number of laser burns:** In ETDRS (1987)<sup>13</sup> the number of burns delivered for complete full scatter treatment was 1200-1600. H.K. Tewari, Viney Gupta et al. (2000)<sup>14</sup> in a study on laser scatter photocoagulation in diabetic retinopathy delivered  $1694 \pm 234$  numbers of burns. In a similar study by Mohan Rema, Purushothaman Sujatha et al. (2005)<sup>10</sup> about the visual outcomes of PRP delivered 2500-3000 numbers of burns. In our study average number of burns delivered in a single sitting of PRP is 643 and in three sittings ( $643 \times 3 = 1923$ ), which closely correlates with the above studies.

**c. Spot size ( $\mu\text{m}$ ):** The spot size used for focal laser is in the range of 50-100 $\mu\text{m}$  and that for grid is 100-200 $\mu\text{m}$  in all the studies mentioned above. The spot size used for PRP is between 200-500 $\mu\text{m}$ . In our study the spot size used for focal/grid laser photocoagulation ranged from 50-100 $\mu\text{m}$  and that for PRP is in range of 200-300 $\mu\text{m}$  which is same as used by ETDRS<sup>13</sup> and other studies.

**d. Duration (sec):** ETDRS<sup>13</sup> required 0.05-0.1 sec for focal/grid and 0.1 sec for PRP.

In our study duration is kept constant in all cases of PRP i.e., 0.1 sec which is similar to ETDRS. In case of focal and grid laser photocoagulation duration varied from 0.05-0.1 sec which also correlates with other studies.

### Effect On Visual Acuity

#### i. I improvement in BCVA after laser

The largest randomized clinical trial by ETDRS<sup>13</sup> (1985) found improvement in 16%, stabilization in 77% and deterioration in 7% of the cases of CSME after argon grid/focal laser. Romaniuk W, Koziol H et al<sup>15</sup> (2000) found improvement in 21.4% and stabilization in 60.7% cases, Kajo bucan, Milan Ivanisevic et al<sup>12</sup> (2007) found improvement in 53.8% and stabilization in 23%. In our study we found improvement in 36.8% of cases of CSME after focal laser. Vision remained stable in 42.10% and deteriorated in 21.05% of the cases. In case of grid laser photocoagulation there is improvement in 27.3%, stabilization in 54.5% and deterioration in 18.2% of cases.

Yi. Q, Bamroongsuk P, Mc Carty D J et al<sup>16</sup> (2003) in their study found improvement or stabilization of visual acuity in 61.9% of cases after PRP for PDR. Wilczynski M, Dzivgiewski K et al<sup>17</sup> (2006) in a similar study found stabilization or improvement in 46.10% of the cases.

In our study we found improvement in 33.3% and stabilization in 38%. There is deterioration in 28.5% cases. Our study closely correlates with other studies. In cases of combined grid and PRP, Shrestha S, Karki DB, Byanju R et al<sup>9</sup> (2007) in their study found improvement or stabilization in 66% and deterioration in 33% of the cases. In our study there is improvement in 25%, stabilization in 37.5% and deterioration in 37.5%.

#### ii. Status of post laser BCVA in comparison to pre laser BCVA

Mohan Rema, Purushothaman Sujatha et al<sup>10</sup> (2005) in a study found that 73% of the eyes with baseline VA 6/9 maintained 6/9 or improved after 1 year of laser photocoagulation. 70% of the eyes with baseline VA  $\leq 6/60$  maintained 6/60 at 1 year follow up and 30% showed improvement.

In our study, 78.9% of cases having baseline VA of 6/6-6/18 improved or maintained the same acuity. Deterioration occurred in 20% of the cases. Out of those having baseline VA of 6/24-6/60, improvement occurred in 23% and vision remained stable in 56.4%. In cases having VA  $< 6/60$  stabilization occurred in 72% and deterioration in 27.2%.

### Fundus Changes

#### a. Post laser diabetic maculopathy status:

The table below shows the status of diabetic macular edema after focal/grid laser in different studies (Table 03). From the above table (Table 03) it can be seen that resolution of macular edema occurred in  $> 80\%$  of the cases in most of the studies. In our study macular edema resolved in 81.57% of the cases and persisted in the rest.

Sl. No.	Studies	CSME resolved (%)
1.	Yi Q, Bamroongsuk P, Mc Carty DJ et al <sup>16</sup> (2003)	91.6
2.	Wilczynski M, Dzigielewski K et al <sup>17</sup> (2006)	89.32
3.	Kajo bucan, Milan Ivanisevic et al <sup>12</sup> (2007)	73
4.	Shrestha S, Karki DB, Byanju R et al <sup>9</sup> (2007)	91
5.	Our study	81.57

**Table-3:** Status of diabetic macular edema after focal/grid laser in different studies

### b. Post laser retinopathy status

Venkat M Reddy, M.D., Rene L et al<sup>18</sup> (1995) in a study found that neovascularization regressed in 93% of the cases after PRP with argon green. Yi. Q, Bamroongsuk P, Mc Carty D J et al<sup>16</sup> (2003) found regression in 65.5% of PDR after PRP.

In our study, neovascularization regressed in 72% and persisted in 28% of the cases after full scatter treatment.

### Complications

Mohan Rema, Purushothaman Sujatha et al<sup>10</sup> (2005) in a study found that predominant causes of visual loss at 1 year after PRP were vitreous haemorrhage (31.7%), chronic macular edema (23.8%), preretinal fibrosis (4.7%) and pre retinal haemorrhage (9.5% of the cases). In our study we found that vitreous haemorrhage occurred in 7.5%, 2.5% complained of pain after PRP, 5% developed chronic macular edema and in 2.5% pre-retinal haemorrhage. Lesser percentage of complications is seen in our study than other studies.

### CONCLUSION

The study shows that the focal/grid laser photocoagulation of CSME with Nd:YAG (532x2nm) facilitates improvement of visual acuity as it causes regression of macular edema.

Pan retinal laser photocoagulation with the same wavelength causes regression of neovascularization and stabilization of visual acuity in most of the cases of proliferative diabetic retinopathy.

In patients with PDR and CSME together, focal followed by scatter therapy improves the visual acuity and facilitates regression of macular edema and neovascularization.

Laser photocoagulation decreases the chances of severe visual loss due to complications of diabetic retinopathy and reduces the ocular morbidity. Rational and timely laser therapy is important method to control diabetic retinopathy.

### REFERENCES

1. Klein R, Klein B, Epidemiology of proliferative diabetic retinopathy. *Diabetes care*. 1992;15:1875-91.
2. Klein R, Klein B, Moss S, et al. The Wisconsin Epidemiologic Study of Diabetic Retinopathy. XIV. Ten year incidence and progression of diabetic retinopathy. *Arc Ophthalmol*. 1994;112:1217-28.
3. Yanko L, Goldbourt U, Michaelson C, et al *Br J Ophthalmol*. 1983;67:759-65.
4. Fong DS, Ferris FL III, Davis MD, Chew EY, for the early treatment diabetic research group causes of severe

visual loss in ETDRS; Report 24-Am *J Ophthalmology*. 1999;127:137-41.

5. Diabetic macular edema-Review of *Ophthalmology*. 1986;93:989-997.
6. Stefansson E, Macherner R, De Juan E, et al. Retinal oxygenation and laser treatment in patients with diabetic retinopathy. *Am J Ophthalmology*. 1992;113:36-8.
7. Rema M, Ponnaiya M, Mohan V. Prevalence of retinopathy in non insulin dependent diabetes mellitus at a diabetes centre in southern India. *Diabetes Res Clin Pract*. 1996;34:29-36.
8. Yanko I, Goldborst U, Michaelson IC. Prevalence and 15 yrs incidence of retinopathy and associated characteristic in middle aged and elderly diabetic man. *Br J Ophthalmology*. 1983;67:759.
9. Shrestha S, Karki DB, Byanju R, Malla OK, Shrestha SM, Pradhananga CL: Visual outcome of laser treatment in diabetic retinopathy; *Kathmandu University Medical Journal*. 2007;5:72-80.
10. Mohan Reema, Puroshotham Sujata, Rajendra Pradeepa, visual outcome of panretinal photocoagulation in diabetic retinopathy at one year followup; *IJO*. 2005;53:93-99.
11. Dastur Y K. The rationale of argon green laser photocoagulation for diabetic maculopathy. *J Postgrad Med*. 1994;40:13-15.
12. Kajo Bucan, Milan Ivanisevic, Ljubo Znaor, Lavro Bojic, Ksenija Karaman, Davor Galetovic: The role of frequency doubled Nd-Yag laser (532nm) in the treatment of diabetic macular edema; *Acta Clin Croat*. 2007;46 (Suppl 1):13-15.
13. Early Treatment Diabetic Retinopathy study Research Group: *Int Ophthalmology Clin*. 1987;27:254.
14. H. K. Tewari, Viney Gupta, Atul Kumar and Lalit Verma: Efficacy of diode laser for managing diabetic macular oedema; *Acta Ophthalmol. Scand*. 1998;76:363-366.
15. Romaniuk W, Koziol H, Markowska J, Fronczek M. A grid pattern type of photocoagulation in treatment of diabetic maculopathy-personal experience. *Klin Oczna*. 2000;102:183-186.
16. Yi, Q., Bamroongsuk, P., McCarty, D.J. et al, Clinical outcomes following laser photocoagulation treatment for diabetic retinopathy at a large Australian ophthalmic hospital. *Clin Experiment Ophthalmol*. 2003;31:305-309.
17. Wilczyński M, Dzigielewski K.; Results of laser photocoagulation in patients with diabetic retinopathy developed as a complication of diabetes type 2; *Klin Oczna*. 2006;108:66-9.
18. Venkat M.Reddy, M.D, Rene L.Zamora, M.D., and R. Joseph Olk, M.D. Quantification of retinal ablation in proliferative diabetic retinopathy. *American journal of ophthalmology*. 1995;119:760-766.

**Source of Support:** Nil; **Conflict of Interest:** None

**Submitted:** 28-01-2016; **Published online:** 19-02-2016