

CASE REPORT

Arterio-Venous Malformation In A 18 Year Old: A Case Report

K.Umesh¹, Gayathri Goudar², B.S Ravi Kiran³, Mohammad Imran⁴, Prachi Pahwa⁵, G. Dinesh⁶, Chinthan Savani⁷

ABSTRACT

Introduction: Intraosseous arteriovenous malformations (AVMs) in the maxillofacial area are very rare. These malformations are usually associated with severe hemorrhage resulting in significant morbidity and mortality. The standard treatment of AVMs is an endovascular embolization, combined with surgery. Due to progressive bone development in children, disease management remains a challenge for the surgeon.

Case Report: Here we report a case of AVM wherein we describe our experience in treating the patient with sclerotherapeutic agent. A 18-year-old girl was admitted to our department with provisional diagnosis of an AV malformation in the right cheek region. A sclerotherapeutic agent was used in the management of this malformation. We found a significant change in the size of the swelling.

Conclusion: In conclusion, we advocate that the sclerotherapeutic agents can be used safely in the treatment of AV malformation.

Keywords: Intraosseous arteriovenous malformations, sclerotherapeutic agents.

How to cite this article: K.Umesh, Gayathri Goudar, B.S Ravi Kiran, Mohammad Imran, Prachi Pahwa, G. Dinesh, Mubasheer. Arterio-venous malformation in a 18 year old: a case report. International Journal of Contemporary Medical Research. 2015;2(2):453-455

¹Professor and HOD, ²Professor, ^{3,4,5,6,7} Postgraduate student, Department of oral & maxillofacial surgery, The Oxford Dental College and Hospital

Corresponding author: Dr. Umesh K, Professor and HOD, Department of oral and maxillofacial surgery, The Oxford Dental College and Hospital, Bangalore, India

Source of Support: Nil

Conflict of Interest: None

INTRODUCTION

Since the studies by Mulliken et al,⁶ two types of vascular lesions have been recognized, which depend on the intrinsic properties of the endothelial cells: hemangioma and vascular malformation. Each of these entities meets specific clinical and paraclinical criteria. Vascular malformations are frequently seen in the skin, but much more rarely affect the visceral organs or bones. Fifty percent of all bone involvement occurs in the skull and maxillofacial area. Lesions in the mandible are potentially dangerous, as a biopsy or even a simple tooth extraction can cause a catastrophic haemorrhage that may even lead to death¹. In 1982, usable classification came into being after assessing the clinical and biological behavior of vascular birthmarks. They were divided into vascular tumors (hemangiomas) and malformations which helped in the diagnosis and management of these lesions. Despite recent advances in the knowledge of vascular anomalies, arteriovenous malformations (AVMs) remain an enigma. AVMs are said to arise from errors in vascular morphogenesis. Histologically, AVMs are composed of numerous aberrant arteriovenous shunts associated with dilated capillary beds which are devoid of autoregulation. Vascular recruitment and collateralization contribute to progressive expansion of AVMs, which in turn gives rise to feeding arteries and draining veins. The subsequent network forms a "nidus" of vascular ectasia with an inherent growth potential.²

CASE REPORT

A patient named Lakshmi aged 18yrs reported to our Department of oral and maxillofacial surgery in the oxford dental college and hospital, Bangalore, with a chief complaint of pain in the upper right back tooth region since two weeks. On clinical examination there was grossly destructed

upper right second molar, we could also observe a soft tissue growth extending from the upper right first premolar to upper right second molar. Patient gave a history of swelling since childhood when she was a 8 years old. The swelling started as small peanut size gradually increasing to attain the present size, hence the swelling was of slow growth, extending to involve her upper lip and right anterior maxilla. There was no history of trauma, fever, paresthesia, or dysphagia. The swelling in the right cheek region was extending superior-inferiorly from 1cm above the alartragal line to the lower border of the mandible, antero-posteriorly from the angle of the mandible till the corner of the mouth. General physical examination revealed she had an altered gait which was due to history of RTA 10 years back. Mouth opening was adequate and there was no deviation of the mandible while opening the mouth. Extra oral examination with palpation revealed that the swelling was tender and the lesion was non pulsatile. It was soft in consistency. Intra orally the swelling extended from the right premolar to the right second molar and measuring approximately 1x1.5 cms in diameter. The mucosa over the swelling was bluish in colour with obliteration of the vestibule. The blood investigations were done and found to be normal.

Differential Diagnosis

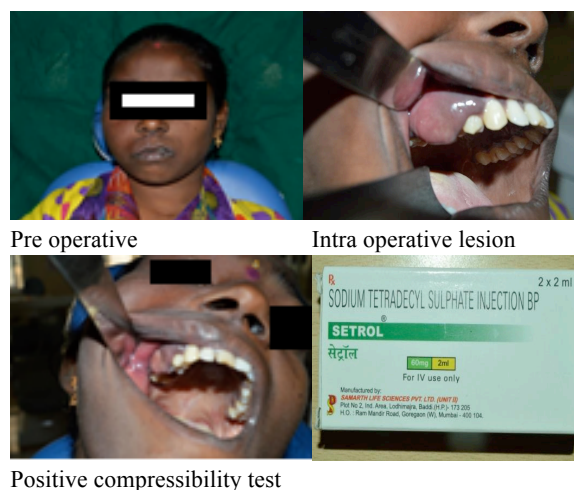
Infantile hemangioma and A.V malformation.

INVESTIGATIONS

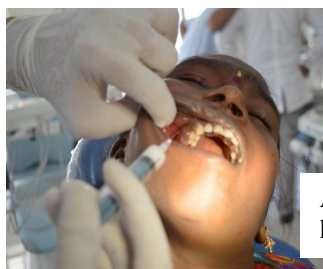
Colour Doppler ultrasound was done which confirmed the arterio venous malformation. Intra-orally 2ml i.e 30mg of sodium tetradecyl sulphate was injected at multiple sites surrounding the swelling along with 8mg of dexamethasone. The soft tissue growth significantly subsided post operatively and the patient is on follow up protocol for the next 6 months.

DISCUSSION

AVMs more common in the head and neck region, compared to other regions in the body, which are exceedingly uncommon. The course and pathogenesis of AVMs are not completely



understood. This misunderstanding has led to sometimes controversial treatment protocols. Many AVMs are diagnosed wrongly as hemangiomas during infancy only to cause progressive soft tissue destruction later in life which can cause ulceration, bleeding, and disfigurement. Since the growth pattern of AVMs are highly misunderstood, this can limit patient access to appropriate therapy. This results in irreversible cosmetic and functional deficits, poor quality of life, and potentially life-threatening disease. Such consequences of continuous AVM growth are rarely mentioned.² The aim of the treatment of such malformations are complete eradication of the nidus, which is the basic abnormality. Even the smallest residual nidus may lead to a recurrence. Various techniques have been proposed that include open curettage, cryosurgery, removal of the intraosseous portion of the vascular malformation, devascularisation by ligation of major feeding vessels, and en bloc resection, sclerotherapy is also a treatment of choice using various sclerotherapeutic agents. Many authors have advocated super selective embolisation followed by resection as the treatment of choice for AVMs of the maxilla and mandible.³ Early signs and symptoms reported in connection with AVMs include pain, mobile teeth, erythematous and spontaneously bleeding gingiva, soft tissue discoloration, facial swelling and asymmetry, visible or palpable pulsations and presence of a thrill or bruit.⁴ Because of the common vasculogenic origin of arteries, capillaries, veins and lymphatics, AVMs are usually mixed or combined type occur. Combinations include capillary-venous (e.g.



Administration of sclerotherapeutic agent.

Sturge-Weber) arteriovenous, lymphaticovenous, capillary-lymphatic, capillary-arteriovenous (Parkes-Weber), capillary-venous lymphatic (Klippel-Trenaunay) and more complex combined forms.⁵ AVMs were supplied with blood by the maxillary artery, facial artery, according to the data obtained. Angiography is considered the gold standard for the definitive diagnosis of AVMs, which appear as a markedly opacified vascular tangle, typically with early venous filling. The angiographic goals are to define the vascular anatomy, assess the extent of the vascular malformation, and identify the feeding vessels. However, angiography cannot demonstrate the full extent of a lesion in the surrounding tissues. CT and MRI help to clarify the extent of the lesion, bone erosion, and the involvement of major vessels; large AVMs can be readily identified on CT and MRI, but smaller lesions may be more difficult to detect. Non contrast head CT is usually the initial imaging examination based on clinical presentation to evaluate for any hemorrhage. CT examinations can show easily calcified and hyperattenuating structures, representing draining veins, components of the nidus, or dilated arterial feeders, suggesting a diagnosis of AVM. The AVM typically does not cause much mass effect, unless there has been hemorrhage.⁷ Haemangiomas show intense focal uptake throughout the lesion. Vascular malformations show abnormal vessels or diffusely increased activity, and lymphatic malformations do not show increased activity⁸ when scintigraphy is done.

REFERENCES

1. L. Giaoui, G. Princ, J. Chiras, F. Guilbert, J.-C. Bertrand: Treatment of vascular malformations of the mandible: a description of 12 cases. *Int. J. Oral Maxillofac. Surg.* 2003;32:132–136.
2. Gresham T. Richter, MD, and James Y. Suen, MD. Clinical course of arteriovenous

malformations of the head and neck: A case series *Otolaryngology–Head and Neck Surgery* 2010;142:184-190

3. Vidya Rattan, Amit Sethi. Arteriovenous malformation of the mandible: successful management by buccal window approach *British Journal of Oral and Maxillofacial Surgery* 2010; 48:e31–e33
4. Nadine Bagherzadegan, Bettina Hohlweg, Majert, Thomas Mucke, Stephan Haerle, Herbert Deppe, Frank Holzle et al Microvascular bone grafting: A new long-term solution for intraosseous arteriovenous malformations of the mandible in children. *Journal of Cranio-Maxillo-Facial Surgery* 2011;39:431 -434
5. Ian C Duncan, Pieter A Fourie; Vascular malformations Part-2 current classification of vascular malformations; *SA journal of Radiology* 2004;2:23-27
6. Jennifer T. Huang, Marilyn G. Liang *Vascular Malformations Pediatr Clin N Am* 2010; 57:1091–1110
7. Kaan Orhan, Murat Icen, Secli Aksoy, Hakan Avsver, Gokcen akcicek. Large arteriovenous malformation of the oromaxillofacial region with multiple phleboliths. *Oral Surg Oral Med Oral Pathol Oral Radiol* 2012;114: e147-e158
8. Watzinger F, Gossweiner S, Wagner A, Richling B, Millesi-Schobel G, Hollmann K Extensive facial vascular malformations and haemangiomas: a review of the literature and case reports *Journal of Cranio-Maxillofacial Surgery* 1997; 25:335-343