

ORIGINAL RESEARCH

Study Of The Cranial Variant Palatine Torus In The Skull Of Uttar Pradesh Region

Pankaj Kumar Singh¹, Zaidi S.H.H.²

ABSTRACT

Introduction: Study of the Palatine Torus, a non metric cranial variant, has been a subject of considerable interest for researchers. Palatine torus is a midline bony protrusion of the palate. It is a slow growing hyperostosis arising from the cortical plate. The aim of the study was to find out the prevalence, size, shape and location of the palatine torus in skulls of Uttar Pradesh region, which is not only of racial and regional importance but also has great clinical implications in prosthodontics treatment in dentistry. Any coexistence of maxillary torus was also noted.

Material and Method: A morphological assessment of 54 skulls from different medical and dental colleges of Uttar Pradesh was done to study this cranial variant.

Result: The result showed a 16.6% prevalence of palatine torus in our study with a significant female predominance. The tori were more commonly spindle shaped and no coexistent maxillary torus was observed.

Conclusion: The current study was to find out the incidence, topographical anatomy and morphology of palatine torus in Uttar Pradesh region, the knowledge of which is important during maxillofacial surgery and in prosthodontics treatment.

Keywords: Palatine Torus, hard palate, exostosis.

How to cite this article: Pankaj Kumar Singh, Zaidi S.H.H. Study of the cranial variant palatine torus in the skull of Uttar Pradesh region. International Journal of Contemporary Medical Research 2015;2(3):499-501

¹Associate Professor, ²Professor, Department of Anatomy, Rohilkhand Medical College, Bareilly, Uttar Pradesh.

Corresponding author: Dr. Pankaj Kumar Singh, Department of Anatomy, Rohilkhand Medical College, Bareilly, Uttar Pradesh, India

Source of Support: Nil

Conflict of Interest: None

INTRODUCTION

Palatine torus is a benign, non painful, non tender, hard bony ridge sometimes seen in the midline of the hard palate. It has been a subject of considerable interest for researchers as it is one of the most common bony osteoma found in the oral cavity, often been referred to by different names eg. Hyperostosis,

hyperplastic bone and exostosis. Histologically however it is similar in nature to a typical bone having an outer cortical and inner cancellous zone. On histopathological examination it appears as a hyperostosis with simple hyperplasia of the mucosa. Palatine torus are generally less than 2 cm in diameter though their size changes continuously throughout life. Its not uncommon however for the size to decrease due to resorption. Palatine torus typically presents in early adult life and even though it has been suggested to be an autosomal dominant trait its cause remains essentially multifactorial. Palatine torus generally has a flat base with a smooth surface. Its shape is variable ranging from nodular, spindle shaped, lobular to irregular. The prevalence of palatine torus is more common than mandibular torus ranging from 9-60%. The commonest location of the tori is in the mid or posterior part of the midline of palate. The current study was aimed at establishing the prevalence and morphological variability of palatine torus from samples taken from the population of Uttar Pradesh. The result was carefully interpreted and compared with the result from other population.

MATERIALS AND METHOD

54 human crania of both sexes were taken for this study from the museum from Rohilkhand Medical College Bareilly, Institute of Dental Sciences Bareilly and Integral Medical College, Lucknow. Thirty three of the skull were male and twenty one female. The skulls with only intact hard palate were included. The incidence of palatine torus was noted as was its shape.

RESULT

Out of the 54 skulls studied the palatine torus was seen in 9 cases (16.6%). Of these, in 4 out of 33 male skulls (12.12%) and 5 out of 21 (23.8%) female skulls, incidence of Palatine Torus was observed (table no-2). In 5 out of 9 (55.5%) cases the tori were of spindle shape.

DISCUSSION

Fox¹ (1814) mentioned it as an exostosis in mid palatal region. Kupffer² (1880) was first to name it. He concluded that the torus occurred more commonly

POPULATION	SAMPLE SIZE	MALE	FEMALE	PREVALANCE
Eskimos Woo J.K.5	Not Available	Not Available	Not Available	66 %
United States Kolas S and Halparin V6	2478	Not Available	Not Available	20.9%
Norway Haughen L.K.24	5000	11.2%	6.7%	9.2 %
Israel Gorsky M25	1002	24.9%	16.4%	21 %
Africa AL Bayaty HF26	367	6.7%	5.5 %	6.2 %
Turkey Cagirankaye L.B.27	253	28.2 %	6.0 %	20.9%
India , Uttar Pradesh Our study (2015)	54	23.8%	12.1%	16.6%

Table - 1: Prevalence of Palatine Torus in various population

in the population living in Northern Hemisphere. Drenan³ found an alarmingly high rate of prevalence (>30%) in the Bushmens, a tribe found in south west Africa. The effect of age on the frequency and expression of palatine torus is still inconclusive. While Miller and Roth⁴ concluded that palatine torus is rare under the age of five and occurs more commonly around 7 years of age. Woo⁵ to the contrary demonstrated the presence of palatine torus in fetal palate. Woo further stated that palatine torus stopped growing once skeletal maturity is achieved at around 20 years. Kola et al⁶ however was of the view that palatine torus increases from the age of adolescence to the age of around 30 years. Miller and Roth⁴ held the view that palatine torus expressed itself more in the older adults, a view that was contradicted by Balez et al.⁷ and Yaacob et al.⁸ who found lower frequency after the age of thirty. No conclusive evidence could thus come out from all these studies that could attribute a certain age that predisposed to the occurrence of palatine torus.

Similar contrasting views emerged regarding the increase in height and width of palatine torus. The generally more acceptable view is the one endorsed by the Norse study that stated that the width did not alter much with age even though the height increased even after skeletal maturity is attained.

Regarding sex predisposition most researchers are of the view that palatine torus is more prevalent in females than in males (Austin et.al.,⁹ Balez et.al.,⁷ Baptista,¹⁰ Lasker,¹¹ Ohno et.al.,¹² Yaacob et.al.⁸). This finding is in accordance to our study. A few authors found higher frequency in males (Bernaba,¹³ Hrdlicka¹⁴). Only some stated no difference between sexes (Axelsson and Hedegaard,¹⁵ Chew and Tan,¹⁶ DeVelliers¹⁷). This female predominance could be due to hormonal difference, X linked inheritance or variation in the biomechanics of jaw size. Another notable feature in all these studies has been the remarkably less incidence of palatine torus in living as compared to the cranial specimen. This could be attributed to the fact that small tori sometimes gets obscured by the mucous membrane.

Various theories have been propounded by different workers regarding the etiology of the palatine torus. Hooton,¹⁸ Kajava¹⁹ and Hrdlicka¹⁴ suggested that it was due to hyperfunction stress in the jaw related to chewing. Schreiner²⁰ concluded that abnormal sensitivity of the bone conditioned by deficient diet and/ or hypervitaminosis resulted in palatine torus. Vanden Brook reported that the torus was a localized growth caused by chemical irritation of the mucous membrane. Hence the final conclusion that was derived was that the incidence of palatine torus varies with race and age. However there is a proven predominance of cases seen in females.

The results of our study showed the prevalence of palatine torus to be 16.6% with a significant female (23.8%) predominance compared to male (12.12%) shown in table no - 2. The size was approximately 18mm and was most commonly spindle in shape. The commonest location was in the posterior part of midline of hard palate. No association with maxillary torus was found. While the prevalence of palatine torus has shown wide variations, most of the morphometric findings were in accordance with the other findings on study of palatine torus (V K Hiremath et al.,²² Janusz Skrazl et al.²³) except for the fact that in our study the commonest location was in posterior part of midline, while most common location attributed to it has been mid part of midline of palate.

CONCLUSION

The palatine torus is the most common bony exostosis encountered in the oral cavity. Its knowledge is of great clinical significance not only for the maxillofacial surgeons but also in prosthodontic treatment. The current study has added further information about the incidence, topographical anatomy and morphology of palatine torus in Uttar Pradesh region.

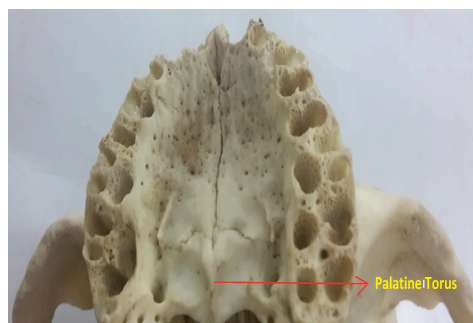


Figure-1: showing palatine torus

Traits	Total			Female		Male	
	No	%		No	%	No	%
Palatine Torus	Absent	45	83.4%	16	76.2%	29	87.88%
	Present	09	16.6%	05	23.8%	04	12.12%
	Total	54	100%	21	100%	33	100%

Table – 2: Prevalence of the palatine tori in a sample of the Uttar Pradesh population

REFERENCES

1. Fox J. Natural history and diseases of human teeth. E. Cox: London; 1814.
2. Kupffer C, Bessel-Hagen F. Verhandlungen der berliner gesellschaft fur anthropologie, ethnologie und urgeschichte. Zeitschrift fur Ethnologie. 1879;11:70–1. 6
3. Drennan, M.R. The torus mandibularis in Bushmans. Journal of Anatomy, 1937; 70:66-70
4. Miller, S.C. and Roth H Torus palatinus: A statistical study. Journal of American Dental Association 1940;27:1950-57.
5. Woo, J.K. Torus palatinus. American Journal of Physical Anthropology. 1950;8(1):81-111
6. Kolas S, Halperin V, Jefferis K, Huddleston S, and Robinson HBG (1953) The occurrence of torus palatinus and torus mandibularis in 2,478 dental patients. Oral Surg., Oral Med., Oral Path. 1953;6r:1134-41.
7. Balazs AB, Diaz EM, and Perez IR Prevalencia de Torus palatinos mandibulares en Ciudad de La Habana. Revista Cubana de Estomatologia. 1983;2Or:126-132
8. Yaacob H, Tirmzi H, and Ismail K The prevalence of oral tori in Malaysians. Journal of Oral Medicine 1983;38:40-42.
9. Austin JE, Radford GH, and Banks SO, Palatal and mandibular tori in the negro N Y State Dent. Journal 1965; 36:187-191
10. Baptista ML Torus palatinus. A frequent clinical observation in the state of Zulia. Dental Abstracts. 1958;35-44
11. Lasker GW Migration and physical differentiation. American Journal of Physical Anthropology. 1946;4r:273-300
12. Ohno N, Sakai T, and Mizutani T Prevalence of torus palatinus and torus mandibularis in five Asian populations. Aichi-Gakuin Dental Science. 1988;1:1-8
13. Bernaba JM Morphology and incidence of torus palatinus and mandibularis in Brazilian Indians. Journal of Dental Research 1977; 56:499-501.
14. Hrdlicka A. Mandibular and maxillary hyperostoses. American Journal of Physical Anthropology. 1940;27r:1-67
15. Axelsson G, and Hedegaard B Torus palatinus in Icelandic school children. American Journal of Physical Anthropology 1985;67:105-112
16. Chew, C.L. and Tan, P.H. Torus palatinus. A clinical study. Australian Dental Journal 1984;29t:245-248
17. De Villiers H (1968) The Skull of the South African Negro. Johannesburg: Witwatersrand University Press.
18. Hooton EA Eskimoid characters in Icelandic skulls. American Journal of Physical Anthropology. 1918;1r:53-76
19. Kajava, Y. Die Zähne der Lappen. Anthropologische Zahnstudie. Society Proceedings Finnish Dental, 1912;10: 1-64.
20. Schreiner, K. E. 1931-35. Zur Osteologie der Lappen. Oslo, H. Aschenhoug & Co
21. Van den Broek, A. J. P. On exostoses in the human skull. Acta Neerlandica Morphologiae Normalis et Pathologiae, 1943-45;5: 95-118.
22. V K Hiremath, A Husein, N Mishra Prevalance of torus palatinus and torus mandibularis among Malay population. Journal of International Society of Preventive and Community Dentistry 2011;1:60-64
23. Janusz Skrzal, Dominika Holiat, Jerzy Walocha Folia Morphol 2003;62:183-186
24. Haugen LK. Palatine and mandibular tori. A morphologic study in the current Norwegian population. Acta Odontol Scand. 1992;50:65–77
25. Gorsky M, Raviv M, Kfir E, Moskona D. Prevalence of torus palatinus in a population of young and adult Israelis. Arch Oral Biol. 1996;41:623–625.
26. Al-Bayat HF, Murti PR, Matthews R, Gupta PC. An epidemiological study of tori among 667 dental outpatients in Trinidad & Tobago, West Indies. Int Dent Journal. 2001;51:300–304.
27. Cagrankaya LB, Kansu O, Hatipoglu MG. Is torus palatinus a feature of a well-developed maxilla. Clinical Anatomy 2004;17:623–625.