CASE REPORT

A Giant Multinodular Goiter - A Case Report

Uttal Taranga Bhuyan[1], Pinpo Teron[2], Nirupama Moran[3]

ABSTRACT

Introduction: The Thyroid gland is a bilobed structure situated in the lower anterior neck common presentation of patients with thyroid disorders affecting of a nodular or generalized swelling of the thyroid.
Case Report: We present a case of multinodular goiter (MNG) in a 25 years old female with a huge swelling in the anterior part of neck. She had a history of 7 years of neck swelling, which was increasing from last two years. Patient was euthyroid, fine needle aspiration cytology was suggestive of colloid goitre. Patient was planed for surgery; total thyroidectomy was done under general anesthesia.
Conclusion: Total thyroidectomy seems to be the best choice for MNG despite the higher rate of complications. Recurrence of goiter after surgery was significantly lower after TT(Total Thyroidectomy).

Keywords: Multinodular goiter, Thyroid, Colloid Total Thyroidectomy

How to cite this article: Uttal Taranga Bhuyan, Pinpo Teron, Nirupama Moran. A Giant Multinodular Goiter - A Case Report. International Journal of Contemporary Medical Research 2015;2(3):469-471

[1]Associate Professor, [2]Assistant Professor, [3]Postgraduate student, Department of Otorhinolaryngology, Assam Medical College , Dibrugarh , Assam

Corresponding author: Dr. Nirupama Moran, Department of Otorhinolaryngology, Assam Medical College , Dibrugarh , Assam

Source of Support: Nil

Conflict of Interest: None

INTRODUCTION

Goitre is an enlargement of thyroid gland caused by compensatory hyperplasia and hypertrophy of the follicular epithelium which occurs sporadically and usually of unknown etiology. Nodular goitre presents rarely before middle age and female preponderance is established.[1] Adenomatous or colloid multinodular goitre(MNG) are common, occuring in 3-5% of the general population, haemorrhage, fibrosis and calcific ation are found within goitres and the incidence of malignant transformation is approximates 7-5%.[2]

There are two forms of multinodular goitre (1) Non-toxic multinodular goitre (2) Toxic multinodular goitre. If the goitre makes the normal amounts of thyroid hormone, it is known as a non-toxic multinodular goitre. If the goitre makes the higher than normal amounts of thyroid hormone leading to suppressed TSH (Thyroid stimulating hormone), it is it is known as toxic multinodular goitre. The exact causes of thyroid nodules or MNG are unknown. In general development of goitre is due to a complex mix genetic and environmental factors. MNG is the most prevalent thyroid pathological abnormality worldwide, although its geographical incidence varies greatly according to environmental iodinization. The main epidemiological determinants are iodine deficiency, age, sex and duration of goitre in iodine deficient and also iodine sufficient areas.
Growth may be accelerated by ingestion of goitrogens, iodine defficiency, pregnancy, malignant change and the development of hyperthyriodism. Most recently, a gene located on Chromosome 14 has been associated with familial non-toxic MNG and polymorphism of codon 727 has been associated with toxic MNG.[3,4]
Clinical management of thyroid nodules is influenced by the combine results of TSH measurement, FNA biopsy and US and depends on cytological diagnosis.[5]

CASE REPORT

A 25 years old female presented a with huge swelling over the anterior part of neck. When patient first noticed the mass it was the size of a thumb, 7 years back. In due course, it has gradually increase in size, and the attaining the present size. Clinical examination revealed a smooth lobulated solid to cystic mass approximately 12x10x10 cm^3 in size extending from the just below the chin to the supra sternal notch (Figure-1). Swelling moves with deglutition, there are no dilated vessels over the swelling. No palpable lymph nodes.patient give a history of difficulty in breathing during sleep.
Computerized Tomography scan of neck and fine needle aspiration cytology (FNAC) were advised. CT scan of neck showing multilobulated heterogeneous predominantly cystic lesions with multiple septations and areas of calcification within with normal enhancing thyroid parenchyma at places noted in both the lobes of thyroid (more on left side) extending

from oropharynx to the infraclavicular region causing mild narrowing of the oropharyngeal and laryngeal lumen. The lesions are showing predominantly peripheral and septal enhancement. The lesion is displacing the trachea to right side without significant narrowing of its lumen (Figure-2). FNAC showed colloid goitre. Thyroid profile was within normal limits. All other haematological and biochemical profile were within the normal range. On the basis of findings the patient was planned for surgery. A transverse neck incision above the suprasternal notch was done, deepen upto fat. The skin flaps are raised in subplatysmal plane superiorly to the thyroid notch and inferiorly to the sterna notch and dissection done between strap muscle and thyroid capsule. Gentle finger dissection is used to free the goitre circumferentially, from the surrounding soft tissues, anteriorly at the thoracic outlet and proceeding laterally, posteriorly and inferiorly (Figure-3) The dissection is facilitated by simultaneous traction. Both the thyroid lobes were removed (Figure-4). Patient was sent to intensive care with unit for observation, no tracheostomy was done. The specimen was sent for histopathological examination that revealed colloid goitre. she was shifted to general ward at 3rd post-operative day. She developed hypocalcaemia post-operatively, which was treated by intravenous infusion of calcium gluconate.Patient was discharge on 10th post-operative day with oral calcium therapy. She came for follow-up and she was absolutely fine.

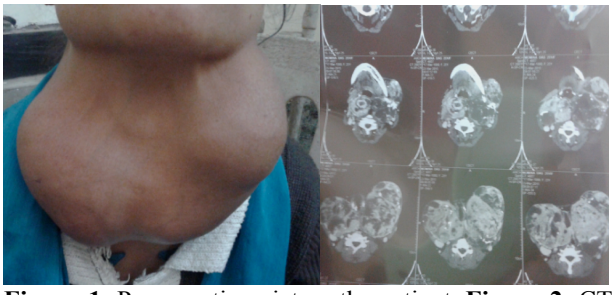

Figure-1: Preoperative picture the patient; **Figure-2:** CT SCAN of the patient

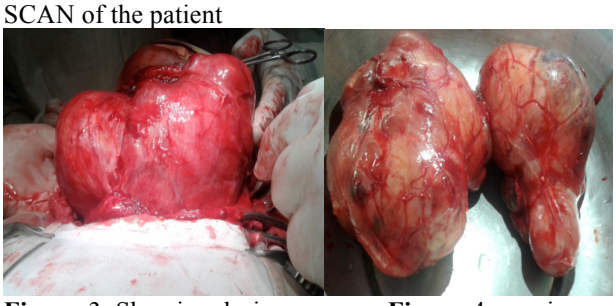

Figure-3: Showing during surgery; **Figure**-4: specimen of thyroid after surgery

DISCUSSION

Thyroidectomy is performed in the treatment of, or exclusion of thyroid cancer and in addition where benign disease gives rise to compression of the oesophagus or trachea, causing dysphagia or stridor, respectively, the treatment of thyrotoxicosis and occasionally for cosmosis. A form of thyroidectomy was first described in China over one thousand years ago.[6]

In 1866, Samuel Gross wrote that thyroid surgery should be considered as horrible butchery and that no sensible and honest surgeon would be engaged in its practice. Kocher, he reduced bleeding by meticulous haemostatic technique and subsequently received the Novel prize for his work in this area. He reported a 0.2 per cent haemorrhage rate in 1898 for the over 5000 thyroidectomies which he performed.[7]

Besides surgery, radioiodine therapy is an attractive alternative, as it does not require hospitalization.[8] Another new treatment is the combination of subtotal thyroidectomy with prophylactic levothyroxine.[9] Although these non-surgical techniques have shown promising results, for large goitres and cases in which malignancy cannot be ruled out, surgical therapy remains the best treatment.[10]

In our case we did total thyroidectomy, and the patient is living normal healthy life after surgery.

In 2008 Agarwal et al. stated that total thyroidectomy is a safe option in the hands of expert surgeons, and that near-total thyroidectomy is a similarly effective but safer option.[11]

Recurrence of goiter after surgery was significantly lower after tatal thyroidectomy (TT). The study of Lehwald et al., which was exclude from the results because it did not compare TT and subtoatal thyroidectomy (STT), also confirm these results: after STT more recurrent nodules were reported.[12]

Vasica et al stated that total thyroidectomy, rather than bilateral subtotal thyroidectomy,is now preferred management for bilateral multinodular goitre(BMNG) in order to reduce need reoperative surgery.[13]

CONCLUSION

We did total thyroidectomy in our patient, she is on oral calcium therapy, and doing very well. The introduction of a policy of initial total thyroidectomy for bilateral benign multinodular goitre has eliminated the need for the reoperative surgery for recurrent goitre.

Total Thyroidectomy seems to be the best choice for MNG despite the higher rate of complications. Recurrence of goiter after surgery was significantly lower after TT.

REFERENCES

1. Bindu Sharma, A case of Colloidal Nodular Goiter, Indian Journal of Research in Homoeopathy 2011;5:40-46.
2. Susan Clarke, The thyroid gland : function tests and imaging ,Scott-Brown's volume 1-A,seventh edition, 2008,Chapter 27, pg-327-337.
3. Berghout A,Wiersinga WM,Drexhage HA lSmith NJ, Touber JL, Comparison of placebo with L-thyroxine or with carbimazole for treatment of sporadic non-toxic goitre. Lancet 1990; 336:193-7.
4. Elte JW,Bussemaker JK,Haak A. The natural history of euthyroid multinodular goitre.Post graduate Medical journal 1990;66:186-90.
5. N. D. Moulick. Multinodular Thyroid Disease. Medicine Update 2008 Vol. 18,Chapter 83,PG-615-627
6. Welbourn RB.The history of endocrine surgery. New York: Praeger, 1990;2:19-82.
7. Albott JH. A biographical history of medicine: excerts and essays on the men and their work. New York :Grune Stratton, 1970;1012-1014:1044-6.
8. Kaniuka S, Lass P,Sworczak K . Radioiodine – an attractive alternative to surgery in large non-toxic multinodular goitres. Nucl Med Rev Cent East Eur 2009;12:23-98.
9. Barczyński M, Konturek A,Golkowski F, Hubalewska- Dydejczyk A, Cichon S ,Nowak W et al. Five-year follow-up of a randomized clinical trial of unilateral thyroid lobectomy with or without postoperative levothyroxine treatment. World J Surg. 2010; 34:1232-8
10. F Romano, Gelmini R, Franzoni C, R Caprotti, A Andreotti, M Guaglio et al. Incidental thyroid carcinoma (ITC): A retrospective`study in a series of 737 patients treated for benign disease. Ann Ital Chir.2010;8:421-7.
11. Agarwal G, Aggarwal V. Is total thyroidectomy the surgical procedure of choice for benign multinodular goiter? an evidence-based review. World J Surg 2008; 32:1313-1324
12. Lehwald N, Cupisti K, Willenberg HS, Schott M,Krausch M, Raffel A et al. Standard-radical vs. function-preserving surgery of benign nodular goiter: A sonographic and biochemical 10-year follow-up study. Langenbecks Arch Surg. 2009; 394:279-83.
13. Vasica G, O'Neil CJ, Sidhu SB, Sywak MS, Reeve TS, Delbridge LW. Reoperative surgery for bilateral multinodular goitre in the era of total thyroidectomy, Br J Surg. 2012;99:688-92.