

Usefulness of CECT Abdomen in the Diagnosis and Treatment of Chronic Appendicitis in Children

Subrat Kumar Mohanty¹, Amaresh Mishra¹, Chinmaya R Behera², Sanjeet Mishra³, Aparna Behura⁴

ABSTRACT

Introduction: Chronic pain abdomen of right lower quadrant is quite common in children, but difficult to arrive at a correct diagnosis. Most of the time the clinical diagnosis points at the possibility of chronic appendicitis. Evaluations of these patients by ultrasound is inconclusive. In the study we tried to find out the role of CECT abdomen in the diagnosis and management of chronic appendicitis.

Materials and methods: The study was conducted in the Dept. of Surgery, Kalinga Institute of Medical Sciences, Bhubaneswar between from January 2012 to December 2014, included 30 patients presented with chronic RIF pain. Ultrasound abdomen was normal and CECT abdomen was done to exclude appendicular pathology. Based on CECT findings 18 patients were diagnosed as having chronic appendicitis and 12 patients had normal appendix.

Results: All the 18 patients of chronic appendicitis had undergone lap. appendectomy whereas 12 patients with CECT findings of normal appendix were offered conservative treatment. Histopathology correlation with CECT findings revealed evidence of chronic appendicitis in 14, acute in 2 and normal appendix in 2 patients. In the followed up period upto 1 year, one patient persisted to have recurrent pain abdomen in the operated group, whereas 2 patients in the conservative group continued with non specific pain abdomen.

Conclusion: Suggested correlation with histopathology and clinical criteria indicates that CECT abdomen can be taken as an useful investigation in diagnosis and management of chronic appendicitis in children.

Keywords: Chronic appendicitis, CECT abdomen, lap. appendectomy, RIF pain

INTRODUCTION

Chronic appendicitis has been well documented in literature, but its diagnosis and treatment options still remains controversial. The exact cause is not known, but is thought to be secondary to partial and transient obstruction of the appendix.¹ Diagnosis of chronic appendicitis is often confusing, thereby treatment is delayed. Though CECT abdomen is considered to be the best test for diagnosis of acute appendicitis, its role in chronic appendicitis is not clearly defined. In past these patients were being treated with surgery based on clinical evidence with very high rate of negative appendectomy. Now a days with evidence based medicine the role of imaging studies is very important to arrive at a preoperative diagnosis. In this context we tried to interpret the CECT abdomen findings as chronic appendicitis where radiological feature of appendix doesn't fit into the criteria for diagnosis of neither acute appendicitis nor normal appendix. Although Shah et al 2013 pointed out that CECT abdomen the best

imaging modality in suspected chronic appendicitis², it lacks universal acceptance. Further in this study we have tried to correlate the justification of our CECT interpretations with that of histopathological findings of appendectomy specimen and clinical improvement of our operated patients in follow up period of 1 year. Our findings suggest that CECT abdomen is a very useful investigation even in chronic appendicitis. In spite of more financial implications and risk of exposure to radiation, it helped us in planning surgery in many patients. We could find a good correlation (up to 77.7%) between the histology of appendectomy specimen and CECT interpretations. In our opinion CECT abdomen should be considered as an important investigation for diagnosis of chronic appendicitis and also it can avoid negative appendectomy.

MATERIALS AND METHODS

The study was performed in the department of Surgery, Kalinga Institute of Medical sciences, Bhubaneswar from January 2012 to December 2014. Patients in the age group of 2-14 yrs with chronic or recurrent episodes of mild RIF pain for more than 3 weeks were included in the study group. In these patients clinical features were quite varied and atypical. Chronic appendicitis usually presents as a less severe, nearly continuous abdominal pain lasting longer than typical 1-2 day period, and often extending to weeks, months or even years.³ Most of these patients had been treated by physicians (paediatricians) and then referred for surgical opinion. Detail history including the repeated episodes of pain and reason for referral were noted. These patients were then evaluated as inpatient group with blood investigations like CBC, CRP, Blood urea, Serum creatine, RBS, Serum amylase, LFT to rule out the other reasons for chronic pain abdomen. Urine routine microscopy and ultrasound were also done routinely in all patients. Patients having normal blood, urine and ultrasound report were subjected to CECT

¹Associate Professor, ²Senior Resident, Department of Surgery, ³Assistant Professor, Department of Radiology, ⁴Associate Professor, Department of Pathology, KIMS, KIIT, Bhubaneswar, 751024, Odisha, India

Corresponding author: Dr. Subrat kumar Mohanty, MS, Mch (Pediatric Surgery), C 1/8, Chandrama Complex, Kharvel Nagar, Unit 3, Bhubaneswar-751001, Odisha, India

How to cite this article: Subrat Kumar Mohanty, Amaresh Mishra, Chinmaya R Behera, Sanjeet Mishra, Aparna Behura. Usefulness of CECT abdomen in the diagnosis and treatment of chronic appendicitis in children. International Journal of Contemporary Medical Research 2016;3(2):576-579.

evaluation to find out the cause of chronic right iliac fossa pain in order to exclude appendicular pathology. There were 30 patients in the study group, 18 males and 12 females. The mean age of presentation was 8 years. Based on CECT findings of recurrent or chronic appendicitis, laparoscopic appendicectomy was performed in 18 patients and the appendix specimen was subjected to histopathological examinations. The other group (12 patients) where CECT abdomen showed normal appendix received only conservative treatment as a case of nonspecific pain abdomen with IV antibiotics ceftriaxone, amikacin and metrogyl for a period of 5-7 days and discharged home. Both the group of patients (laparoscopic appendicectomy and conservative) were followed up to 1 year for either complete cure or recurrence of pain. CECT findings of chronic appendicitis patients were compared with that of histopathological findings. CT scan abdomen was taken as confirmatory evidence before taking up decision to do surgery. The following CECT criteria's were used for diagnosis of chronic or recurrent appendicitis like- subtle appendicular wall thickening with enhancement, and replacement of intraluminal air by fluid. Based on clinical presentation of chronic or recurrent pain abdomen, lack of significant mesenteric adenopathy possibility of chronic appendicitis was considered. Histopathological criteria for diagnosis chronic appendicitis were based on lymphocytic infiltration of the lamina propria, significant lymphoid hyperplasia, fibrosis, serosal adhesions, luminal obstruction, or dilatation. Similarly the H/P diagnosis of acute appendicitis was based on infiltration of granulocytes into the epithelial mucosal layer or deeper.

All these eligible patients enrolled for the study as per clinical and CT scan criteria were subsequently informed about the study background and protocol. Written informed consent was taken before definitive enrolment in the study. The study was approved by the ethical committee, KIIT University.

RESULTS

30 patients with chronic pain in the right iliac fossa were included in the study group. 18 male and 12 female with mean age of presentation 8 years. The age group with maximum number of 20 patients were within 6-10 yrs. CT scan of abdomen was done in all such patients. Based on the CT scan report, 18 patients had findings suggestive of chronic appendicitis and rest 12 patients had normal appendix (Fig 1). In our patients, CT evidence of chronic appendicitis was subtle wall thickening with enhancement and presence of intraluminal fluid (fig 2). Laparoscopic appendicectomy was done in all such 18 patients and appendix specimen was sent for histopathological examination. Histopathological examination revealed pathological evidence of chronic appendicitis in 14 patients (fig. 3), acute appendicitis in 2 patients and normal appendix in 2 patients. On follow up to 6 months, all the 18 patients were pain free except mild pain in 1 patient. Similarly, rest 12 patients of normal appendix had no recurrence of pain except nonspecific pain in 2 patients. (fig 4). There was no postoperative complications or mortality.

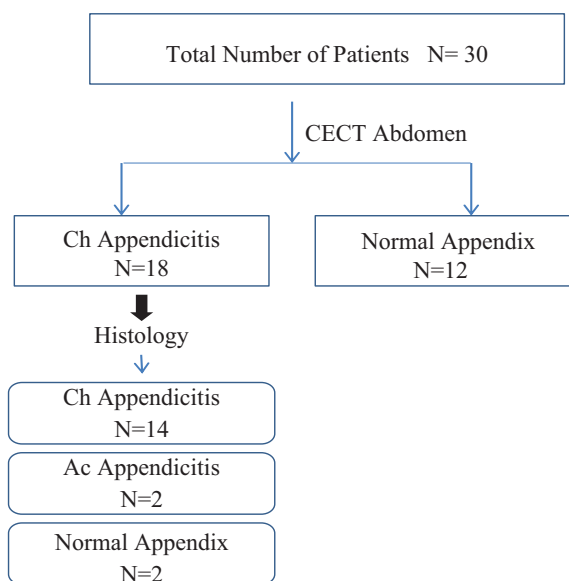


Figure-1: Flow chart of study

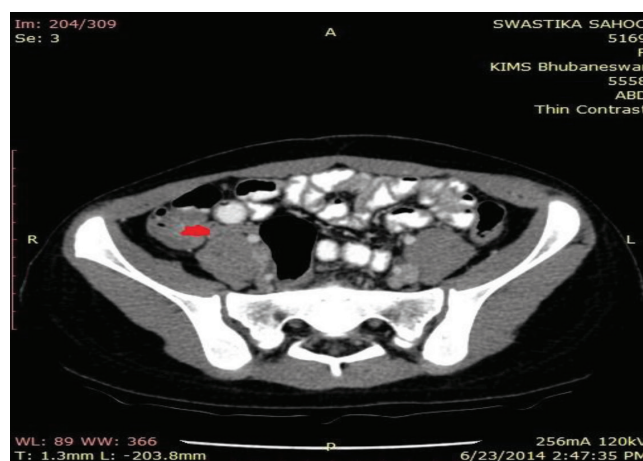

Figure-2: Axial CECT shows mildly dilated appendix with minimally thickened wall, which shows post contrast enhancement. intraluminal fluid seen

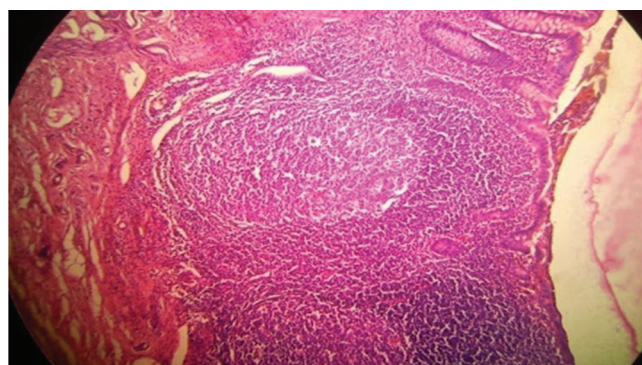


Figure-3: Photomicrograph showing intact epithelium and large lymphoid follicles, H & E, 200X

DISCUSSION

Recurrent pain abdomen is really a difficult entity to treat particularly in children. Symptoms and signs are mostly vague. Only localisation of pain and mild tenderness in RIF arouses suspicion regarding the possibility of a chronic or re-

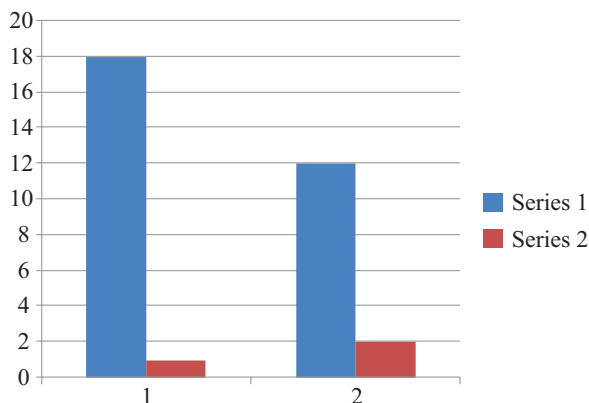


Figure-4: Pain in different group of patients, Series 1-lap.appendicectomy. Series2-Normal group

current appendicitis. Sometimes these types of symptoms respond to iv and oral antibiotics and reappears off and on. Parents and relatives move from one doctor to another in view of complete cure of their child. In that situation, the correct diagnosis and cure by surgery carries a lot of challenge for the surgeon. In the present day practise of evidence based medicine, one has to justify the treatment option and subsequent result. For us CECT abdomen helped in planning the treatment options in more than 90% of patients (27 out of 30 patients were pain free). Clinical and radiological diagnosis of ch.appendicitis remains a controversial subject. In CECT subtle wall thickening with enhancement and replacement of intraluminal gas by fluid was taken as a criteria for diagnosis of chronic or recurrent appendicitis. Continuous symptom duration of more than 3 weeks (chronic appendicitis) or previous episodes of similar symptoms (recurrent appendicitis) occur in 6% and 13% of patients with appendicitis referred for CT.⁴ In our series, based on the CT scan findings, 18 patients had findings suggestive of chronic appendicitis and had undergone lap.appendicectomy. Histopathological examination revealed chronic appendicitis in 14 patients, acute appendicitis in 2 patients and normal appendix in 2 patients. Appendicitis in children is still a difficult diagnosis, researchers found that 60.5% of children had equivocal clinical findings, 14.7% had negative appendectomies, and when an imaging protocol was used 4.1% of cases had negative appendectomies. After implementation of an imaging protocol using US and CT, the perforation and negative appendectomy rates decrease.⁵ In our series, 18 patients had CT scan evidence of chronic appendicitis and 14 patients had good correlation of ch.appendicitis on histopathological evaluation (77.7%).

Imaging that aides in the diagnosis of chronic appendicitis include barium enema, ultrasound abdomen and contrast CT scan of abdomen. Barium is rarely used now a days, ultrasound abdomen the most frequent first hand investigation, but CT scan of the abdomen is considered the most accurate imaging modality of choice for diagnosing and excluding appendicitis with an overall accuracy ranging from 93% to 98%.⁶⁻⁷

The precise aetiology is unknown, but chronic appendicitis is secondary to partial and persistent obstruction of the

appendiceal lumen.^{9,1,2} In such case, luminal secretions accumulate until they are subsequently released.⁶ The causes of intermittent or partial appendiceal obstruction include fecolith, tumors, lymphoid hyperplasia, foreign bodies, and appendiceal folding.^{6,7}

A case series by Rao and colleagues described chronic inflammation of the appendix noted to have lymphocytic and eosinophilic infiltration, fibrosis and granulomatous reaction, and foreign body giant-cell reaction.⁶ Mattei and colleagues considered that the fibrous obliteration of the lumen may be secondary to acute inflammation of the appendix that remained subclinical or resolved spontaneously.⁹

In our study of CT criteria of ch.appendicitis, histopathology had the features of ac. appendicitis and normal study in 2 patients each, other than ch.appendicitis in rest in 14 patients. The exact reason for normal study in 2 patients is not known, but all patients up to 1 year follow up were completely pain free except mild pain in one patient. In the other conservative group of 12 patients with normal appendix, only 2 patients had nonspecific pain in the follow up period. In a case study by Fayez et al, 63 patients who had appendicectomy for chronic RLQ pain and histopathology of the removed appendices revealed abnormality in 92% patients and 95 % of these were completely cured. It is concluded that chronic appendicitis does exist and could be the cause of chronic RLQ pain.¹⁰ The incidence of chronic appendicitis is estimated at 1.5% of all cases¹¹

In this case study, only 3 patients continued to have mild pain in the right lower quadrant. one patient who underwent lap appendicectomy and two patients in the other conservative group. In this regard CECT proved to be fallacious in 10% cases.

Although the clinical data on pain relief following appendicectomy are convincing, the histopathological results are difficult to understand particularly in this context of normal findings. Published figures on the correlation between symptomatology and histopathology are inconsistent.

CECT abdomen of the patients in our series showed an appendix that has neither a normal appearance, nor the appearance in favour of acute appendicitis. These group of patients exhibit an appendix having mild wall thickening (1-2mm) that shows subtle enhancement, intraluminal fluid, normal peri appendiceal fat and prominent ileocolic lymph nodes. Patient having these radiological features when underwent appendicectomy revealed chronic inflammation of appendix in most of these cases.

There are very few articles which describe the CT findings in chronic appendicitis. The above described findings on CT scan can be considered reliable for chronic appendicitis and appendicectomy should be considered in these group of patients, which was proved to be curative in our series. CT scan also helps in planning the treatment options in deciding the group of patients who would benefit the most from surgical treatment.

CONCLUSIONS

Although laparoscopic appendicectomy is a feasible and

safe procedure, diagnosis is challenging and decision to do surgery is difficult. Chronic recurrent appendicitis should be considered in differential diagnosis in the evaluation of a child with chronic RIF pain. CECT criteria of subtle wall thickening with enhancement and replacement of intraluminal air by fluid as the diagnosis criteria for ch.appendicitis and its subsequent correlation with histopathological and clinical criteria suggested that CECT abdomen can be a useful diagnostic aid in these patients of chronic appendicitis.

ACKNOWLEDGEMENTS

We acknowledge with most sincere thanks to the Dept. of Radiology and Dept. of Pathology for their continued help and guidance in this study.

REFERENCES

1. Vanwinter J., Beyer D. Chronic appendicitis diagnosed preoperatively as an ovarian dermoid. *J Pediatr Adolesc Gynecol.* 2004;17:403–406. [PubMed]
2. Shah S., Gaffney R., Dykes T., Goldstein J. Chronic appendicitis: an often forgotten cause of recurrent abdominal pain. *Am J Med.* 2013;126:e7–e8. [PubMed]
3. See T., Watson C., Arends M., Ng C. Atypical appendicitis: the impact of CT and its management. *J Med Imaging Radiat Oncol.* 2008;52:140–147. [PubMed]
4. Athanasios N. Chalazonitis, Ioanna Tzovara; CT in appendicitis: *Diagn Interv Radiol.* 2008;13:19-25.
5. Pena BM, Taylor GA, Fishman SJ. Effect of an imaging protocol on clinical outcomes among pediatric patients with appendicitis. *Pediatrics* 2002;110:1088–1093.
6. Rao, P., Rhea, J., Novelline, R. and McCabe, C. The computed tomography appearance of recurrent and chronic appendicitis. *Am J Emerg Med.* 1998;16:26–33.
7. Drezner, J. and Harmon, K. Chronic appendicitis presenting as low back pain in a recreational athlete. *Clin J Sport Med.* 2002;12:184–186.
8. Babb, R. and Trollope, M. Recurrent appendicitis. Uncommon, but it does occur. *Postgrad Med.* 1999;106:135–138.
9. Mattei, P., Sola, J. and Yeo, C. Chronic and recurrent appendicitis are uncommon entities often misdiagnosed. *J Am Coll Surg.* 1994;178:385–389.
10. Fayez JA, Toy NJ, Flanagan TM. The appendix as the cause of chronic lower abdominal pain. *Am J Obstet Gynecol.* 1995;172:122–123.
11. Hawes AS, Whalen GH. Recurrent & chronic appendicitis; the other inflammatory conditions of appendix. *Am Surg.* 1994;60:207.

Source of Support: Nil; **Conflict of Interest:** None

Submitted: 04-01-2016; **Published online:** 25-01-2016